

RETINOPATHY OF PREMATURITY

Montahaie.T.MD
Ophthalmologist

Therapy:

- ◉ Watch and wait
- ◉ Cryotherapy
- ◉ PRP
- ◉ IVB
- ◉ Scleral buckling
- ◉ Vitx _/+lenx

Indications:

- Zone 1, any stage with plus
- Zone 1, stage 3 without plus
- Zone 2, stage 2, 3 with plus
- Threshold disease therapy within 72 h

STAGES AND ZONES:

Table 5-6 Acute ROP (International Committee on Classification of Acute ROP)

Location

Zone I: posterior retina within a 60° circle centered on the optic nerve

Zone II: from the posterior circle (zone I) to the nasal ora serrata anteriorly

Zone III: remaining temporal peripheral retina

Extent: number of clock-hours involved

Severity

Stage 1: presence of a demarcation line between vascularized and nonvascularized retina

Stage 2: presence of demarcation line that has height, width, and volume (ridge)

Stage 3: a ridge with extraretinal fibrovascular proliferation (may be mild, moderate, or severe, as judged by the amount of proliferative tissue present)

Stage 4: subtotal retinal detachment

A. extrafoveal

B. retinal detachment including fovea

Stage 5: total retinal detachment with funnel:

Anterior

Posterior

Open

Open

Narrow

Narrow

Open

Narrow

Narrow

Open

Cryotherapy:



Figure 5-29 Cryotherapy to the avascular anterior retina in an eye with threshold ROP. (Reprinted by permission of American Medical Association from Multicenter trial of cryotherapy for retinopathy of prematurity: preliminary results. Cryotherapy for Retinopathy of Prematurity Cooperative Group. Arch Ophthalmol. 1988;106:474.)

PRP:

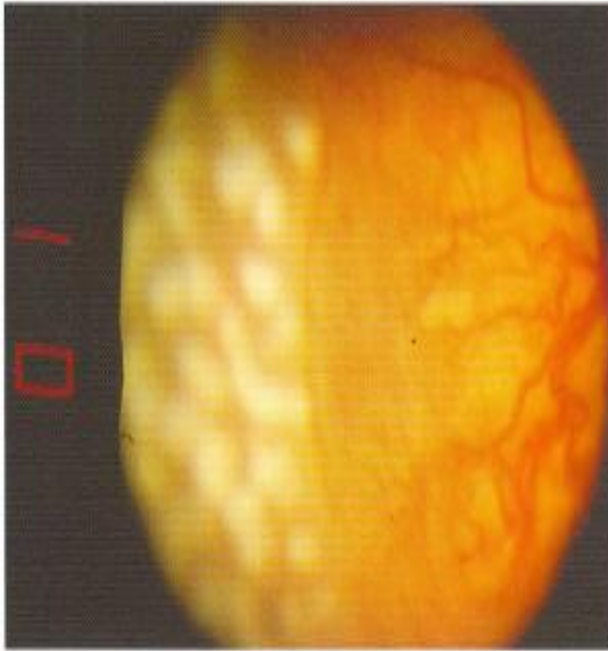


Figure 5-33 Flat neovascularization with florid plus disease. (Courtesy of Philip J. Ferrone, MD.)

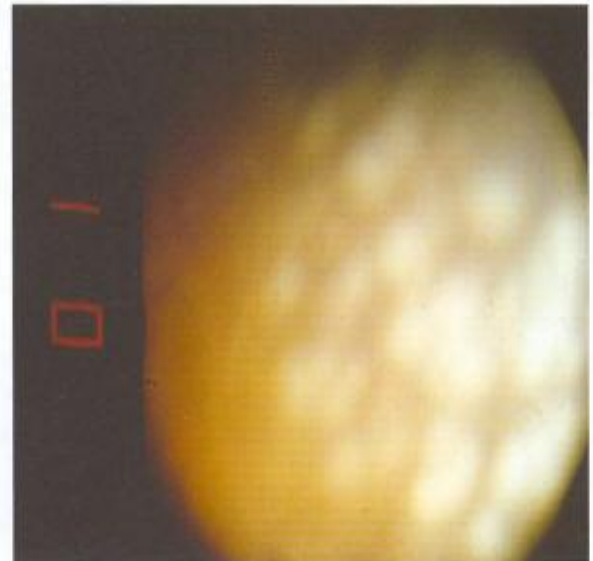


Figure 5-32 Dense laser pattern in avascular retina with plus disease and flat neovascularization. (Courtesy of Philip J. Ferrone, MD.)

Vitx Or SB:

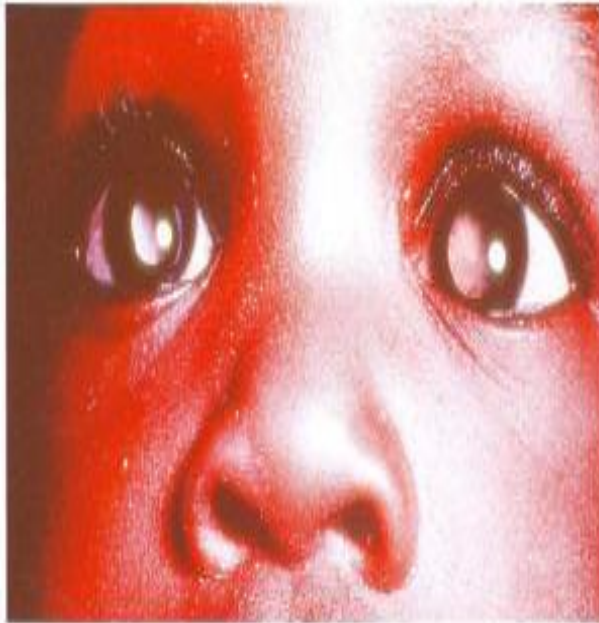


Figure 5-26 Stage 5 ROP. Bilateral total retinal detachments are present, with the retinal tissue drawn up behind the clear lens, forming a retrolental mass in each eye. (Courtesy of Gary C. Brown, MD.)

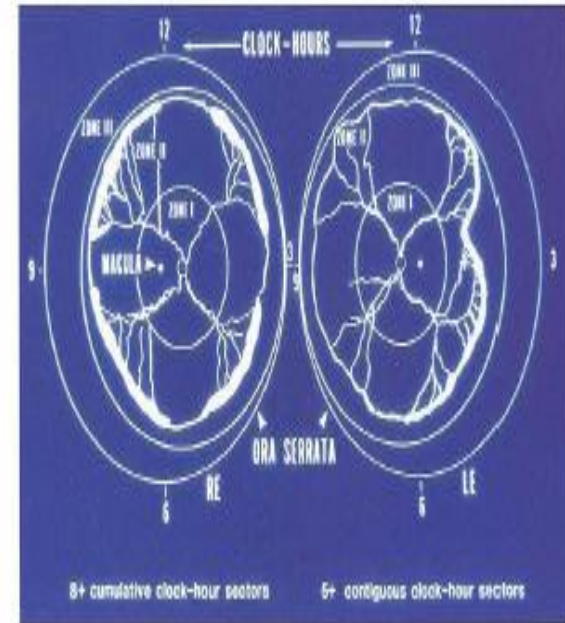


Figure 5-28 Examples of threshold disease, as characterized in the Multicenter Trial of Cryotherapy for Retinopathy of Prematurity. (Reprinted by permission of American Medical Association from Multicenter trial of cryotherapy for retinopathy of prematurity: preliminary results. *Cryotherapy for Retinopathy of Prematurity Cooperative Group. Arch Ophthalmol.* 1985;103:474.)

Figure 5-28 Examples of threshold disease, as characterized in the Multicenter Trial of Cryotherapy for Retinopathy of Prematurity. (Reprinted by permission of American Medical Association from Multicenter trial of cryotherapy for retinopathy of prematurity: preliminary results. *Cryotherapy for Retinopathy of Prematurity Cooperative Group. Arch Ophthalmol.* 1985;103:474.)

Complication:

- ⦿ Retinal changes(RD,HIGH MYOPIA)
- ⦿ Myopia
- ⦿ Strabism
- ⦿ Amblyopia
- ⦿ Cataract
- ⦿ Glucoma
- ⦿ Macular dragging

Macular dragging:

