Pericardial effusion and tamponade

DR .AMIR ARIS

Etiology

- any disease that can cause pericarditis can cause an effusion. Effusions are common early after cardiac surgery and orthotopic heart transplantation, but tamponade is unusual.
- Patients with severe circulatory congestion may have small to moderate transudative effusions. Bleeding into the pericardial sac occurs after **blunt and penetrating trauma**, following **post-MI rupture of the LV free wall**, and, increasingly, as a complication of cardiac procedures.
- Retrograde bleeding is a major cause of death due to **aortic dissection** .
- Pericardial effusions are also common in patients with **pulmonary hypertension.**
- **Those causes of effusion with a high incidence of progression to tamponade include bacterial, fungal, and HIV-associated infections; bleeding; and neoplastic involvement.**
- **Idiopathic pericarditis**

Clinical manifestation

- Effusions do not cause symptoms in and of themselves without tamponade, although patients may have pain due to pericarditis.
- Patients with tamponade may complain of dyspnea, Other symptoms reflect the severity of cardiac output and blood pressure reduction. the cardiovascular examination is normal unless the effusion is large, the cardiac impulse is difficult to palpate, and the heart sounds are muffled. A friction rub may of course be present. Tubular breath sounds may be heard in the left axilla or base due to bronchial compression. The presence of Beck's triad of hypotension, muffled heart sounds, and elevated jugular venous pressure suggests severe tamponade.
- A paradoxic pulse is the rule, but it is important to be alert to situations where it may be absent.

Laboratory testing

- ECG: Low voltage , electrical alternans, usual ECG findings of pericarditis.
- flask-like appearance. Lateral views may reveal the fat pad sign, a linear lucency between the chest wall and anterior surface of the heart resulting from separation of parietal pericardial fat from epicardium.
- The lungs are oligemic.

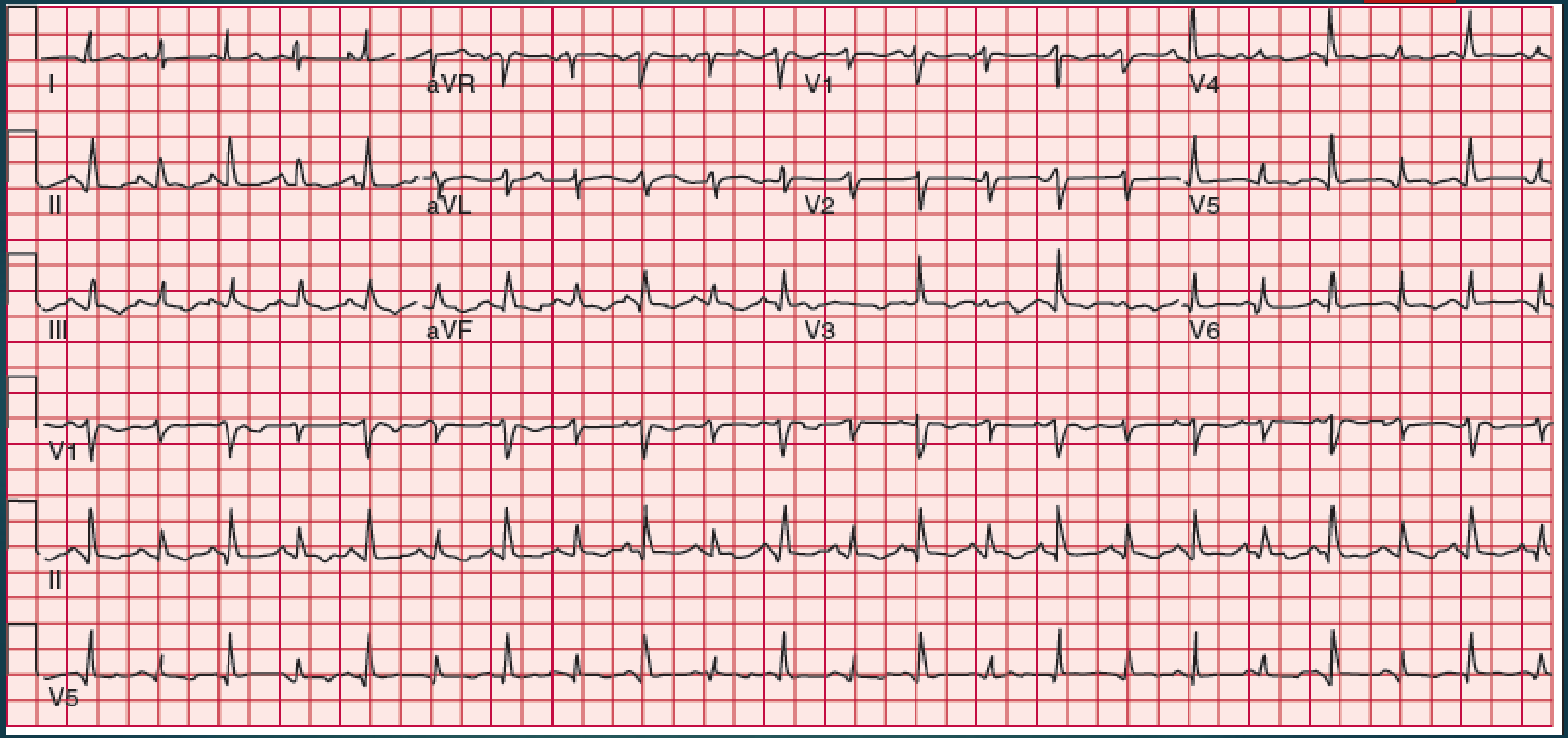
I
aVR
V1
V4
II
aVL
V2
V5
III
aVF
V3
V6
V1
II
V5

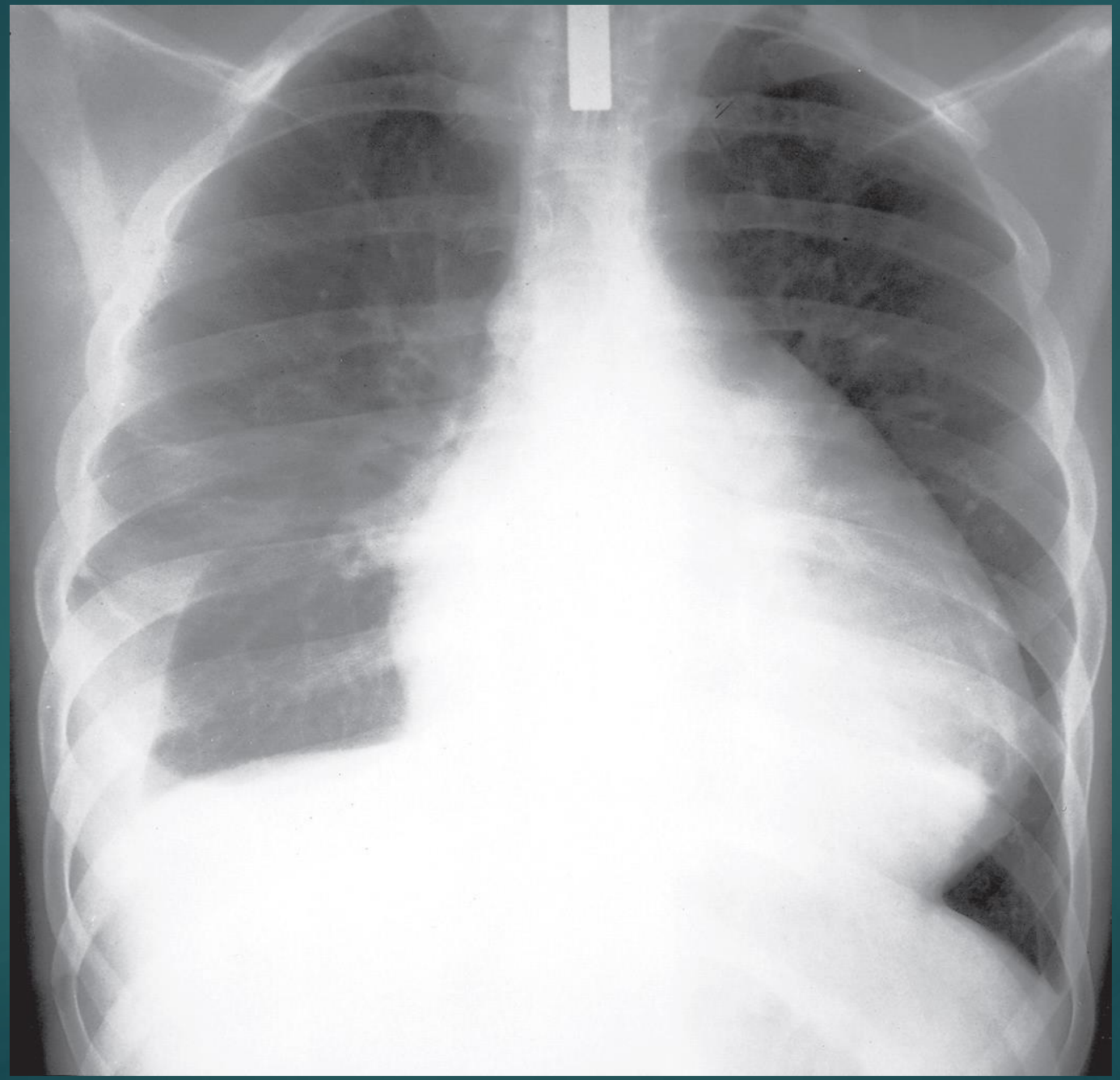

Echocardiography

- early diastolic collapse of the right ventricle
- late diastolic indentation or collapse of the right atrium
- exaggerated respiratory variation in RV and LV inflow
- interventricular septal shifting during inspiration causing a bulge or "bounce."
- Swinging heart

- CT and MRI provide more detailed quantitation and regional localization of effusions than echocardiography and are useful with loculated effusions and coexistent pleural effusions.
- MRI with gadolinium directly identifies inflammation.
- Clues to the nature of pericardial fluid can be gained from CT attenuation coefficients;
- Attenuation similar to water suggests a transudative effusion;
- attenuation denser than water, a malignant effusion or bloody or purulent fluid;
- and attenuation less dense than water, a chylous effusion. Malignant effusions are associated with a thicker pericardium than benign effusions.

Management

- When tamponade is present or threatened, decision making requires urgency and a low threshold for **pericardiocentesis.**
- diagnostic tests recommended for acute pericarditis and anything else dictated by the clinical picture (e.g., screening for neoplastic or autoimmune diseases, infections, and hypothyroidism).
- Before undertaking pericardiocentesis, a course of an **NSAID** or **corticosteroids** combined with **colchicine** may be considered, because this has a low risk. In the absence of evidence of inflammation.
- Recurrence of this type of effusion after closed pericardiocentesis is considered an indication for pericardiectomy or a pericardial window.

1. Determine if tamponade is present or threatened based on history, physical examination, echocardiogram.

2. If tamponade is not present or threatened:
   If etiology is not apparent, consider diagnostic tests as for acute pericarditis.
   If effusion is large, consider a course of an NSAID plus colchicine or corticosteroid; if no response, consider closed pericardiocentesis.

3. If tamponade is present or threatened:
   Urgent or emergent closed pericardiocentesis or careful monitoring if trial of medical treatment to reduce effusion is considered appropriate.

- Hemodynamic monitoring with a central venous or pulmonary artery catheter is often useful, especially in patients with threatened or mild tamponade in whom a decision is made to defer pericardiocentesis. Monitoring is also helpful after pericardiocentesis to assess reaccumulation and the presence of underlying constriction.

- Pericaridocentesis is not suitable in setting of;
- Hemopericadium, dissection type A,LV rupture after trauma or MI
- Open pericariotomy;
- LV free wall rupture, loculated fluid, moderate size pericardial effusion,recurrent pericardial effusion.

- The most common approach to closed pericardiocentesis is subxiphoid needle insertion with echocardiographic guidance to minimize the risk of myocardial puncture and assess the completeness of fluid removal. Once the needle has entered the pericardial space, a modest amount of fluid is immediately removed (perhaps 50 to 100 mL) in an effort to produce rapid improvement. A guidewire is then inserted and the needle replaced with a pigtail catheter.
- Pericardial decompression syndrome.

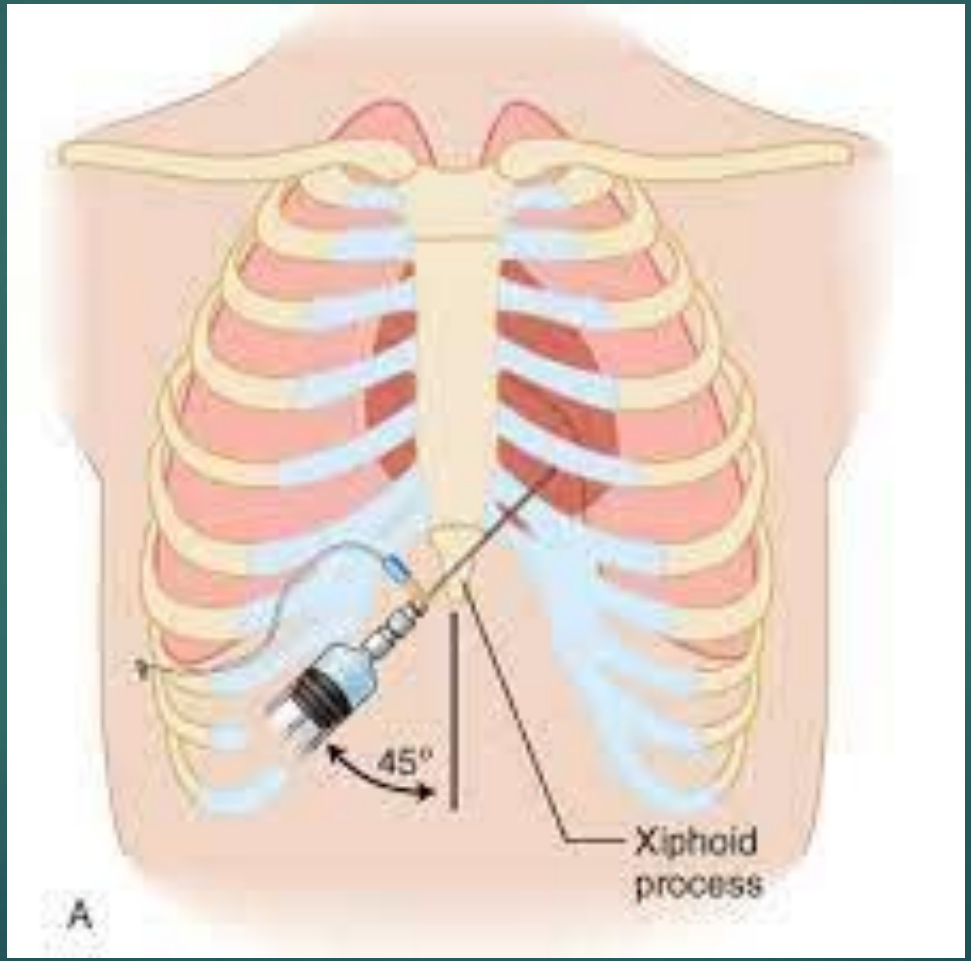
45°
Xiphoid
process
A

Analysis of pericardial fluid

- Measurements should include WBCs and differential, hematocrit, and protein content.
- Although most effusions are exudates, detection of a transudate reduces diagnostic possibilities. **Sanguineous fluid** is nonspecific and does not necessarily indicate active bleeding. **Chylous effusions** can occur after traumatic or surgical injury to the thoracic duct or obstruction by neoplasms. **Cholesterol-rich ("gold paint") effusions** occur in hypothyroidism. Pericardial fluid should routinely be stained and cultured for bacteria, including Mycobacterium tuberculosis, and fungi and as much fluid as possible submitted for detection of malignant cells.
- Suspected for TB :

interferon-gamma (uIFN-γ), adenosine deaminase (ADA), lysozyme levels, and the polymerase chain reaction (PCR)

Thanks for attention