
بسم الله الرحمن الرحیم

Visual Field in Neurologic Disease

A .Medghalchi,M.D
Associate Professor Of Ophthalmology
GUMS 1400

VF loss respecting Vertical line

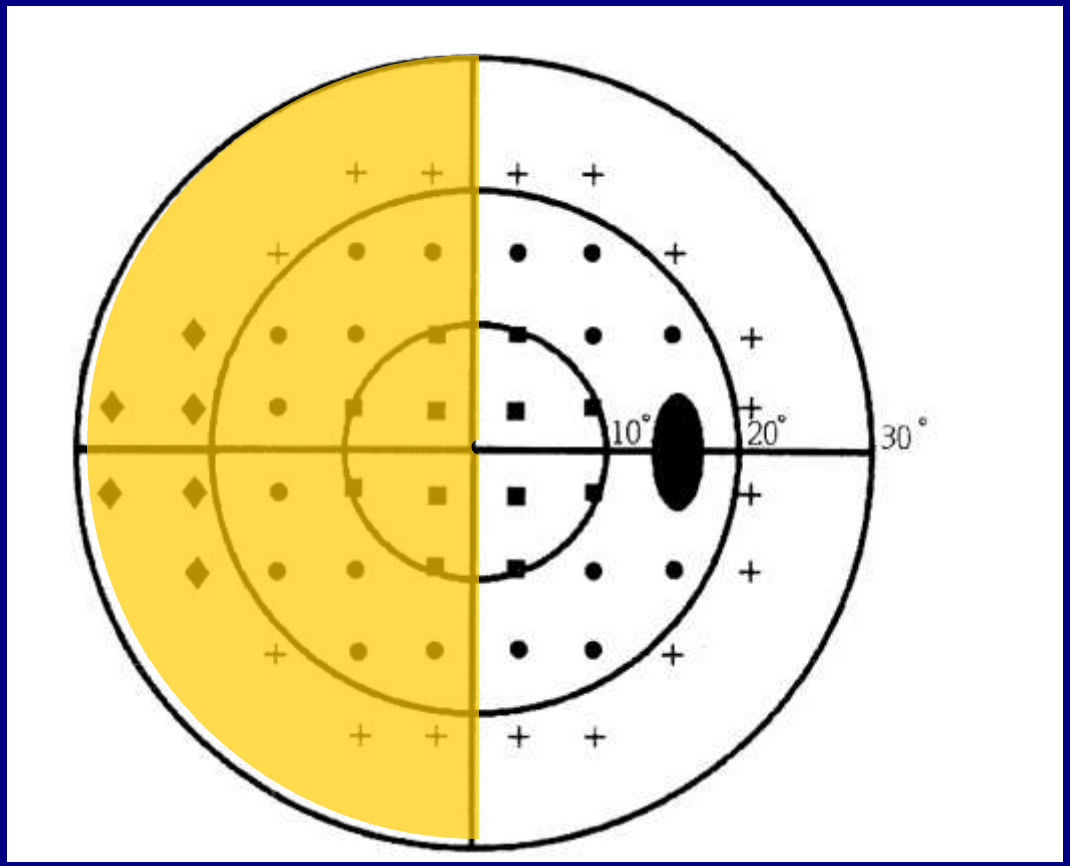

Absolute scotoma

Normal Monocular & Binocular Field

Monocular:

- Nasal side - 50° to 60°
- Superior side - 60° to 70°
- Inferior side - 70° to 80°
- Temporal side - 100°to110°

Binocular:

- Vertical field - 110°
- Horizontal field - 200°

Visual field defects associated with the major lesions of the visual pathway.

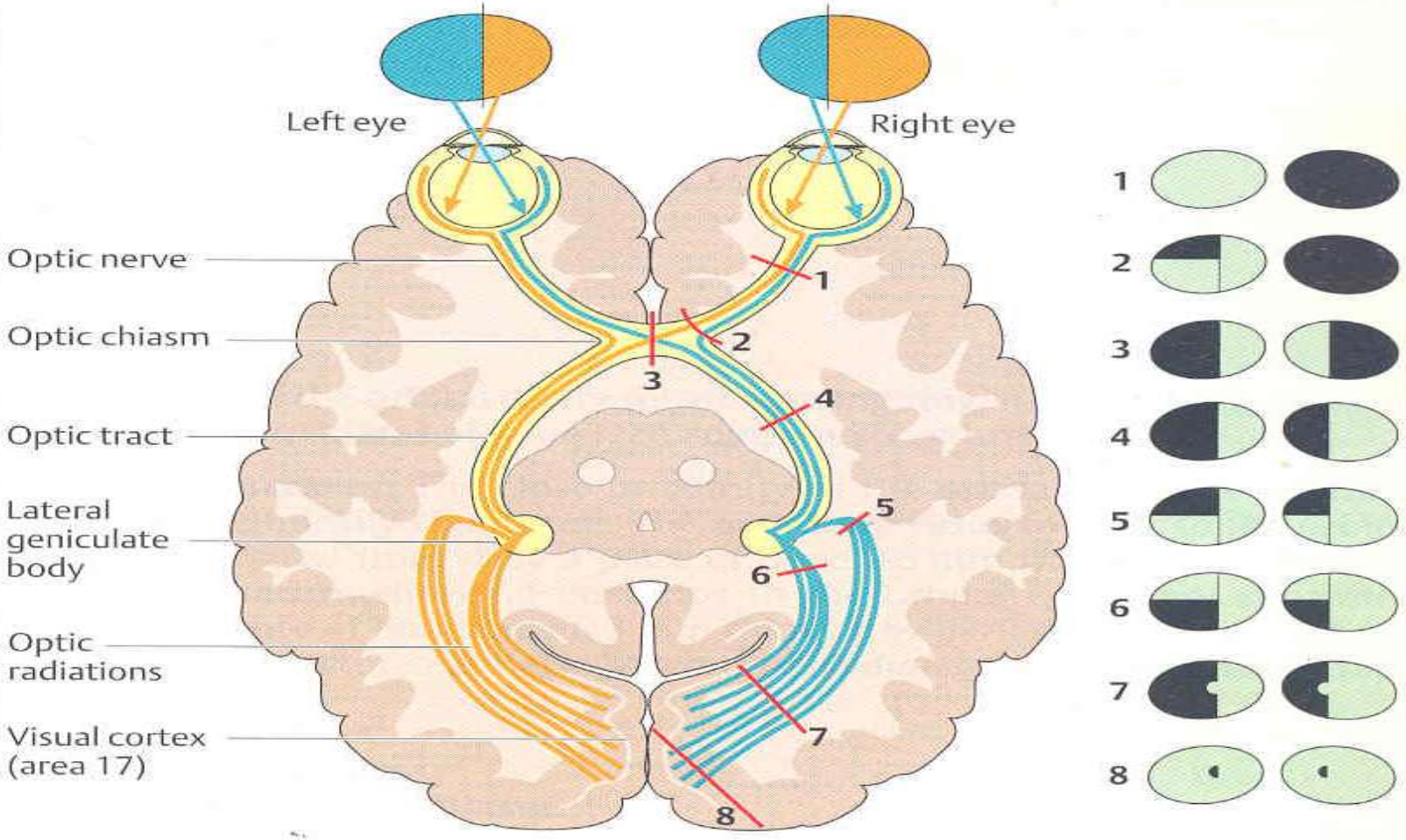

Fig. 14.9

TABLE IV-1

PERIMETRIC TERMS

TERM	CHARACTERISTICS
Characteristics of the visual field defect	
Absolute	No stimulus perceived in the affected area
Relative	Bigger and brighter stimuli may be perceived in the affected field, but smaller, dimmer targets are not seen. The size and shape of the field defect, therefore, change inversely with changes in size and/or intensity of the presented stimulus. Defects may be described as shallow when only the smallest or dimmest targets fail to be identified or deep if bright objects are not detected in the central portion of the defect.
Terms describing visual field defects	
Scotoma	Area of depressed visual function surrounded by normal visual function (eg, the blind spot)
Central	Involves fixation only
Cecocentral	Extends from fixation temporally to the blind spot
Paracentral	Involves a region next to, but not including, fixation
Pericentral	Involves a region symmetrically surrounding, but not involving, fixation
Arcuate	Corresponds to and represents nerve fiber bundle loss
Altitudinal	A more extensive arcuate defect involving two quadrants in either the superior or inferior field
Quadrantanopia	One quadrant of visual field involved
Hemianopia	One half of visual field involved, either nasal or temporal
Description of bilateral visual field defects with respect to spatial localization and extent	
Homonymous	Same side of visual space affected in each eye
Bitemporal	Opposite temporal sides of visual field space affected in each eye
Complete	Entire field affected
Incomplete	A portion of the field spared
Congruity	Tendency for homonymous field defect to be symmetrical (ie, to have a similar size, location, and shape in each eye's field)

- Optic nerve
- Optic chiasm
- Optic tract
- Lateral geniculate body
- Optic radiation
- Optic cortex

VF Defect in ON disease

Visual Field Patterns in Optic Neuropathy

- Retinal ganglion cell nerve fibers enter the optic nerve head in 3 major groups.
- papillomacular fibers:
- arcuate fibers:
- nasal radiating fibers:

Visual Field Patterns in Optic Neuropathy

- papillomacular fibers:
  - cecocentral scotoma
  - paracentral scotoma
  - central scotoma
- arcuate fibers:
  - arcuate scotoma
  - altitudinal defect
  - nasal step defect
  - fibers align along the temporal horizontal retinal raphe
- nasal radiating fibers:
  - temporal wedge defect

- Papilloedema:

✓ Blind spot enlargement

✓ Peripheral contraction

✓ Total loss of visual field

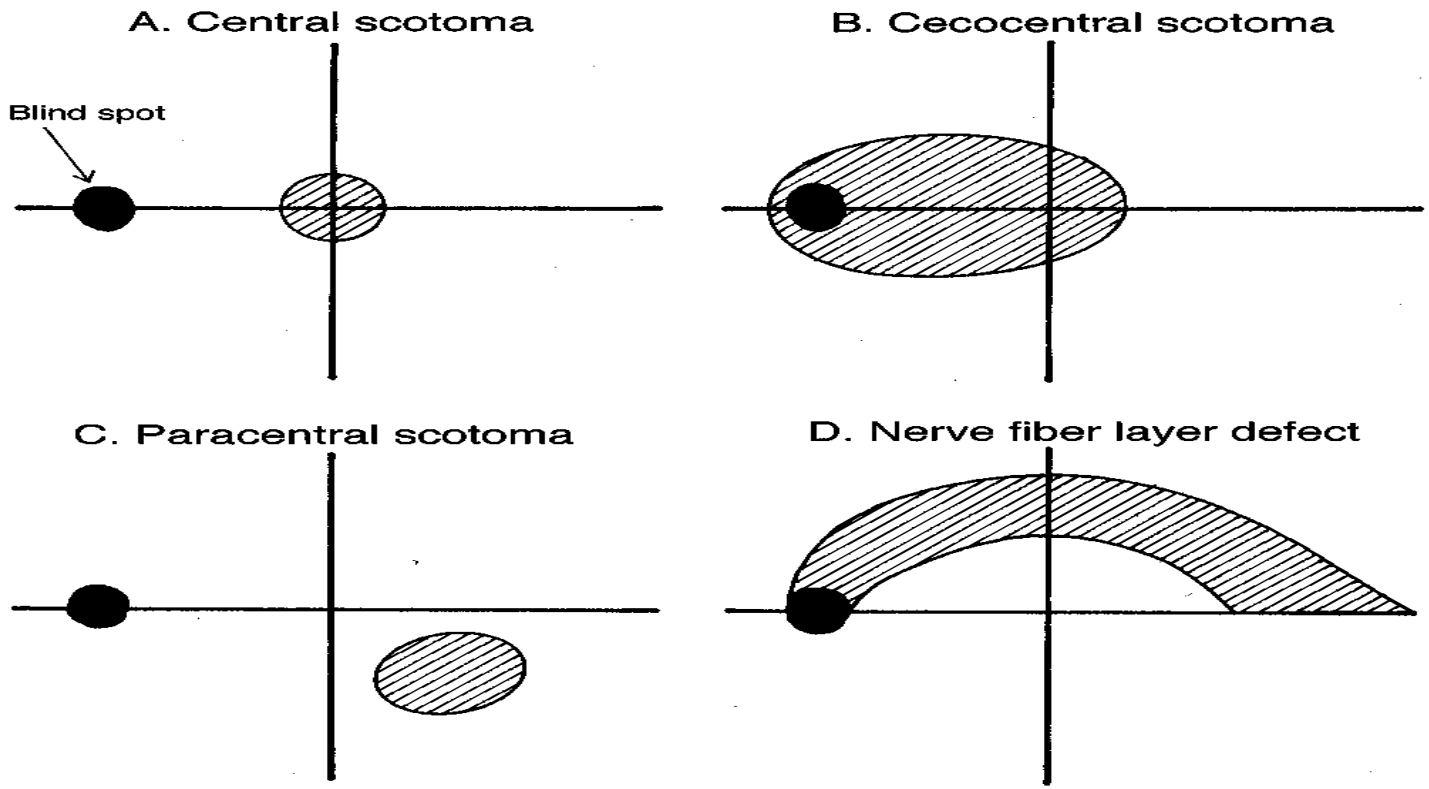

FIGURE 22–1 Common types of visual field defects seen with damage to the retrobulbar optic nerve. A: Central scotoma. B: Cecocentral scotoma. C: Paracentral scotoma. D: Nerve fiber layer defects.



Altitudinal Field Defect
AION Vs. Glaucoma

Diseases of chiasm

Anatomic relationships of the optic chiasm.

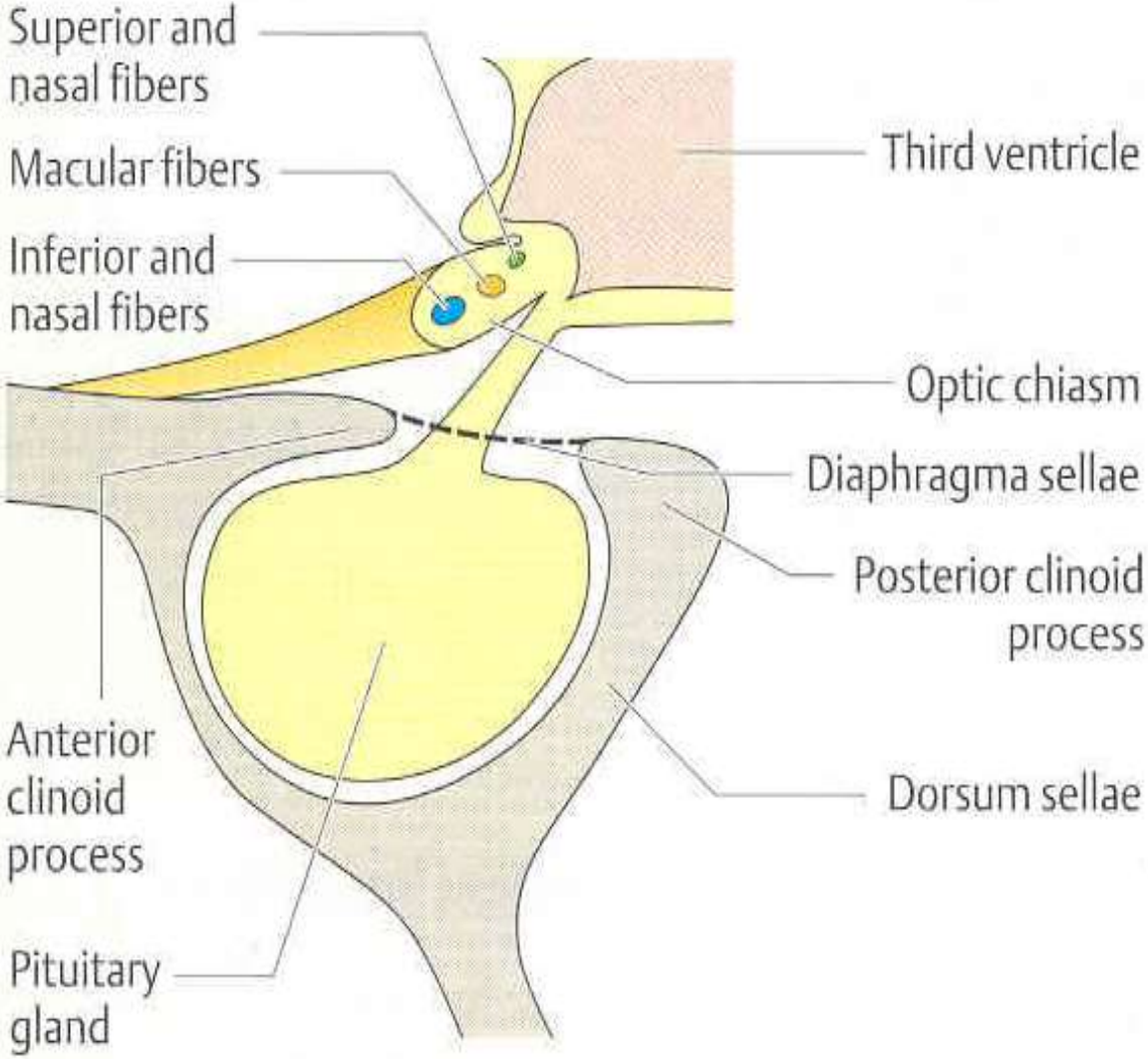

Fig. 14.4 Sagittal section of the optic chiasm. See text for details.

- Extrinsic lesions affecting the chiasm
- Intrinsic lesions affecting the chiasm

Disorders Extrinsic lesions affecting the chiasm

- Pituitary adenoma
- Para sellar meningioma
- Craniopharyngioma
- Para sellar internal carotid artery aneurysm
- Other CNS mass lesions

Intrinsic lesions affecting the chiasm

- infectious :tuberculosis, Lyme disease
- inflammatory :sarcoidosis, multiple sclerosis
- Neoplasm :
  - primary (glioma)
  - secondary (metastasis)
- closed-head trauma
- Para sellar radiation therapy

VF defect

- Ant. Chiasmal synd:
  - ✓ Diminished VA in one eye
  - ✓ Superior temporal defect in other eye
  - ✓ Unilateral hemianopia
- Mid chiasm:
  - ✓ Bitemporal hemianopia
  - ✓ Homonymous hemianopia
  - ✓ Binasal hemianopia
- Post chiasm:
  - ✓ Bitemporal hemianopic scotoma

- The most important characteristics is respecting vertical line

Possible compression of the optic nerve by a meningioma.

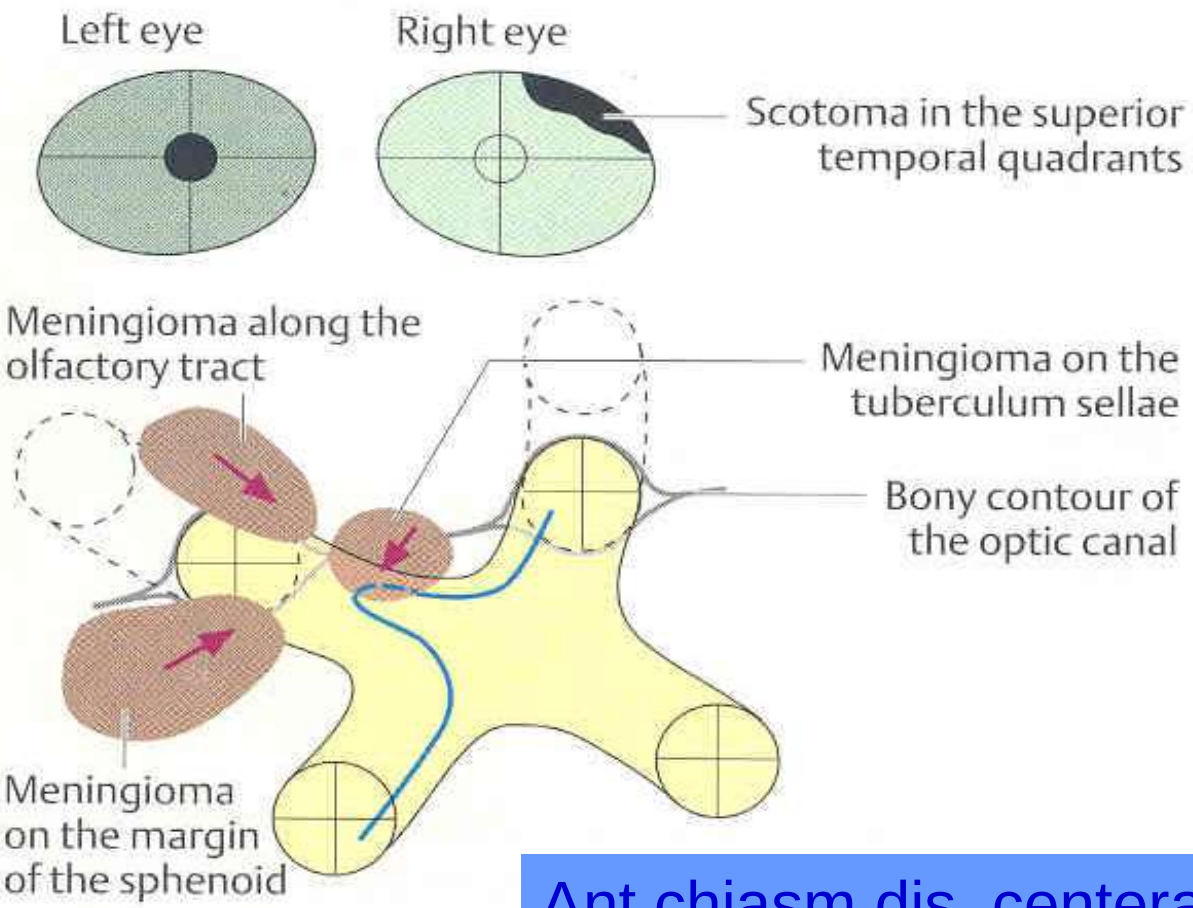

Fig. 14.7 In addition to visual field defects on the side of the affected optic nerve, the contralateral eye may also be affected if fibers in the arc of Wilbrand are compressed.

Ant chiasm dis. centeral ↓ VA in ipsilateral eye + supralateral loss in other eye

(junctional scotoma)

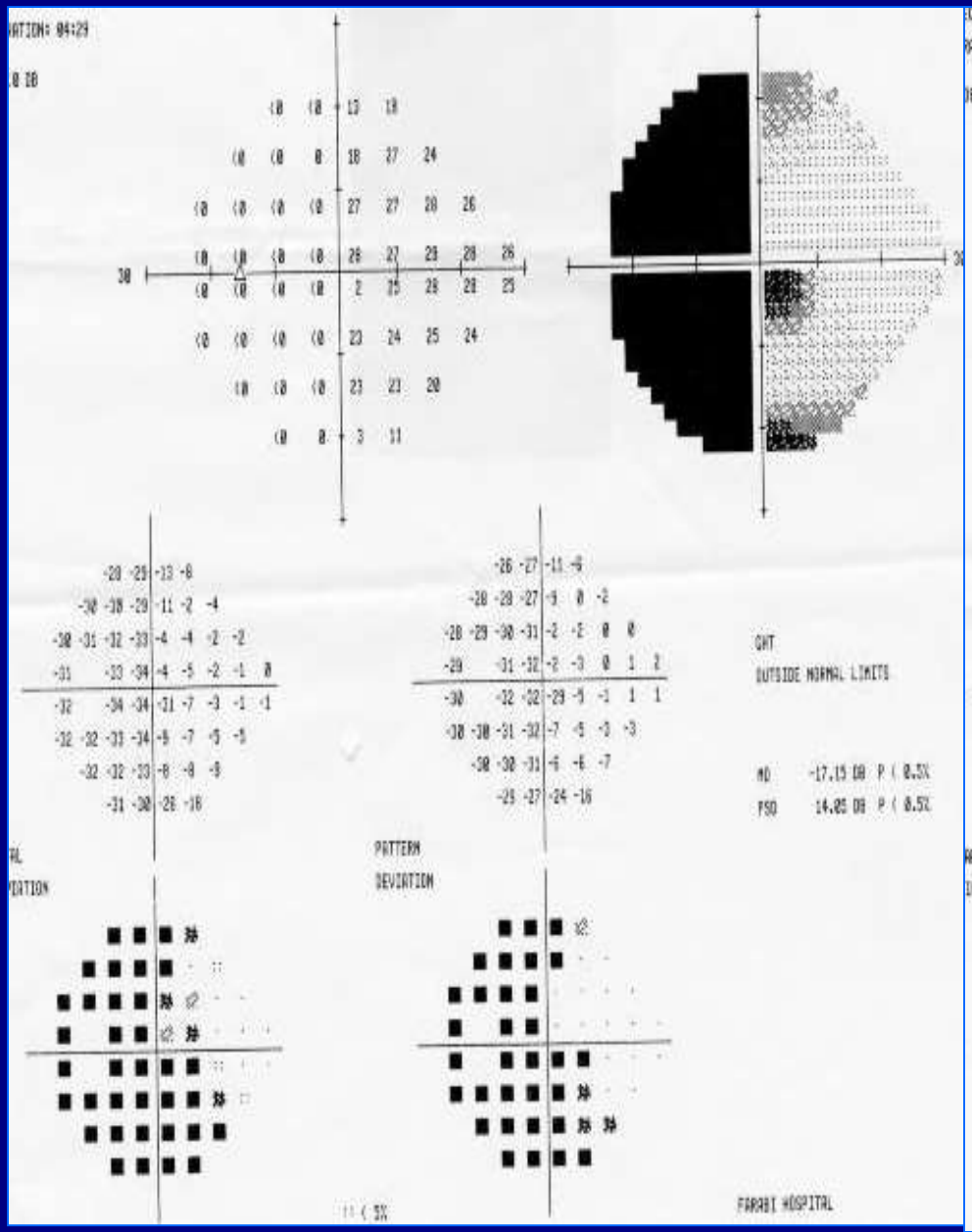
OUTSIDE NORMAL LIMITS
MD -17.15 DB P < 0.5%
PSD 14.05 DB P < 0.5%
PATTERN
DEVIATION
FARABI HOSPITAL

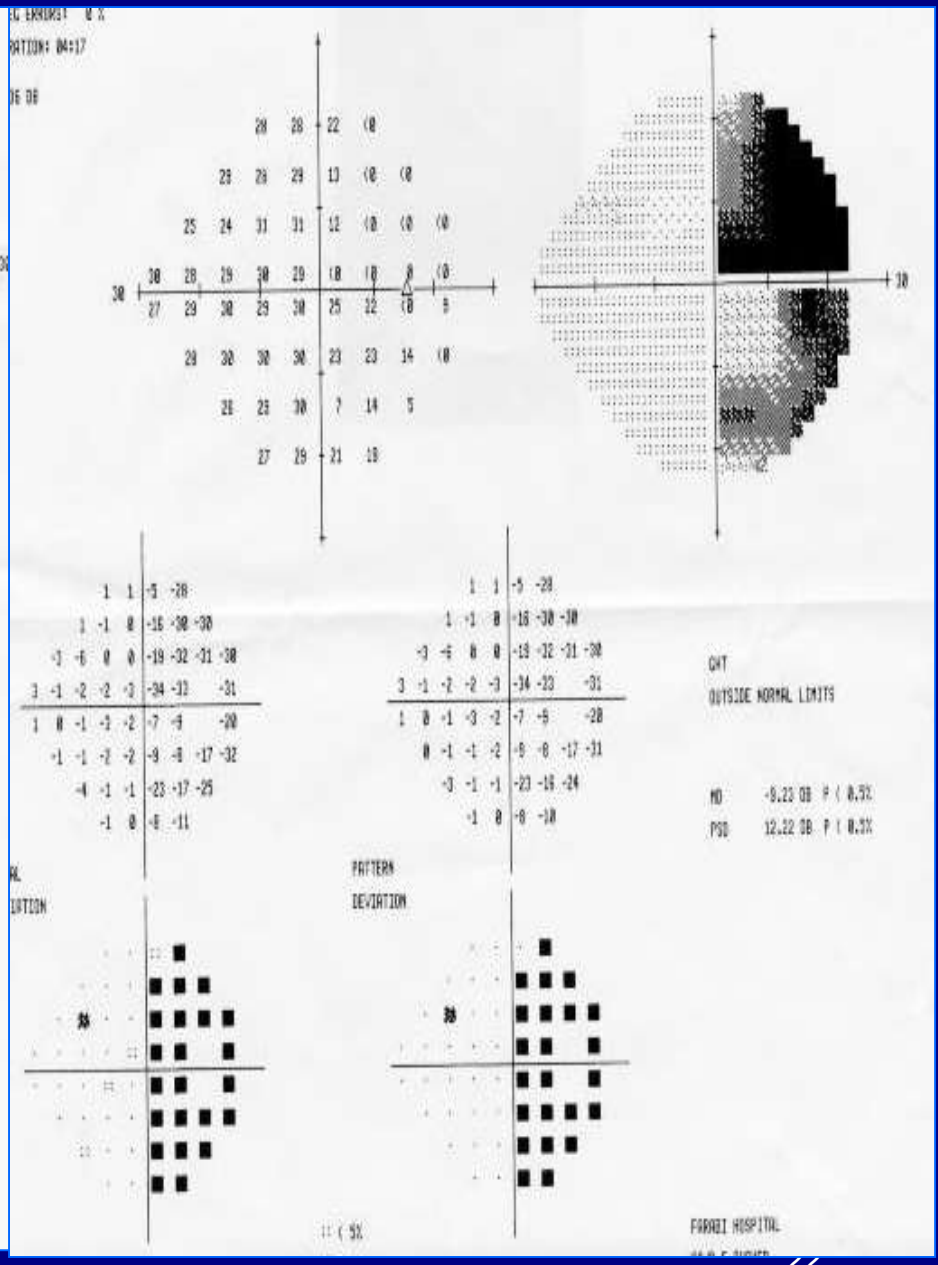
OUTSIDE NORMAL LIMITS
MD -8.23 DB P < 0.5%
PSD 12.22 DB P < 0.5%
PATTERN
DEVIATION
FARABI HOSPITAL

Inferior compression of the optic chiasm by a pituitary adenoma.

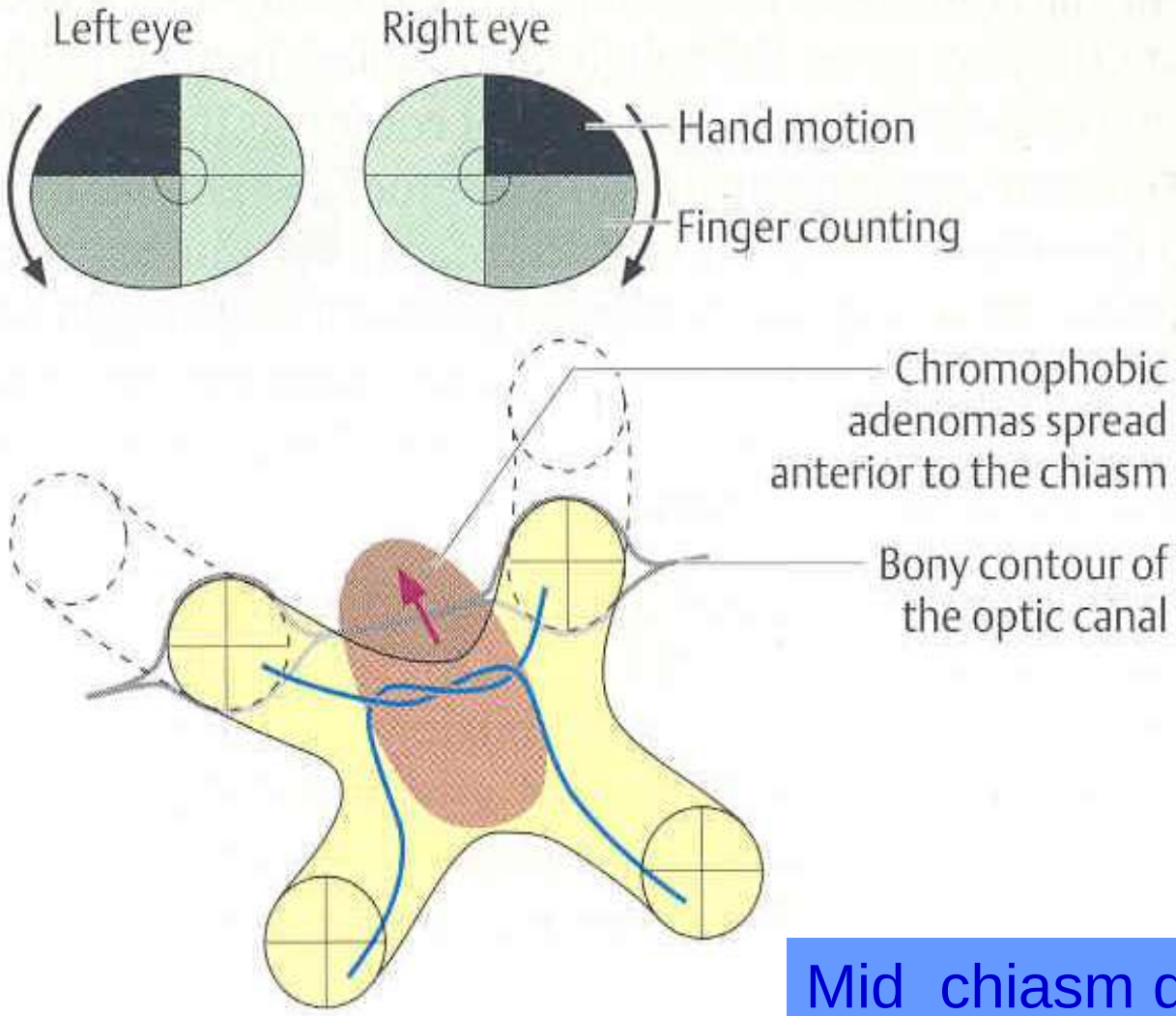

Fig. 14.5 The visual field defect begins as a bilateral superior temporal defect and may progress to complete bilateral temporal hemianopsia. The terms "finger counting" and "hand motion" describe the patient's visual perception.

Mid chiasm disease.

Superior compression of the optic chiasm by a craniopharyngioma.

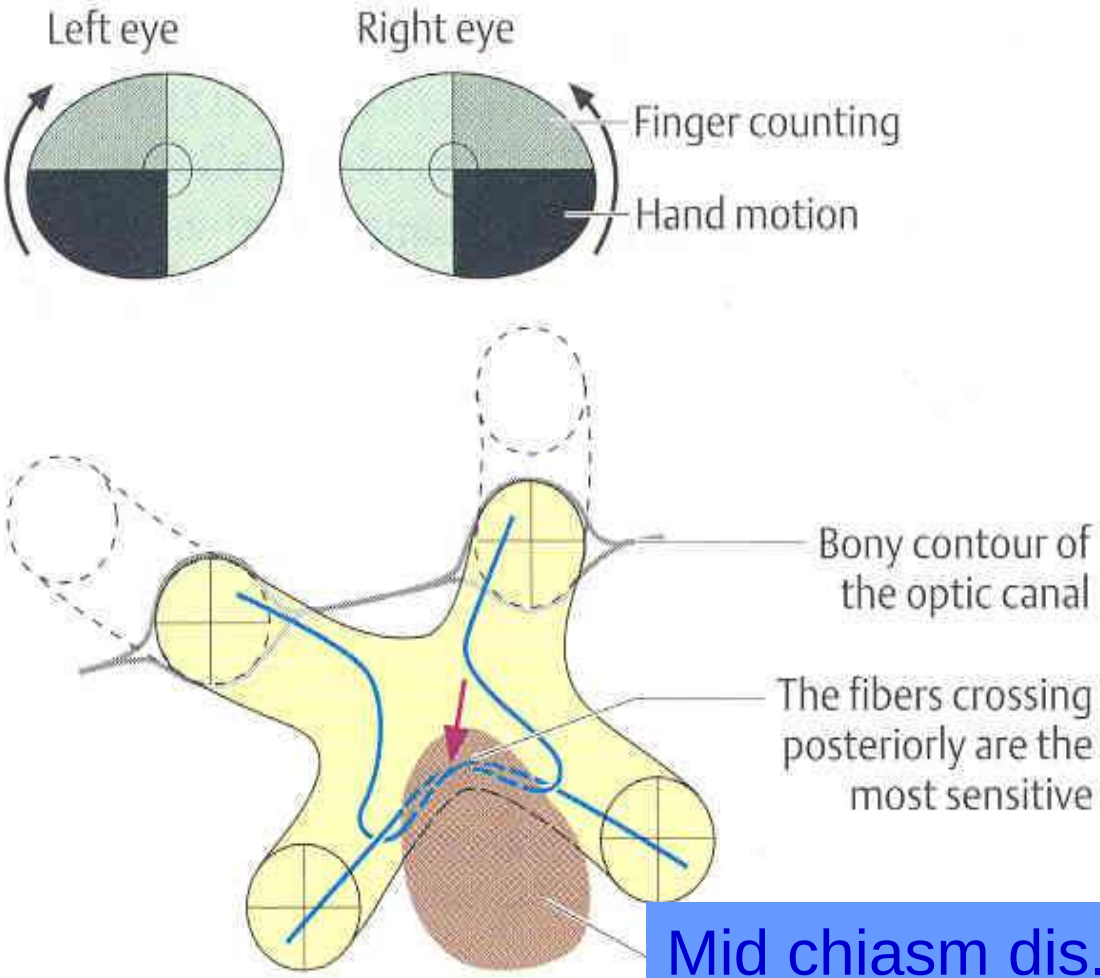

Fig. 14.**6** The visual field defect begins bilaterally in the inferior temporal quadrants and can progress to complete bilateral temporal hemianopsia.

Mid chiasm dis.

Binasal hemianopia is rare

Almost always due to Vascular aneurysm

Lateral compression of the optic chiasm by an aneurysm in the internal carotid artery.

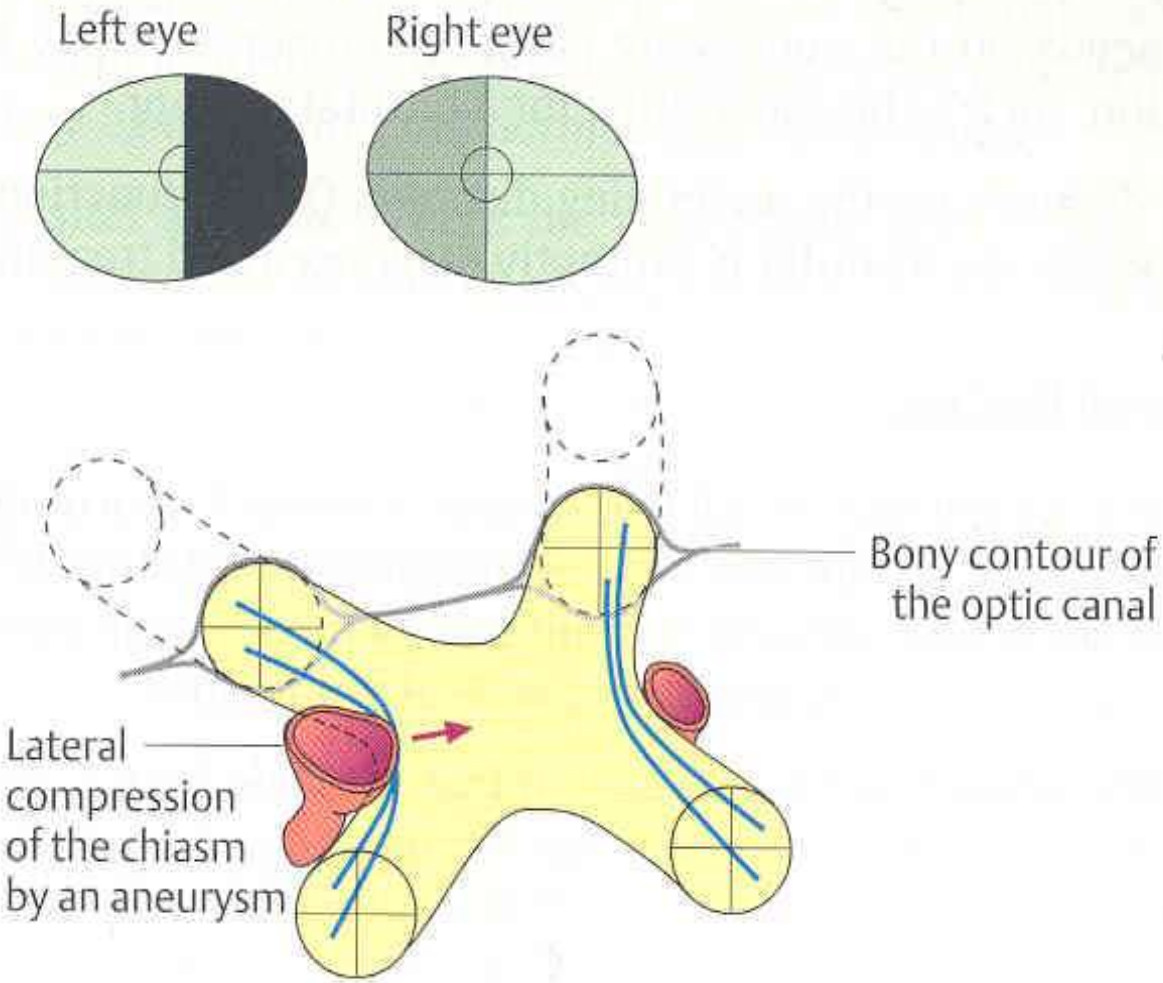

Fig. 14.8 The visual field defect begins on the same side as hemianopsia extending nasally and can progress to bilateral nasal hemianopsia.

Differential diagnosis Bitemporal hemianopia

- Tilted disc
- ON coloboma
- Dominant optic atrophy
- Functional
  - Nasal retinoschisis
  - Nasal RP
  - Dermatochalasia of upper lid
  - Bilaterally enlarged blind spot

They don’t respect vertical line

Optic tract

- *Optic tract syndrome:*

- ✓ Most commonly due to mass lesion
- ✓ Related to aneurysms.
- ✓ Anterior lesions :Incongruous contralateral Homonymous hemianopia
- ✓ Posterior damage :Congruous contralateral Homonymous hemianopia
- ✓ Bow-tie optic atrophy
- ✓ Mild contralateral RAPD

Homonymous Hemianopia

Most common cause: Ischemic processes



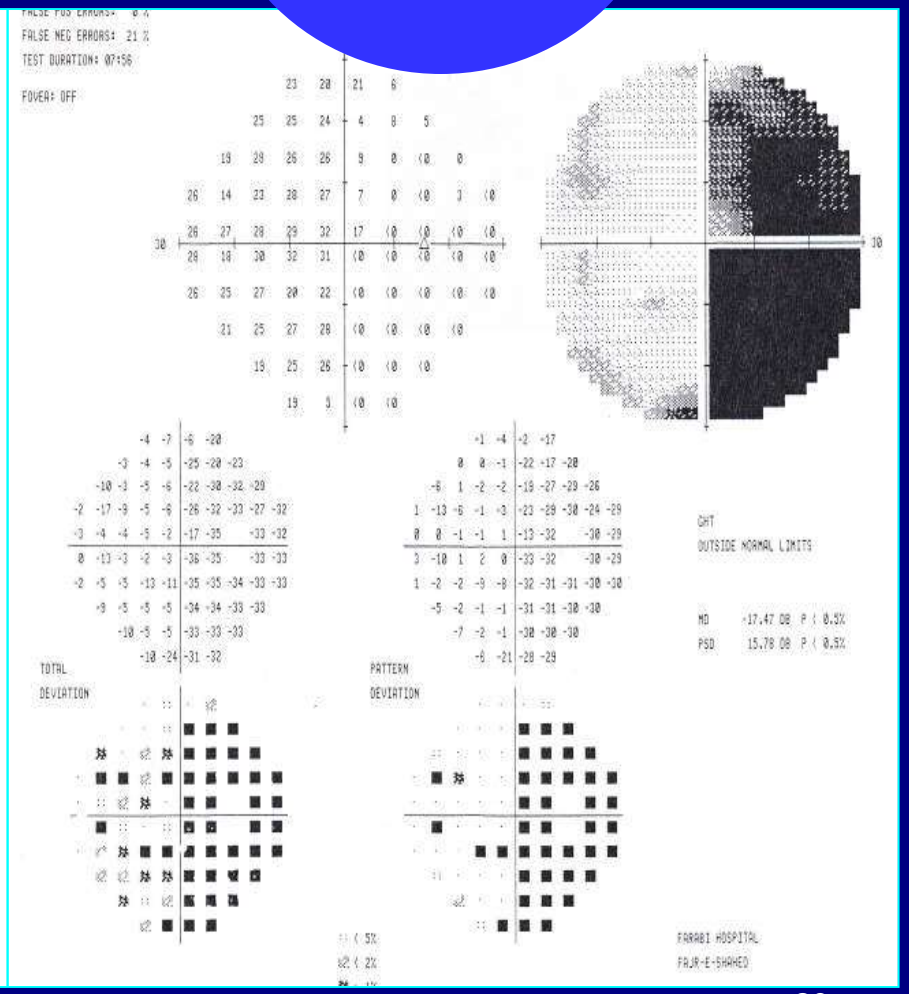

Lateral Geniculate Body

- Lesions in this region therefore can give highly localizing visual field defects.
- Congruous horizontal sectoranopia :**distribution of the posterolateral choroidal artery**
- Loss of the upper and lower homonymous quadrants (also called "quadruple sectoranopia") : **disruption of the anterior choroidal artery**
- Visual field defects respect the vertical meridian
- Very incongruous homonymous hemianopias can also occur with lesions of the LGB.
- Sectoral optic atrophy occurs with LGB lesions

Lateral Geniculate Body

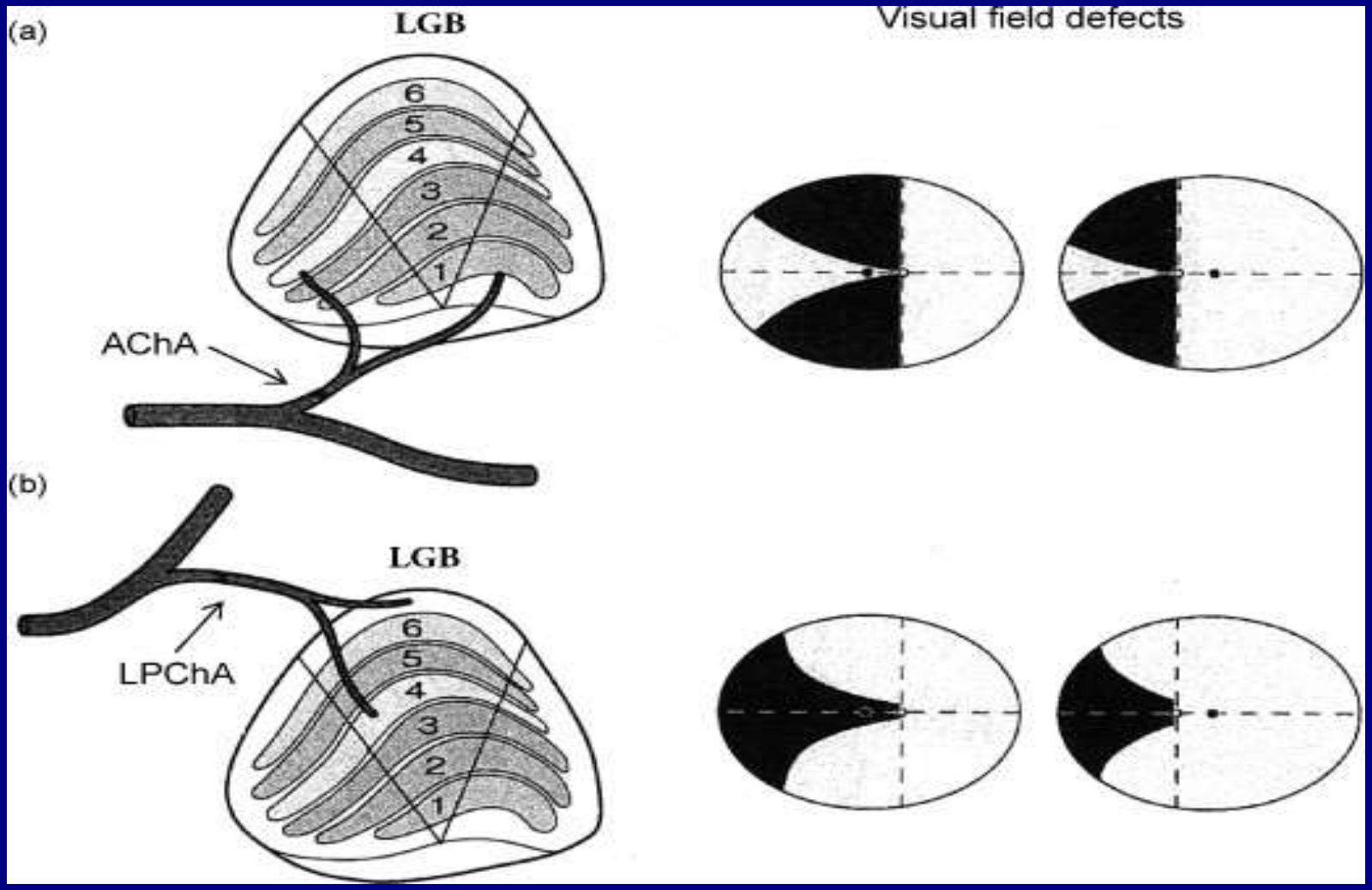

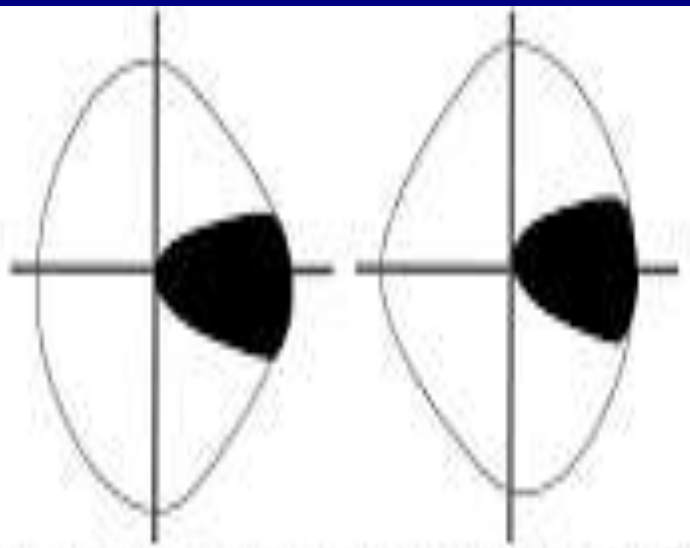

Homonymous horizontal sectoranopia

Posterior choroidal artery occlusion

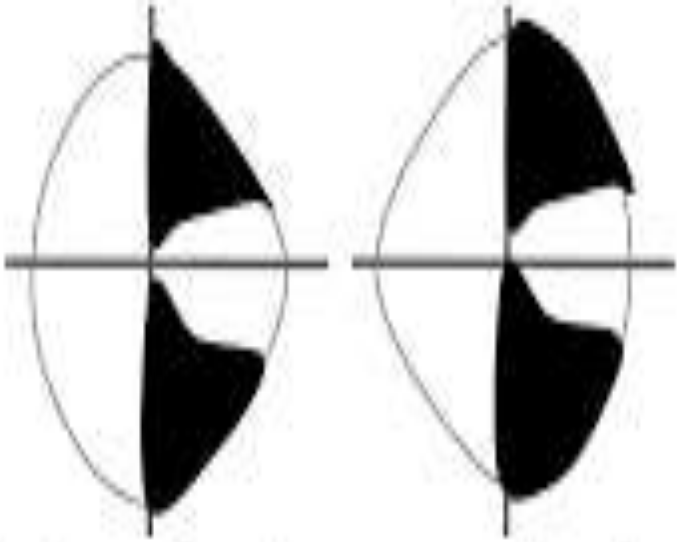

Sector-sparing homonymous hemianopia

Anterior choroidal artery occlusion

Temporal lobe

- Inferior visual fibers course from the LGB anteriorly in the Meyer loop of the temporal lobe
- Superior fibers tend to course more directly posteriorly in the parietal lobe
- Contralateral superior, incongruous, homonymous quadrantanopia defects spare fixation (pie in the sky)
- Damage to the temporal lobe anterior to the Meyer loop does not cause visual field loss.

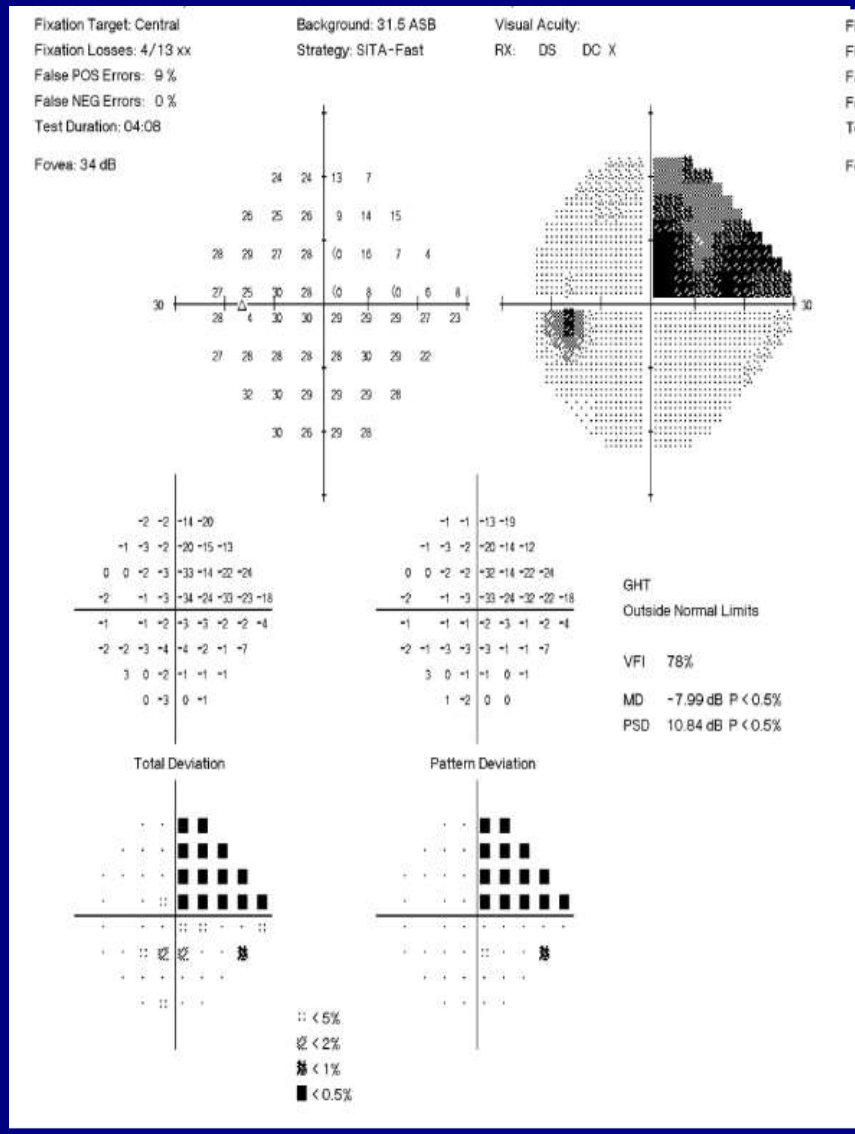

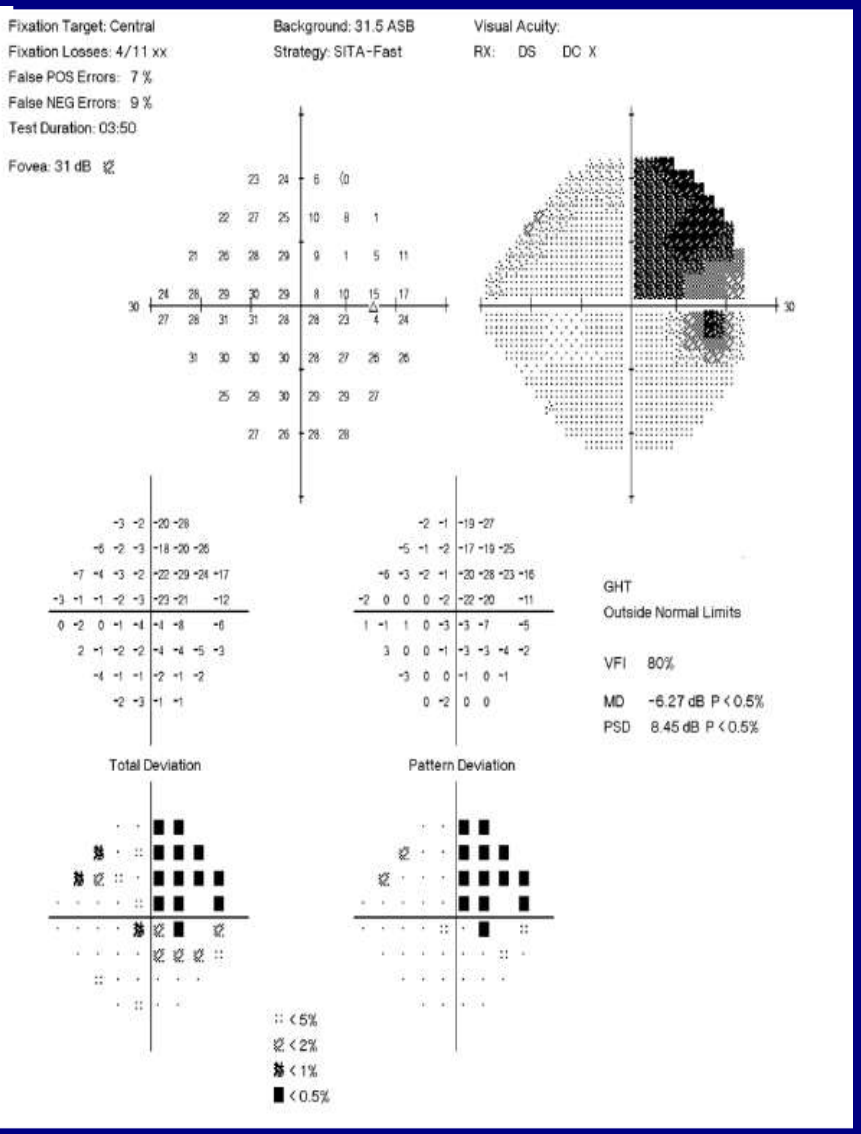

Left eye **Right eye**

Parietal lobe Lesions

- Involve superior fibers first
- Contralateral inferior homonymous hemianopia(pie in the floor)
- Extensive lesions involve the superior visual fields but remain denser inferiorly.
- Damage to pursuit pathways ,optokinetic nystagmus (OKN).
- Homonymous hemianopia and reduced OKN response
- Homonymous hemianopia due to a lesion of the optic tract or occipital lobe will yield an intact OKN response.

Parietal lobe Lesions

- Parietal lobe syndromes :
- agnosia
- apraxia
- Lesions of the dominant parietal lobe:
- Acalculia
- Agraphia
- Finger agnosia
- Left-right confusion
- Lesions in the nondominant parietal lobe
- contralateral neglect.

Right Inferior Homonymous Quadranopia



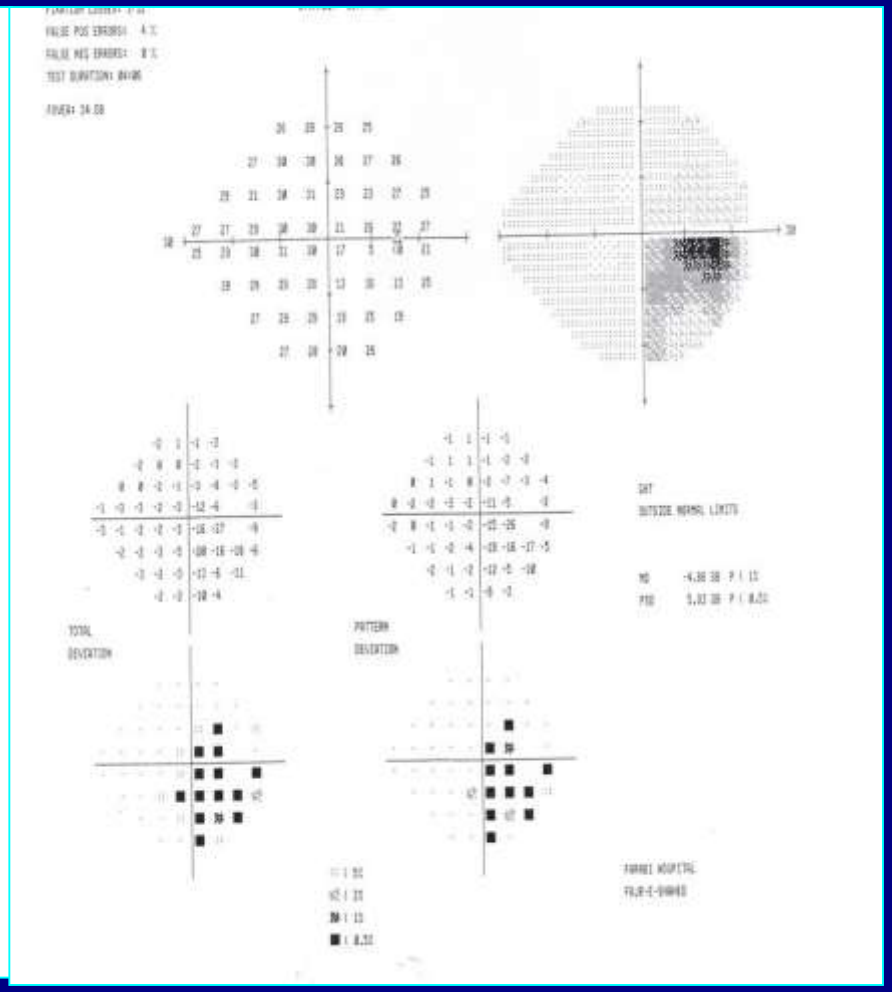

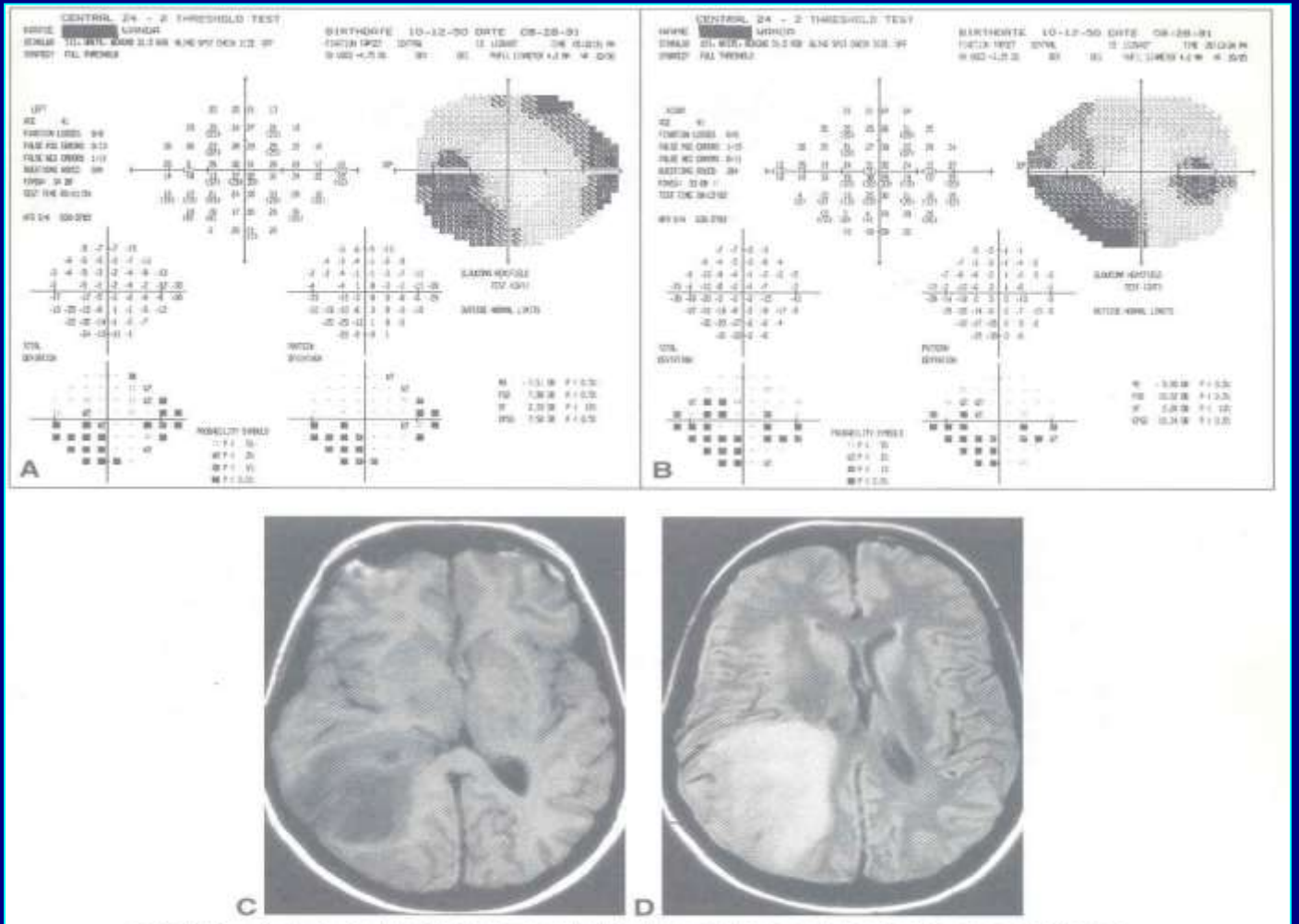

FIG IV-9—A 41-year-old woman presented visual problems and headache. Her acuity was 20/20 OD and 20/30 OS. **A, B,** Her visual fields demonstrate an incomplete inferior left homonymous hemianopia and suggest an enlarged blind spot on the right side as well as superior arcuate defects. MRI shows a lesion in the parietal lobe that is low intensity on T1-weighted images **(C)** and high intensity on proton density images **(D)**. These findings are compatible with a glioblastoma. The arcuate defects were due to papilledema.

Fig. 5-10 Right parietal infarct. A 72-year-old male was evaluated for a left homonymous visual field defect. Optokinetic nystagmus was diminished when the stimulus was moving toward the right and was normal in the opposite direction. **A,** Automated perimetry showed a left homonymous visual field defect that was denser inferiorly, with intermediate congruity. **B,** CT of the brain (axial image) revealed a wedge-shaped area of low attenuation in the right parietal lobe *(between arrows),* most consistent with a subacute infarct.

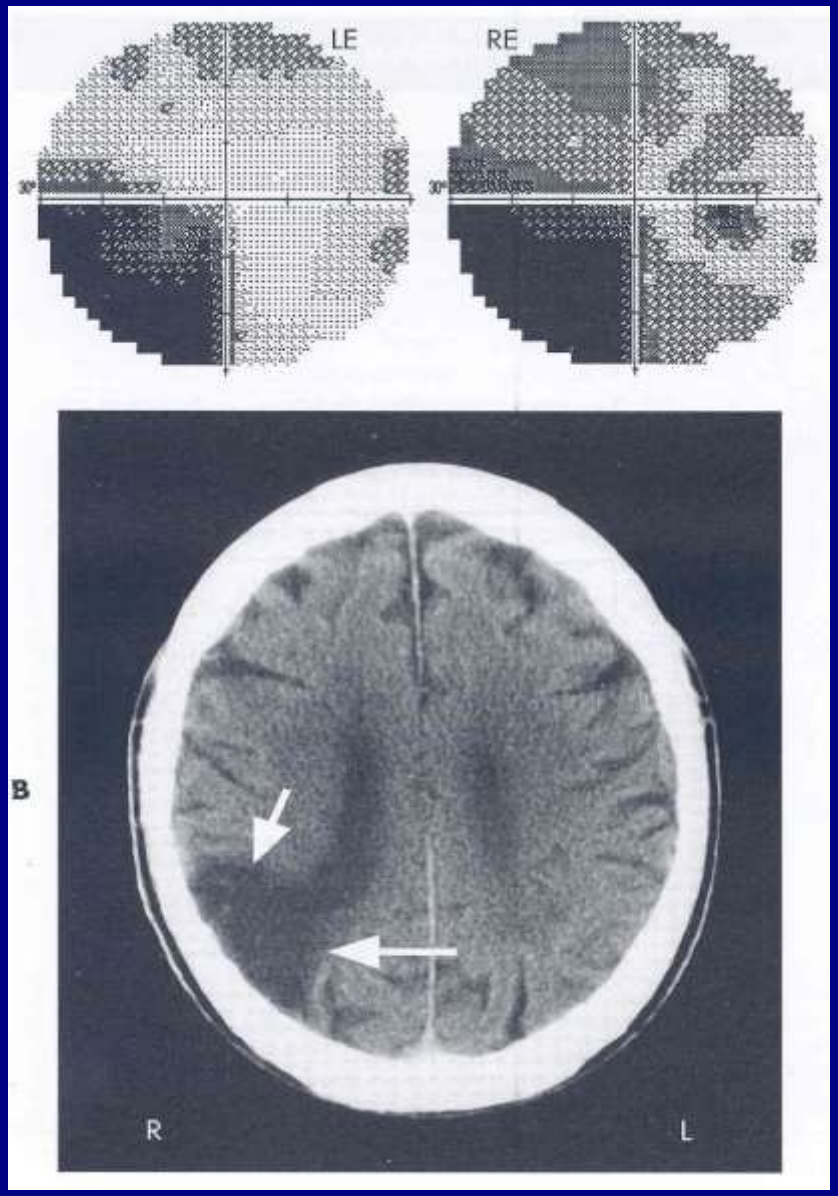

Occipital lobe

Hemifields contralateral to the lesion

- Congruous homonymous hemianopia, sparing the fixational region(Key Hole appearance)
- Monocular temporal crescent defect involving only the most anterior portion of the occipital lobe
- Homonymous lesion sparing the temporal crescent
- Homonymous hemianopia scotoma
- Bilateral altitudinal defects
- Checkerboard defect
- Homonymous hemianopia that respects both the vertical and horizontal meridians

Congruous homonymous hemianopia, sparing the fixational region(Key Hole appearance)

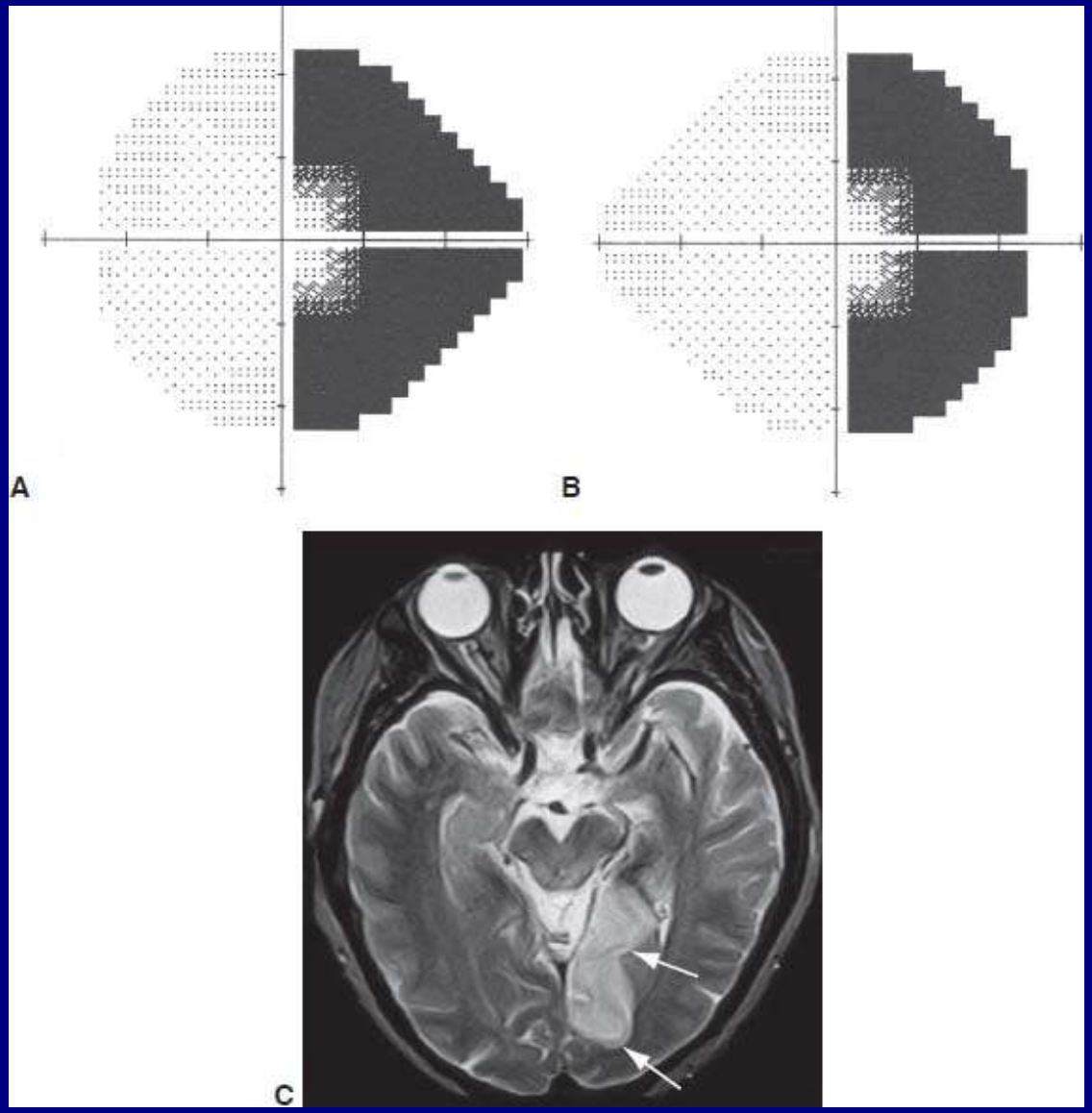

Occipital lobe

- Checkerboard defect

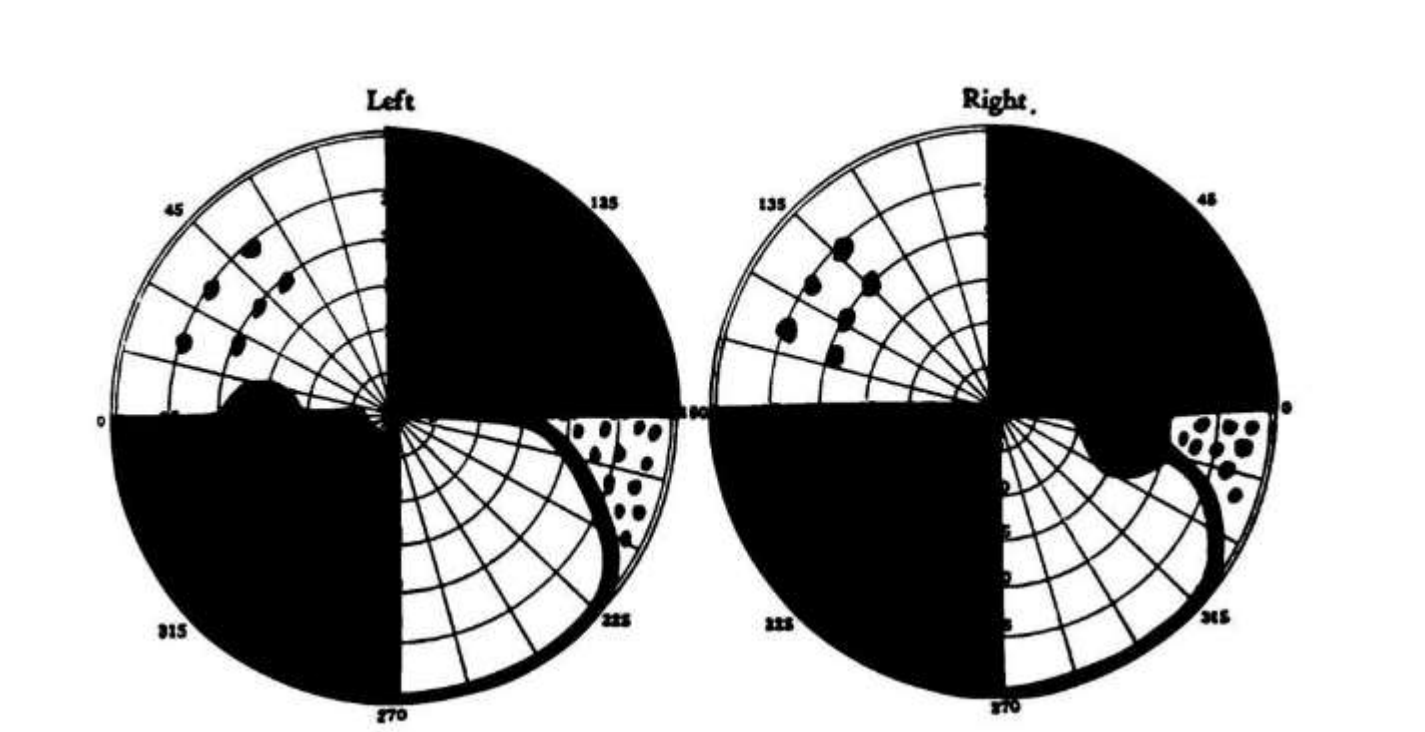

Bilateral altitudinal defects

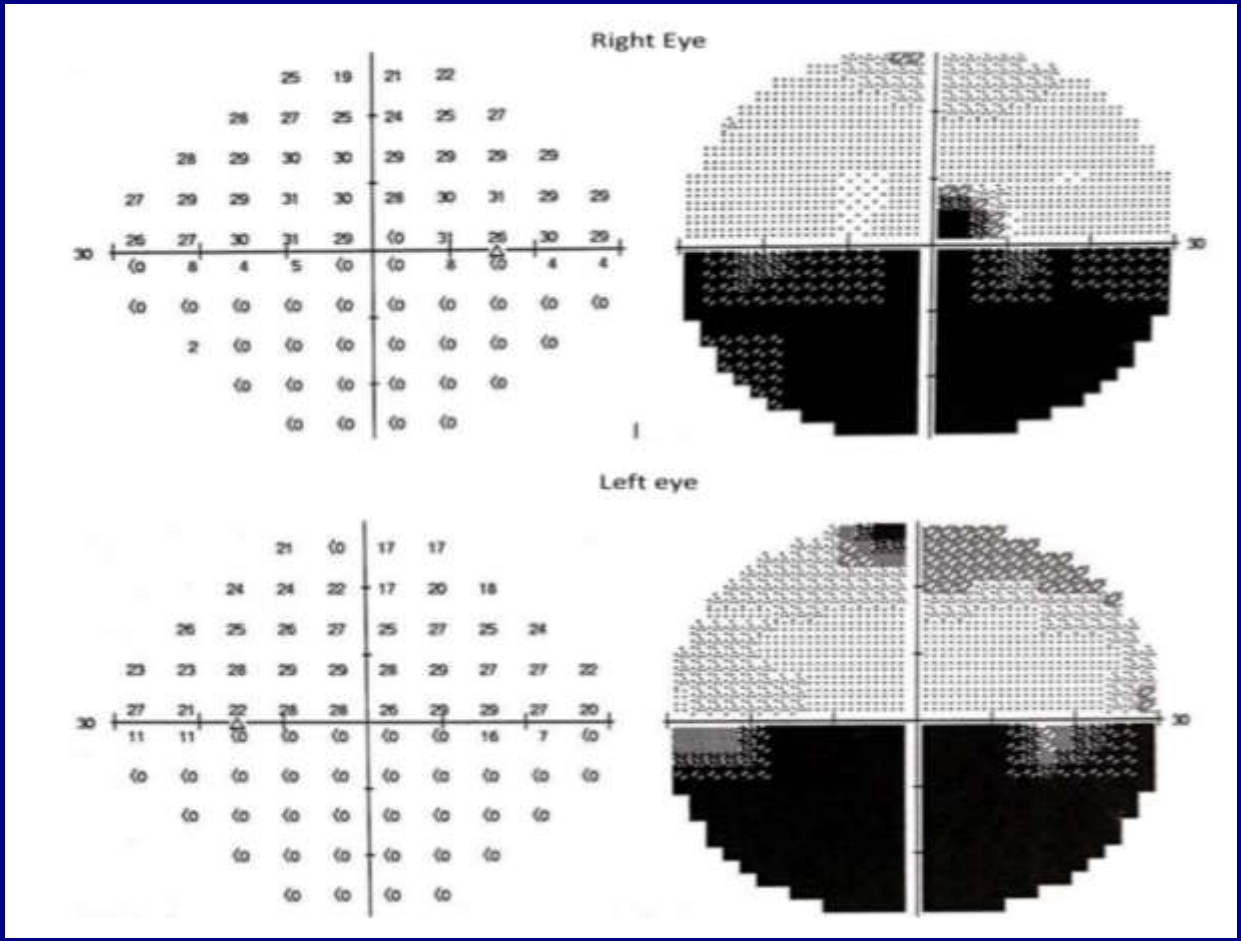

Altitudinal field defect

- Most commonly due to optic nerve or retinal disease
- Bilateral symmetric postchiasmatic lesion
  - Medial LGB
  - Occipital lesion

Total field loss sparing fovea