In the name of
GOD

Geriatrics

Aging and its consequences in the mouth

Tooth loss

- Tooth loss is an important marker indicating the oral health status of a community, and reveals the history of oral and dental conditions during one's lifespan
- The mean frequency percentage of carious and filled teeth is 22%-35% in developed countries
- The global age-standardized prevalence (proportion) of edentate individuals decreased from 4.4% (95% uncertainty interval [UI]:4.1%-4.8%] in 1990 to 2.4% (95% UI: 2.2%-7.2%) in 2010.
- The global age-standardized incidence rate decreased from 374 cases/100 000 people per year (95% UI: 374-706) to 205 cases (95% UI: 187-226)

In Iran

- the age-standardized prevalence of severe tooth loss is significantly higher than the global average
- The age standardized prevalence (proportion) of severe tooth loss in 2010 was .29-.42 worldwide
- whereas the standardized incidence rate (per 100 000 person-years) of severe tooth loss in 2010 was calculated to be 260.9-351 in Iran.

Dental status of the Iranian elderly

- (48.7%) were completely edentulous (95% CI: .49-.49 (51.7%)
- were dentate (95% CI: .52-.52)
- mean number of remaining teeth was 5.73 (95% CI: 5.73-5.73)
- Approximately 50% of the elderly in Iran are completely edentulous.

Frequency of edentulism in Iranian provinces and their confidence intervals

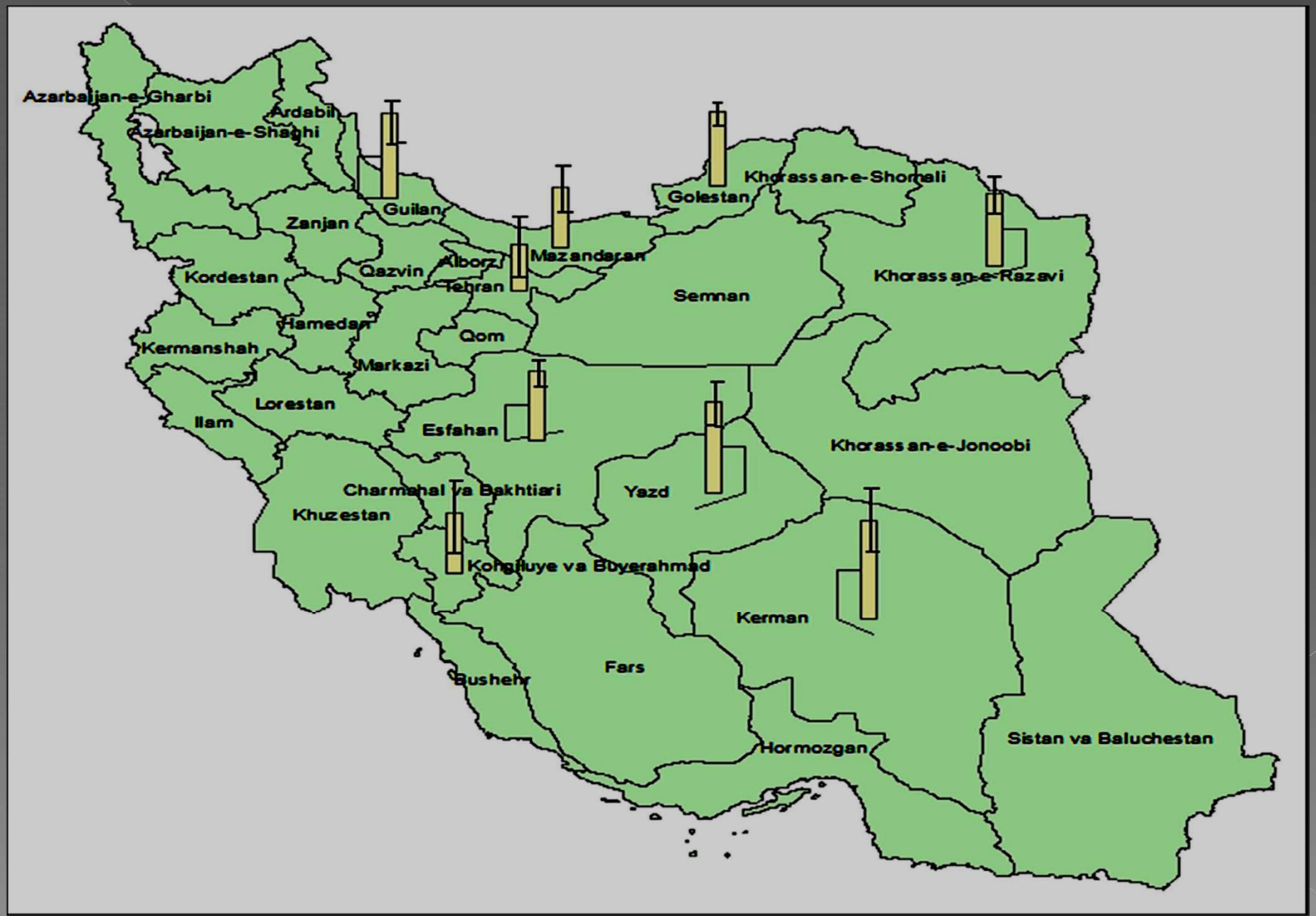

Gender differences

- Gender
- Hormonal
- Skeletal
- Skin & mucosa

Oral health related quality of life

- OHIP 14
- 7 area

OHIP					
Because of problems with your teeth, denture or mouth have you	**Never (%)**	**Hardly ever (%)**	**Occasionally (%)**	**Fairly often (%)**	**All of the time (%)**
1**. Had trouble pronouncing words**	0	1	2	3	4
2. **Felt sense of taste has worsened**	0	1	2	3	4
3. **Had painful aching in the mouth**	0	1	2	3	4
4. **Found in uncomfortable to eat foods**	0	1	2	3	4
5. Have been self-conscious	0	1	2	3	4
6. Felt tense	0	1	2	3	4
7. Had an unsatisfactory diet	0	1	2	3	4
8. Had to interrupt meals	0	1	2	3	4
9. Found it difficult to relax	0	1	2	3	4
10. Have been a bit embarrassed	0	1	2	3	4
11. Have been irritable with other people	0	1	2	3	4
12. Had difficulty doing usual jobs	0	1	2	3	4
13. Felt life in general was less satisfied	0	1	2	3	4
14. Have been totally unable to function	0	1	2	3	4

Aging

- Salivary Quantity in Health
  - No changes in major secretions (parotid, submandibular)
  - No changes in minor secretions
- Salivary Quality in Health
  - No general changes in salivary constituents

Multi morbidity

- Mental
- Hormonal
- Coronary

Menopause

- Average age of onset of menopause in USA is 50 years
- Oral symptoms common, particularly among those with systemic complaints
- Cross-sectional and longitudinal studies have failed to provide significant and reproducible evidence that salivary flow is affected by menopause
  - Oral complaints most likely the result of the types and numbers of xerostomic medications taken
    - Anti-hypertensives, anti-depressants, and anti-histamines are common in this group

Systemic Diseases

- Sjögren's Syndrome
- Sarcoidosis
- Cystic Fibrosis
- Diabetes
- Alzheimer's Disease
- AIDS
- Graft vs Host Disease
- Dehydration

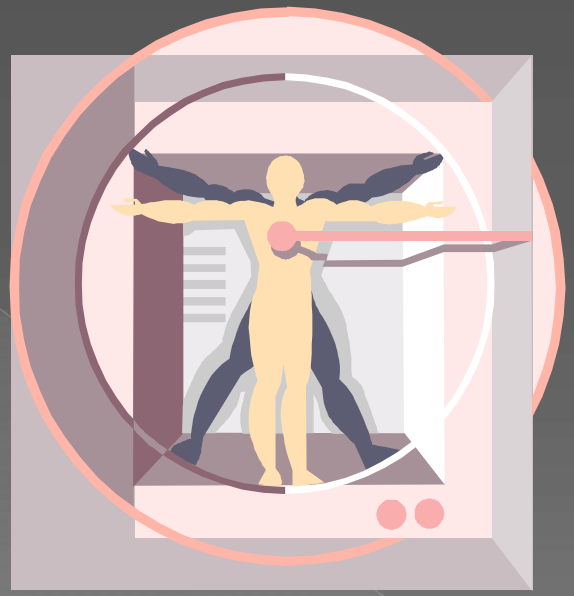

Alzheimer's Disease

- A neurodegenerative disorder leading to a decrease in cognition and mobility
- May affect the neurological component to salivary production and/or flow
- Xerostomic medications
  - Complicated by behavior which makes it difficult to maintain a healthy dentition
    - Poor oral hygiene
    - Poor cooperation for dental care and treatment in a conventional setting

Periodontal disease and dental neglect in an institutionalized elderly patient with dementia

Severe root surface caries in a patient with Parkinson's disease and drug-induced
salivary hypofunction

Marginal gingivitis in a patient with hypothyroidism

Diabetes

- Uncontrolled blood glucose levels may contribute to xerostomia
- Medications may induce xerostomia
- May get enlargement and inflammation of parotid glands (common in endocrine diseases)
- Difficulty to ward off infection: candidiasis, gingivitis, periodontitis, and caries

Gingivitis and periodontitis. Vertical bone loss in a patient with poorly controlled diabetes

Atrophic candidosis in a patient with poorly controlled diabetes.

Age - related changes in oral health

Oral mucosa

Dentition

Periodontium

Salivary glands

Taste and smell

Mastication and swallowing

Oral – facial Pain

Histologic Changes in Oral Mucosa

- ✓ Epithelial thinning
- ✓ Less – prominent retepegs
- ✓ Decreased cellular proliferation
- ✓ Loss of submucosal elastin and fat
- ✓ Increased fibrotic connective tissues
- ✓ Degenerative alteration in collagen

Oral Mucosal Changes

- ✓ Age related structural & immunologic changes
- ✓ Local trauma
- ✓ Systemic disease
- ✓ Medications
- ✓ Poor nutritional status

Oral mucosal Diseases

- Varicosis
- Atrophy of tongue
- Lichen planus
- Leukoplakia
- Fissured tongue
- Geographic tongue
- Oral cancers

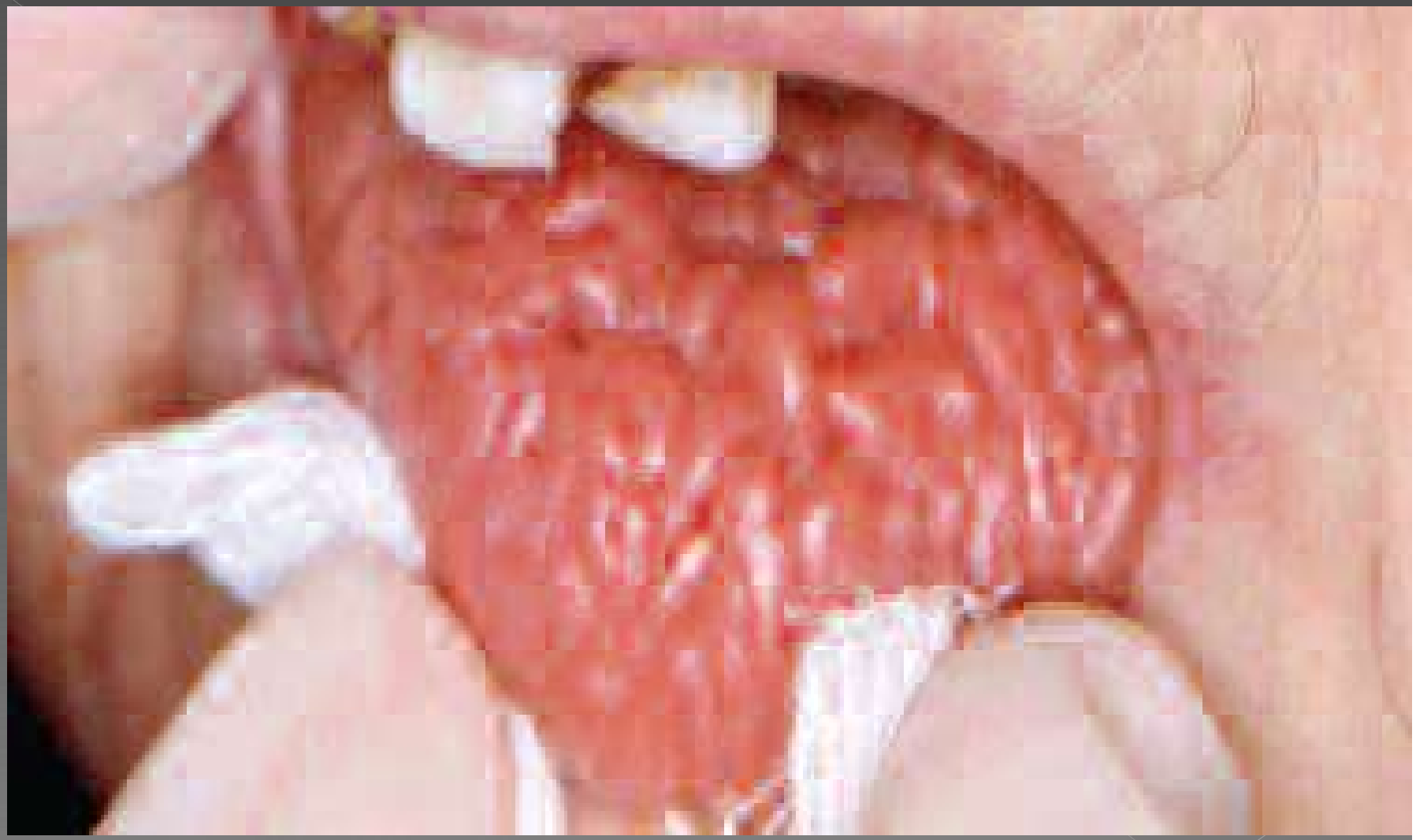

Fissured and desicated tongue secondary to radiotherapyinduced salivary hypofunction.

Major recurrent aphthous stomatitis nonresponsive to topical and systemic corticosteroids.

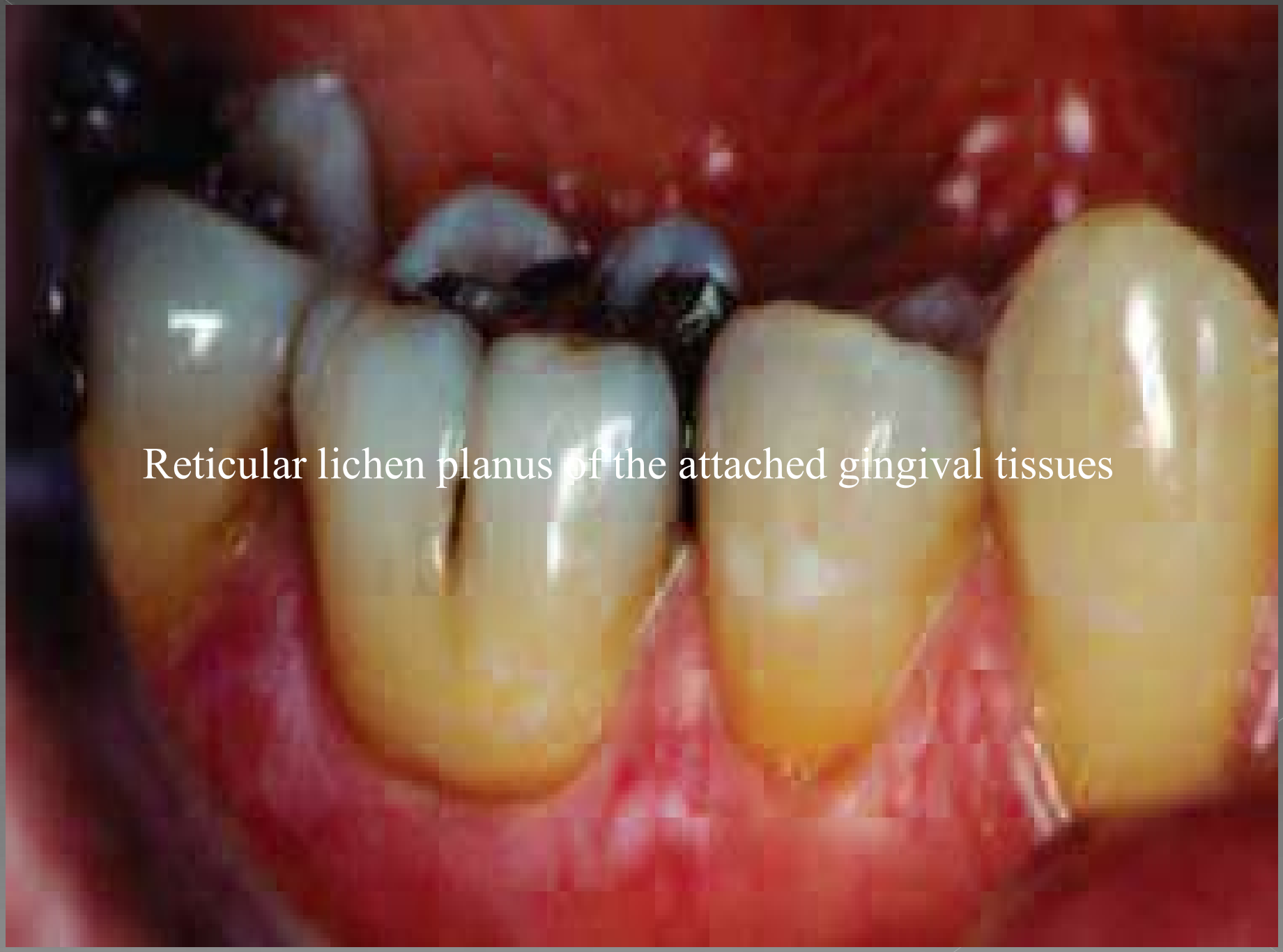
Reticular lichen planus of the attached gingival tissues

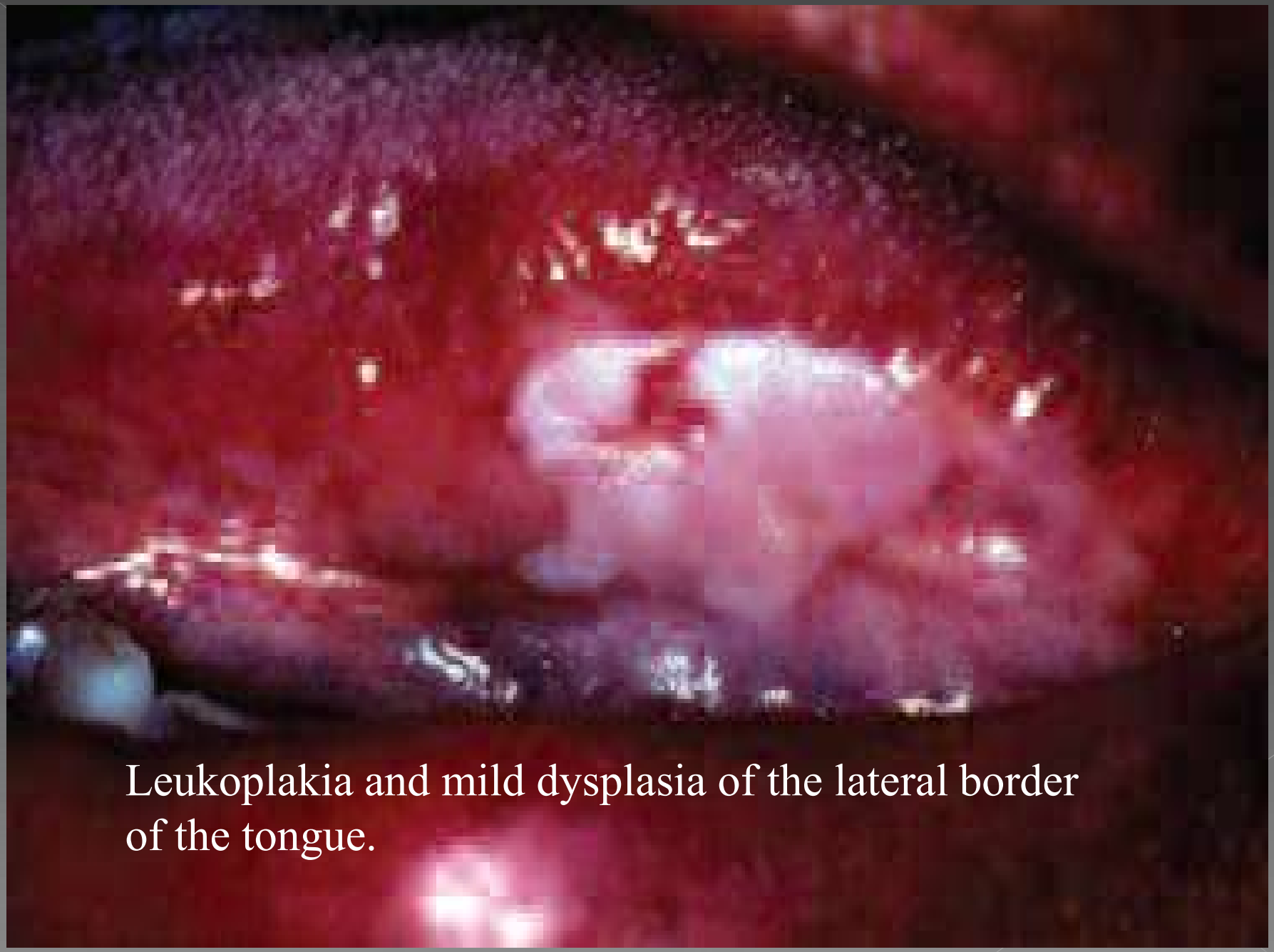

Leukoplakia and mild dysplasia of the lateral border of the tongue.

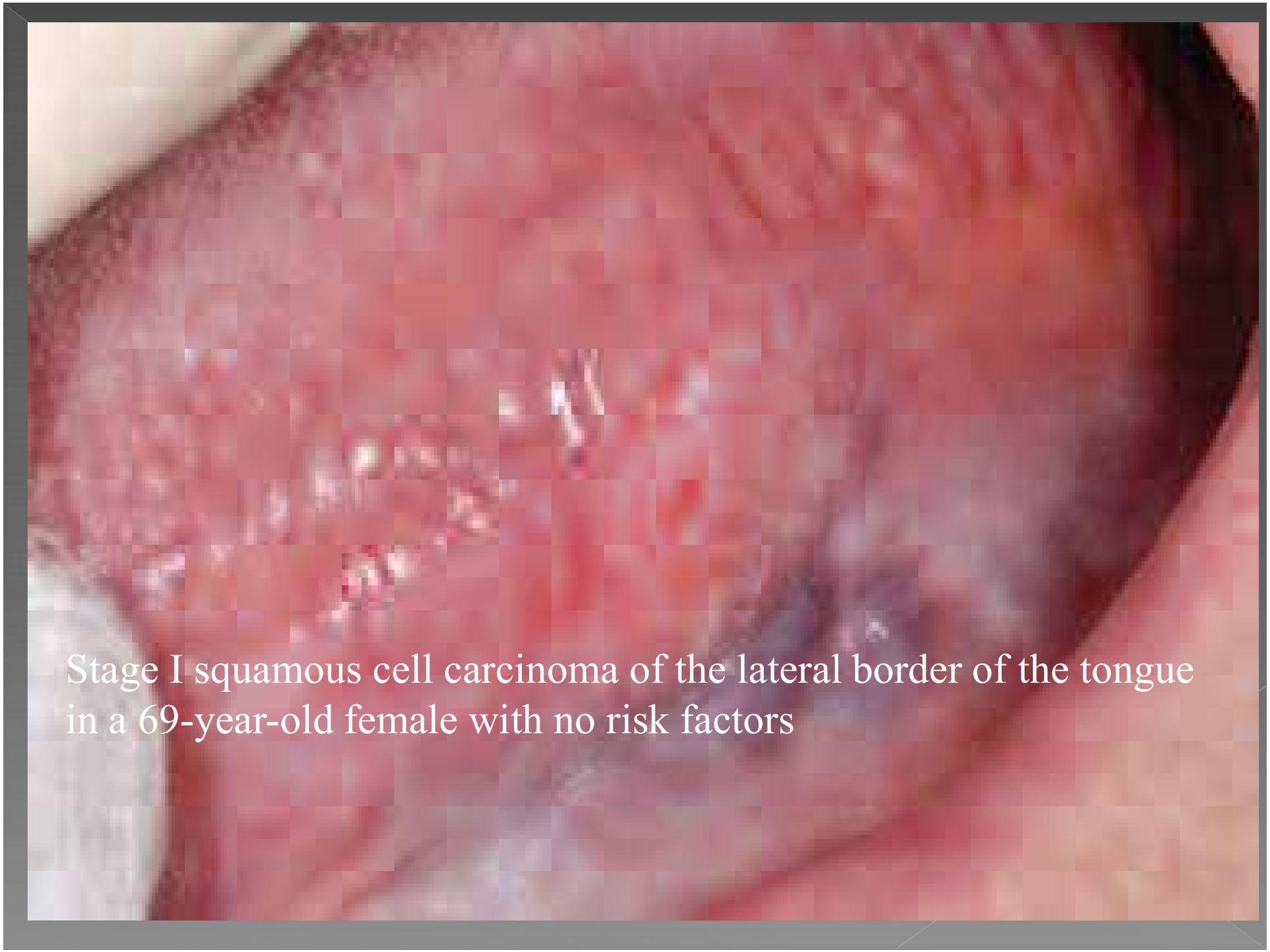

Stage I squamous cell carcinoma of the lateral border of the tongue in a 69-year-old female with no risk factors

Palatal leukoplakia and erythroplakia with severe dysplasia

Lymphoma of gingival tissues

Lesions associated to dentures

- Candidiasis psudomemberanus
- Inflamatory papilary hyperplasia
- Angular keilitis
- Candida leukoplakia
- Median Rhomboid glossitis
- Erythematou candidiasis

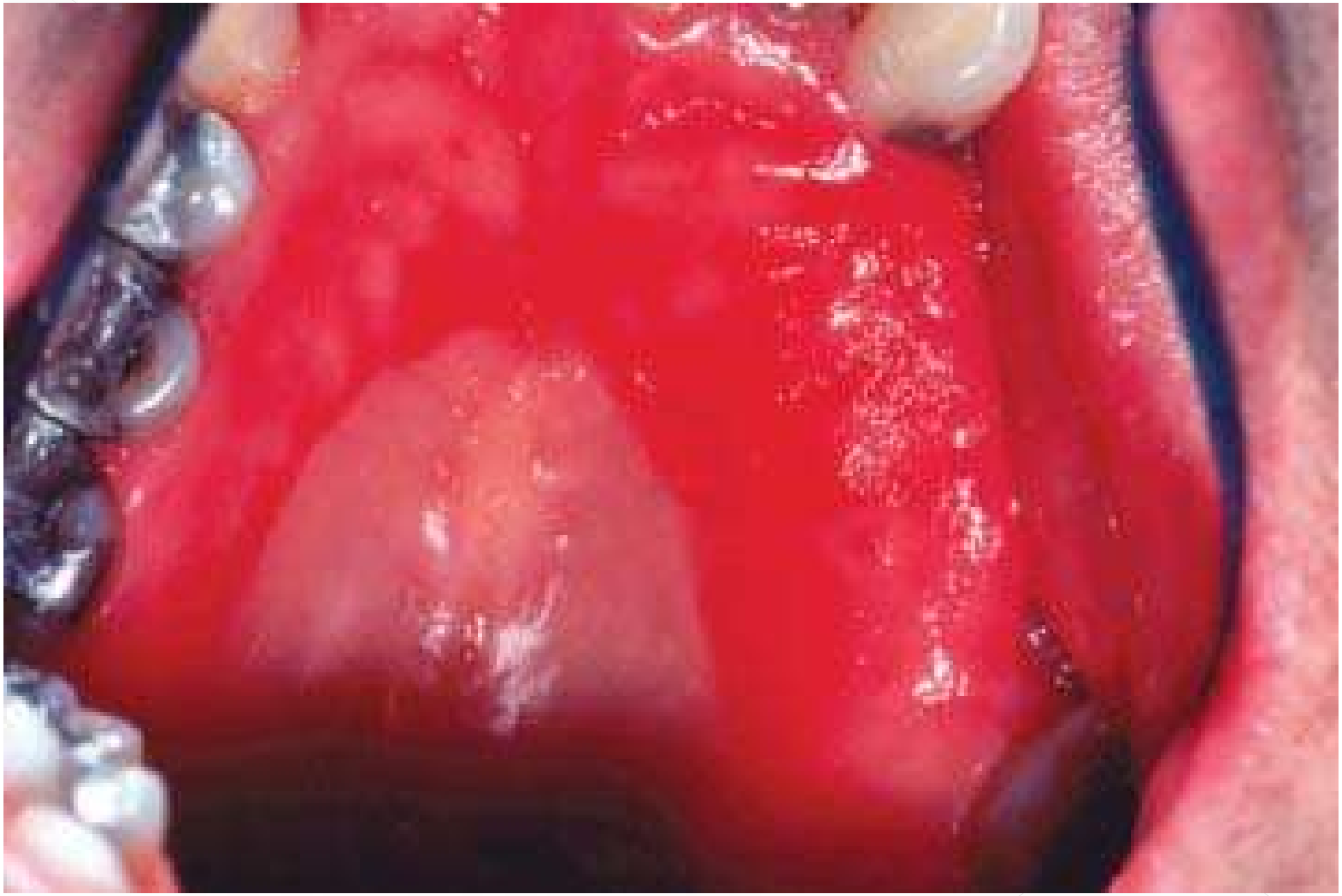

Chronic atrophic candidosis (denture stomatitis) in a patient wearing a partial
metal-based removable prosthesis

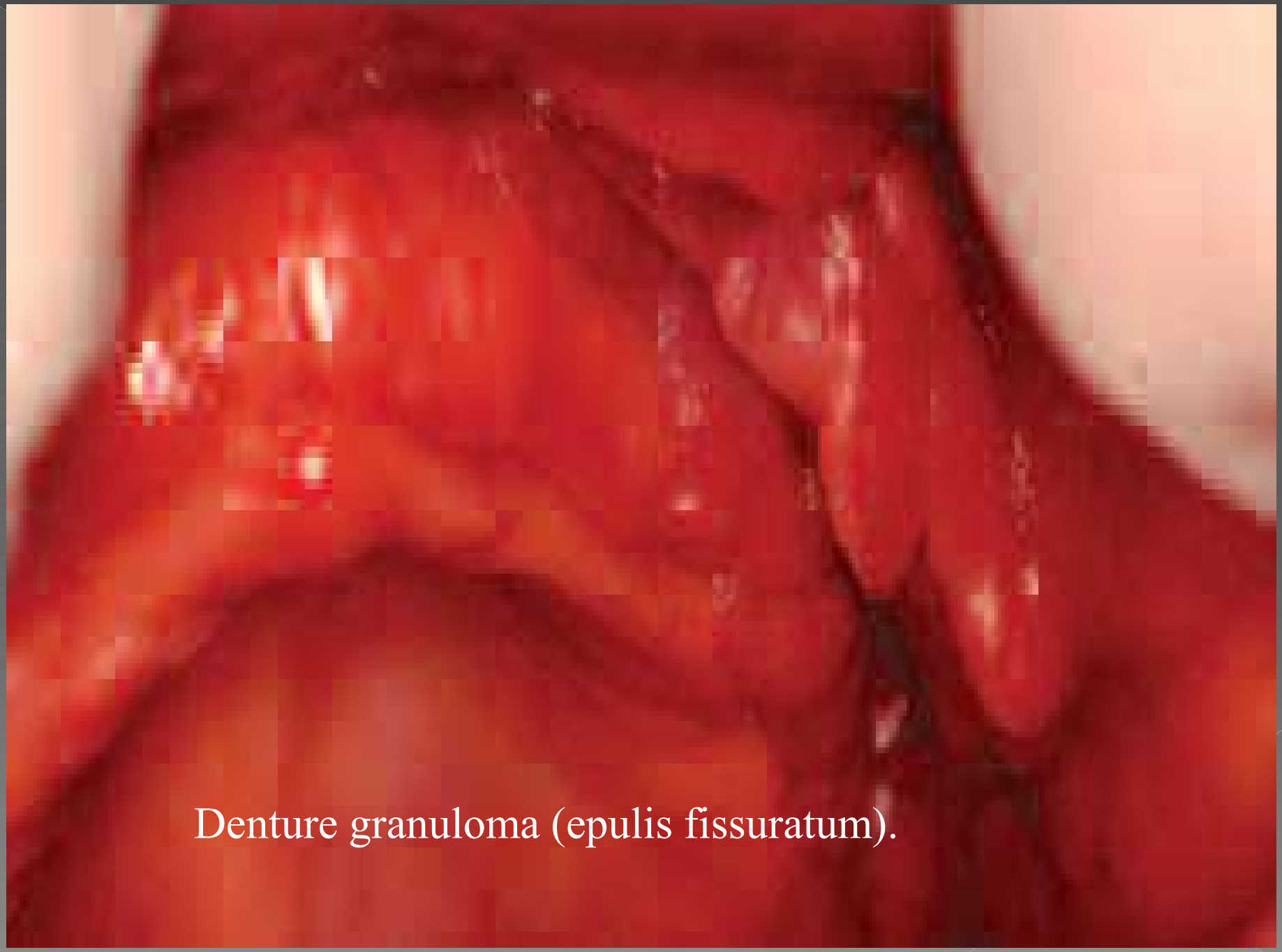

Denture granuloma (epulis fissuratum).

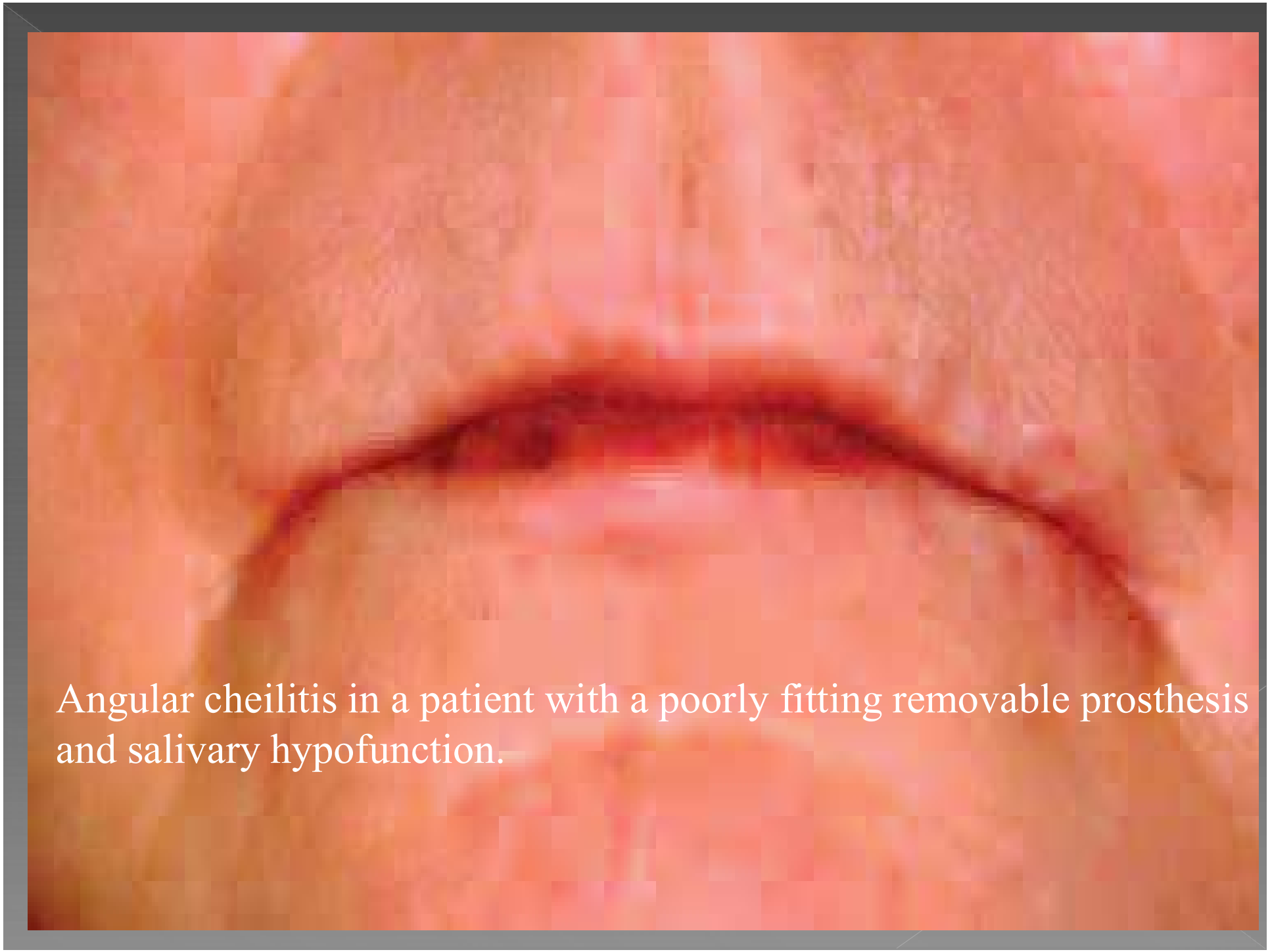

Angular cheilitis in a patient with a poorly fitting removable prosthesis and salivary hypofunction.

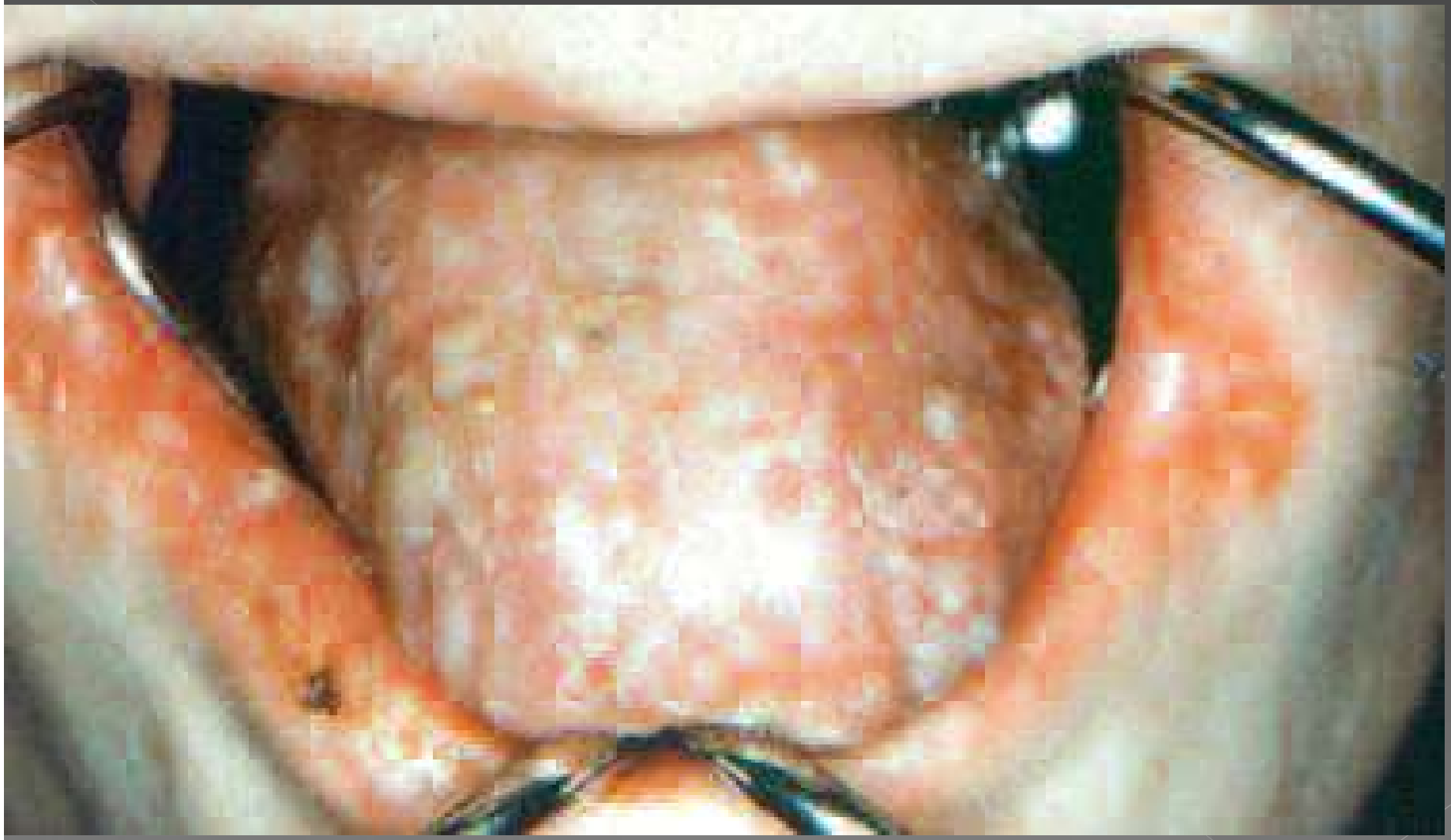

Acute pseudomembraneous candidosis secondary to antibiotic therapy.

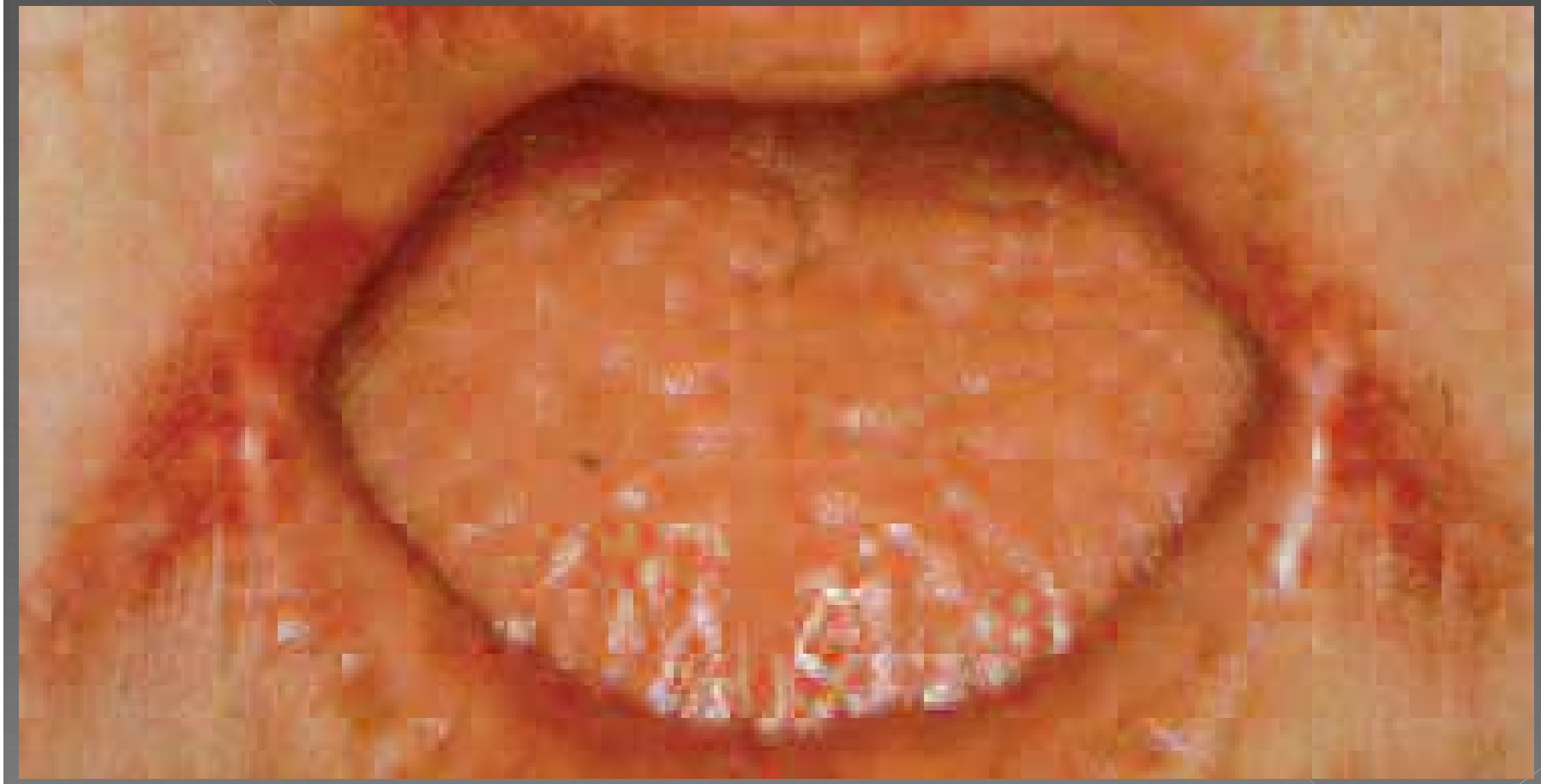

Acute atrophic candidosis and angular cheilitis secondary to antibiotic therapy

Chronic hyperplastic candidosis

Infectious diseases

- Candidiasis
- Herpes simplex
- Shingles

Changes in the dentition due to aging

- External tooth changes
  - ✓ Discoloration (yellowish brown color)
  - ✓ Less of enamel due to attrition, abrasion and erosion
  - ✓ Exposure of underlying dentin which produce sclerotic and secondary dentin in response to trauma, caries and masticary forces

Changes in the dentition due to aging

- ✓ Perception sensitivity reduction and pain perception
- ✓ Cementum thickness
- ✓ Reduction of pulpal dimentions

Continue

Decrease in the size of pulp

- ✓ Secondary dentin deposition
- ✓ Pulpal calcifications
- ✓ External root resorption
- ✓ Increased density and volume of pulpal collagen fibers
- ✓ Diminished nerve supply

Coronal and root surface caries

- ✓ Gingival recession
- ✓ Dental plaque
- ✓ Diminished salivary gland function
- ✓ Disturbances in oral motor function
- ✓ Difficulty in performing oral hygiene

Periodontium

- ✓ Gingival recession
- ✓ Loss of periodental attachment
- ✓ Loss of alveolar bone
- ✓ Age related immunologic changes
- ✓ Alter the host response to dental plaque micro organisms

Periodontium

- ✓ Several systemic conditions and medications
  - Osteoporosis
  - Diabetes
  - Several classes of medications like calcium channel blockers, antiseizure drug, imunosupressant
- ✓ Sociobehavioral factors
  - Smoking
  - Irregular dental visits
  - Psychosocial stress
  - Poor socioeconomic status

Continue

Oral - Facial Pain

1) Intra oral pain
2) Extra oral pain

Intra oral pain

- ✓ Tooth and periodontium
- ✓ Nerve injury
- ✓ Burning mouth syndrome
- ✓ Oral mucosal neoplasia and mucosal infection
- ✓ Bone trauma and infection

Extra oral pain

- ✓ Temporomandibular joint
- ✓ Nerve injury
- ✓ Muscles of mastication (masticatory myalgia)
- ✓ Neuralgia
- ✓ Atypical facial pain

Salivary Glands (Xerostomia)

- ✓ Dental caries
- ✓ Oral mucosal infections
- ✓ Sensory disturbances
- ✓ Speech dysfunction
- ✓ Decreased nutritional intake
- ✓ Difficulty in chewing, swallowing and denture retention

Salivary hypofunction and xerostomia in a patient who completed a 7-week course of external beam radiotherapy for a squamous cell

Fissured tongue in a patient with salivary hypofunction secondary to Sjögren's syndrome.

Taste and smell

- ✓ Diminished sensitivity to olfactory cues
- ✓ Temporary or permanent taste changes due to medications, chemo and radiotherapy, trauma, surgery and neurologic events

Mastication and swallowing

Oral motor distrurbance

- ✓ Cerebrovascular and nerologic disease
- ✓ Alzheimer's disease
- ✓ Head and neck cancer
- ✓ System disorder (diabetes)

Management

- Dental
- Periodontl
- Oral mucosal changes
- Infections
- Saliva
- Taste and smell
- Mastication
- Toothless