



POSTPARTUM HEMORRHAGE

dr .zangenen 2021

Management approaches requiring laparotomy

EVALUATION OF THE ABDOMEN

- Following vaginal birth, midline laparotomy provides the best exposure of both the pelvis and abdomen
- A self-retaining retractor (eg, Balfour, Bookwalter, or Omni) helps to provide adequate lateral and superior exposure (superior exposure will be required if access to the aorta is needed).

-
- The abdominal cavity is irrigated to remove blood and clots and inspected for the source of bleeding, which is usually from the uterus. The source of bleeding is often readily apparent (atony, retained placental fragments, uterine laceration, uterine incision) but may not be immediately recognized when it is inside the uterine cavity after vaginal birth or after closure of the uterine incision at cesarean, retroperitoneal (including vaginal and vulvar hematomas from trauma to branches of the pudendal or uterine arteries and veins), or due to a rupture of the posterior uterine wall. These sites should be systematically evaluated in patients with compensated shock (normal blood pressure with increasing heart rate).

-
- Intra-abdominal blood without an obvious uterine rupture or bleeding vessel may be due to hepatic or splenic rupture, or rupture of a visceral artery aneurysm or pseudoaneurysm.

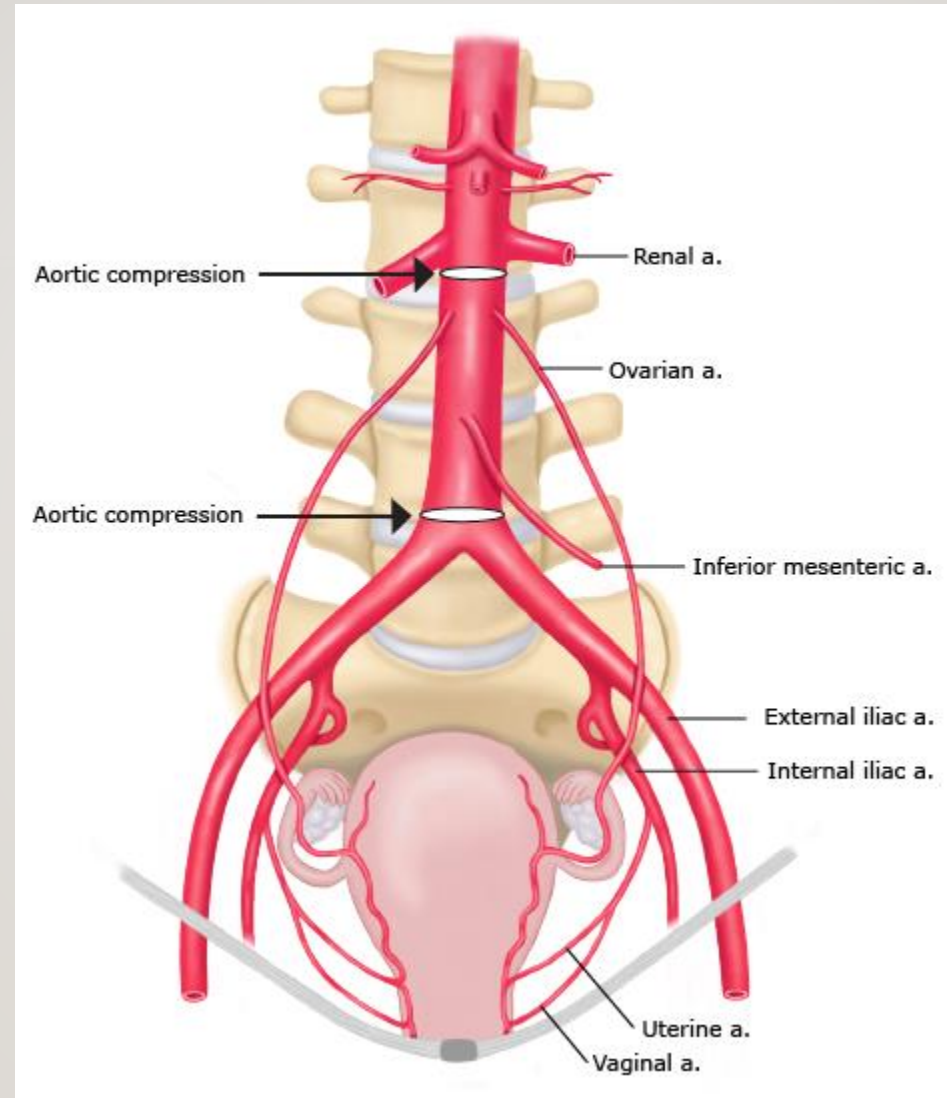
-
- The following measures, in addition to fluid administration and transfusion of blood products, help to support the patient hemodynamically in preparation for and during surgical evaluation and treatment, and can be life-saving

PATIENTS AT IMMINENT RISK OF EXSANGUINATION



MANUAL AORTIC COMPRESSION





If there is an imminent threat of exsanguination (ie, within a few minutes), the surgeon should apply direct pressure to the aorta to compress it against the vertebrae a few centimeters superior to the sacral promontory ; the bifurcation into the common iliac arteries is just distal to this point. Compression can be applied using a closed fist or the heel of the hand. Alternatively, the aorta can be compressed just below the renal arteries, which will minimize collateral flow to the uterus from the ovarian and inferior mesenteric arteries. Compression at either site will slow the volume of bleeding and will afford a better opportunity for finding and controlling the source of hemorrhage. Compression just above the bifurcation may be easier to accomplish but is less effective than below the renal arteries because of the extensive collateral blood supply to the uterus.



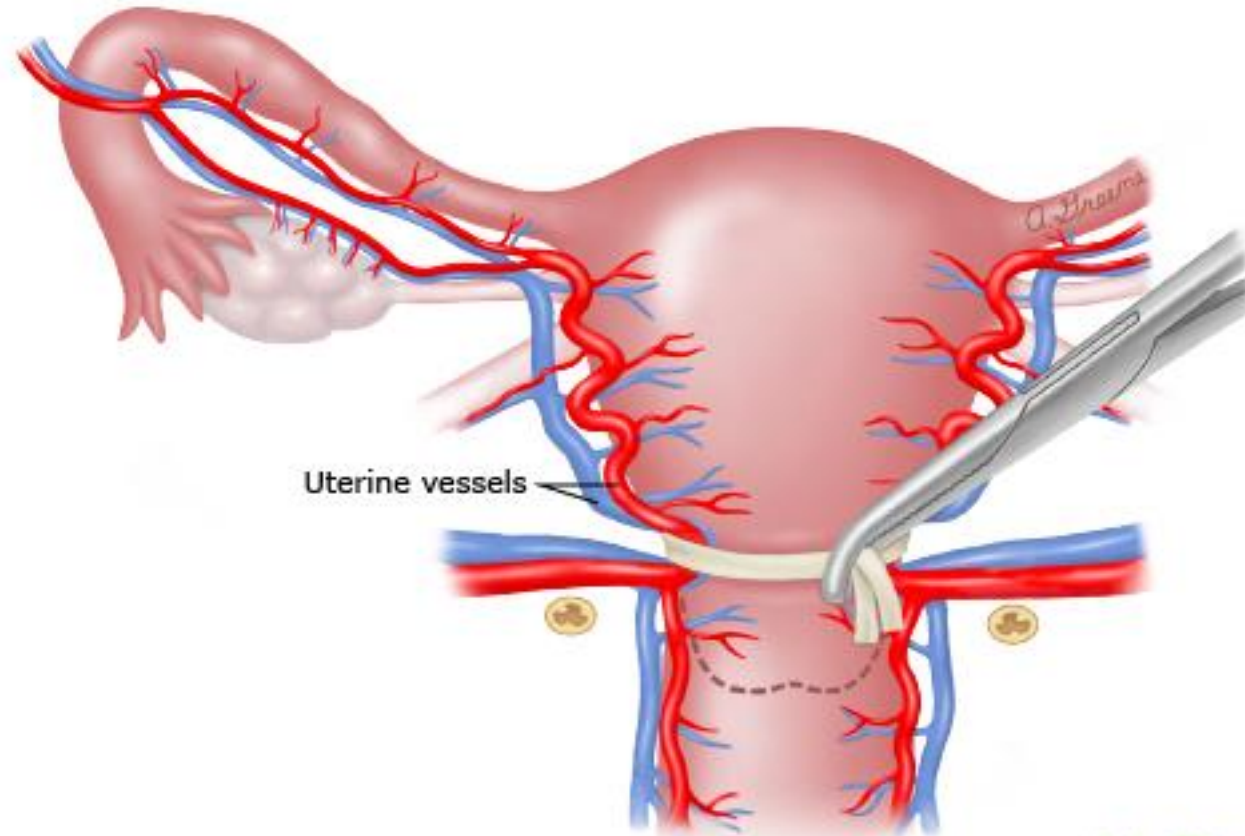
BALLOON OCCLUSION OF THE AORTA

- For patients in danger of imminent exsanguination, an aortic catheter positioned below the renal arteries may temporize bleeding to allow for ongoing resuscitation and can be placed either using a percutaneous femoral approach or by introducing the balloon catheter directly into the aorta.

UTERINE TOURNIQUET

- Tourniquets have been used to control bleeding at myomectomy, for other types of uterine hemorrhage, and may be useful as a temporizing measure in PPH. A Penrose drain or urinary catheter is placed as low as possible around the lower uterine segment without incorporating the urinary bladder, and then the two ends are pulled in opposite directions and as tightly as possible around the corpus to mechanically occlude the vascular supply. A second or third tourniquet can also be applied as needed. The tourniquet(s) can be held in place with a clamp . This procedure markedly reduces blood loss and allows time for the anesthesia team members to catch up with transfusion requirements. When the patient is hemodynamically stable, the tourniquet(s) is removed and the surgical procedure is completed

Placement of uterine tourniquet for managing uterine hemorrhage



UpToDate®

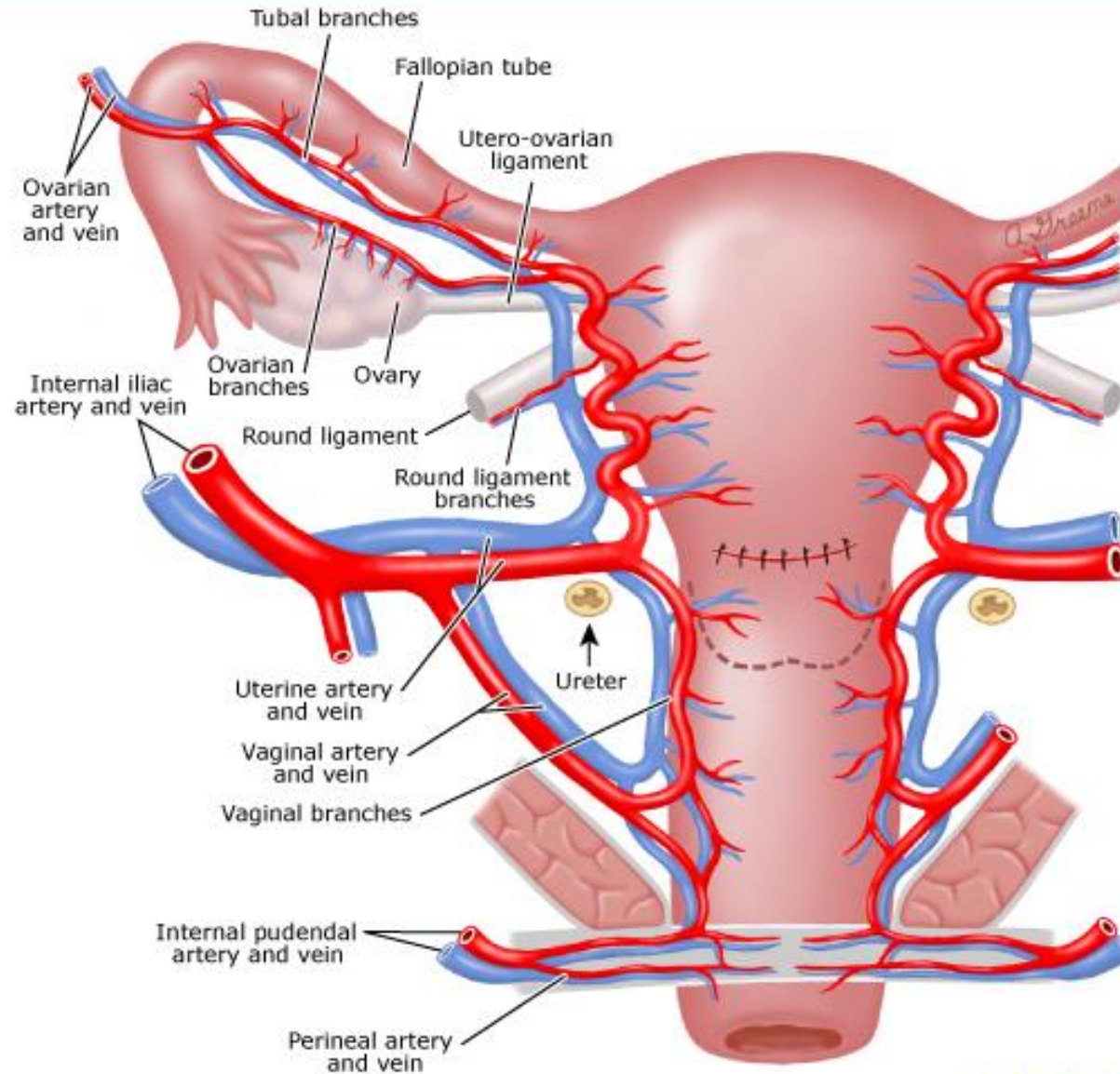
INTRAUTERINE BALLOON TAMPONADE

- Commercially available and improvised devices have been used successfully to tamponade bleeding from the uterine cavity after vaginal or cesarean birth. For each device, the intrauterine balloon is filled until bleeding is controlled; continued excessive bleeding indicates that tamponade is not effective. Intrauterine balloon tamponade has been used alone and in combination with uterine compression sutures ("uterine sandwich"). If a balloon catheter is in utero before placing a uterine compression stitch, it should be removed or deflated while the compression stitch is carefully placed. The compression suture does not prevent subsequent inflation of the balloon.

LIGATION OF UTERINE AND UTERO-OVARIAN ARTERIES

- Ligation of the uterine and utero-ovarian arteries can decrease uterine bleeding by reducing perfusion pressure in the myometrium. It will not completely control bleeding from uterine atony or placenta accreta spectrum but may decrease blood loss while other interventions are being attempted. It does not harm the uterus and does not appear to impact reproductive function

Uterine vessels, ureter, uterus after cesarean delivery

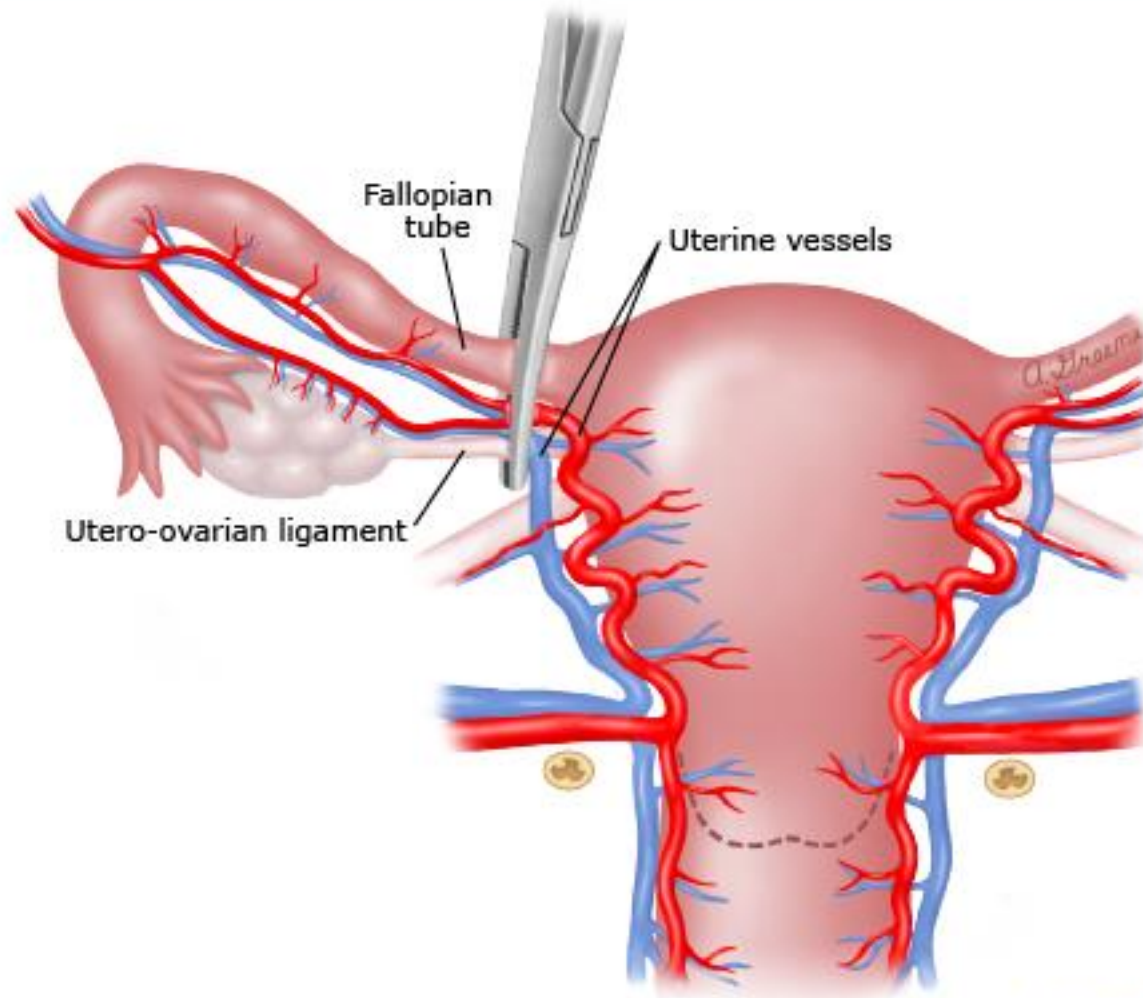


UpToDate®

CLAMP ACROSS UTERO-OVARIAN LIGAMENTS

- Placing a large clamp across the utero-ovarian ligaments bilaterally is a rapid and simple means of occluding uterine blood flow through ovarian artery collaterals; however, it also effectively ligates the fallopian tubes , precluding future conception without in vitro fertilization. It will not completely control bleeding from uterine atony or placenta accreta spectrum but may decrease blood loss while other interventions are being attempted.

Clamp across the utero-ovarian vessels and ligament to reduce uterine bleeding

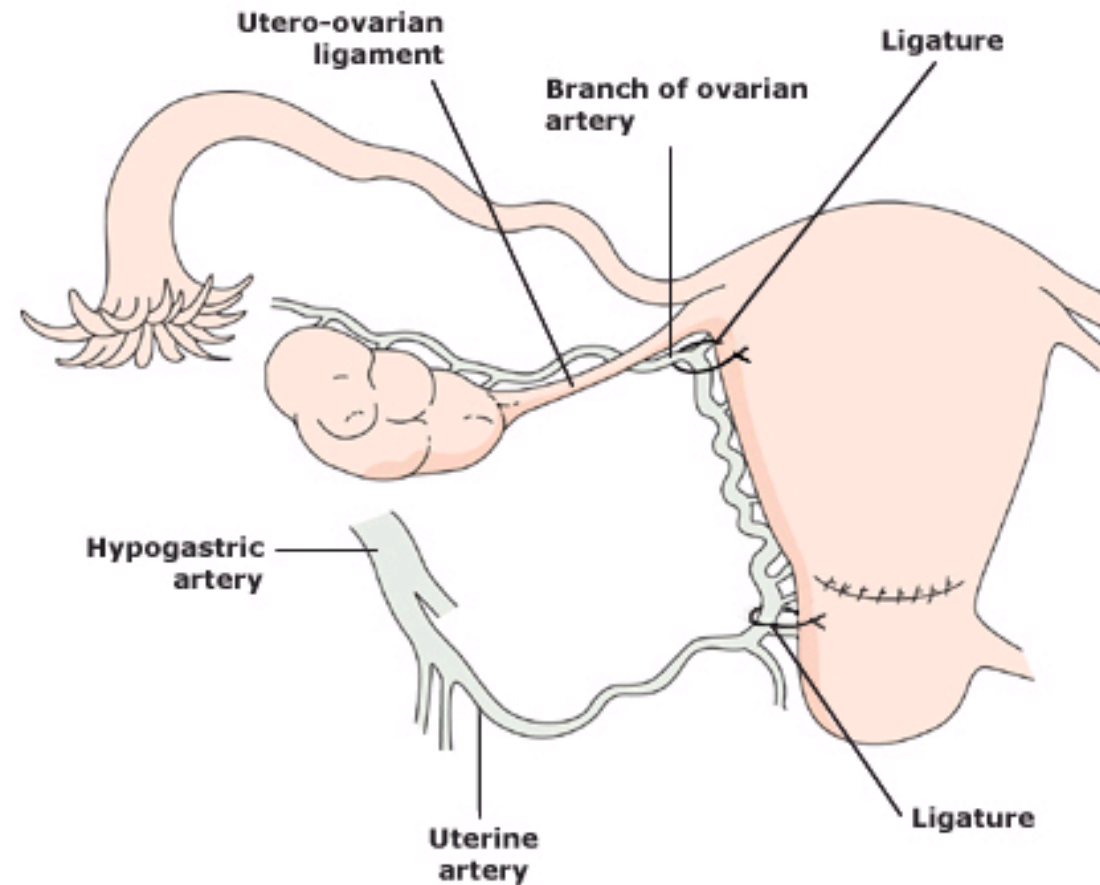


UpToDate®

LACERATION OF THE UTERINE ARTERY OR UTERO-OVARIAN ARTERY BRANCHES

- Bilateral ligation of the uterine vessels (O'Leary stitch) is the preferred approach for controlling PPH from laceration of the uterine artery or branches of the utero-ovarian artery . It is preferable to internal iliac artery ligation because the uterine arteries are more readily accessible, the procedure is technically easier, and there is less risk to major adjacent vessels and the ureters.

Uterine artery ligation



Sutures are placed to ligate the ascending uterine artery and the anastomotic branch of the ovarian artery. The procedure should be performed on each side.

-
- Bilateral ligation of the arteries and veins (uterine and utero-ovarian) is often successful in controlling hemorrhage but in some cases may not completely control it, and other methods may be needed. Bilateral ligation does not appear to affect future reproductive function . Uterine necrosis and placental insufficiency in a subsequent pregnancy have not been described as complications . However, there is a single case report of ovarian failure and development of intrauterine synechiae after postpartum ligation of the uterine, utero-ovarian, and ovarian arteries for PPH related to atony

PELVIC PACKING

- Pelvic packing to create tamponade pressure exceeding arterial pressure can control bleeding from small pelvic arteries. It can be useful as a temporizing measure in the management of broad ligament or retroperitoneal hematomas, lacerations that are difficult to repair because of their location or friable tissue, bleeding related to coagulopathy while coagulation factors are being replaced, and posthysterectomy bleeding.

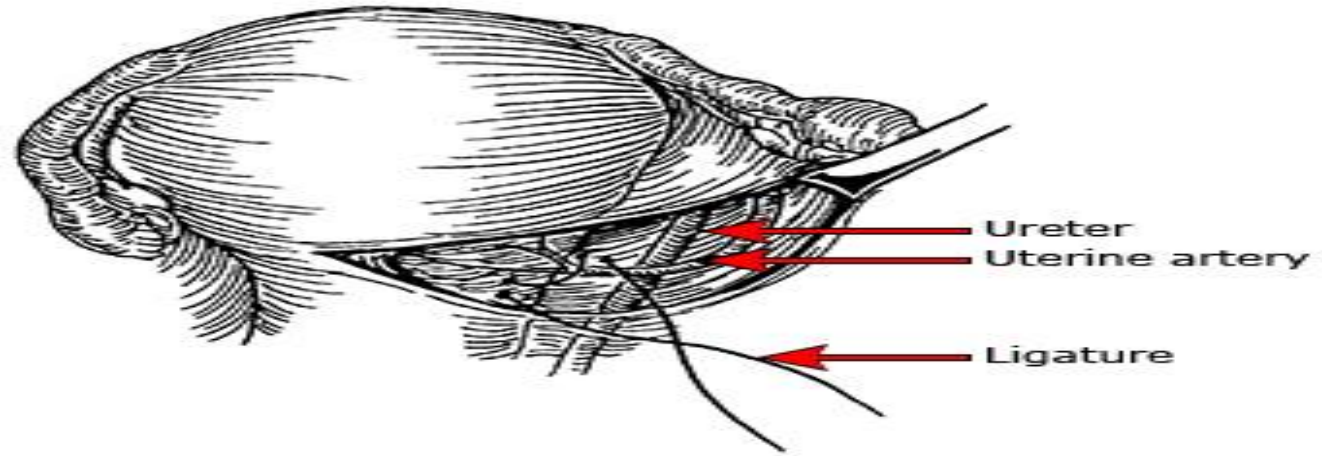
ROLE OF INTERNAL ILIAC (HYPOGASTRIC) ARTERY LIGATION

- This technique is challenging even for an experienced pelvic surgeon, especially when there is a large uterus, limited exposure through a transverse lower abdominal incision, ongoing pelvic hemorrhage, or a patient with obesity. Successful and safe bilateral internal iliac artery ligation becomes even more difficult when attempted by a surgeon who rarely operates deep in the pelvic retroperitoneal space . For these reasons, uterine compression sutures, uterine artery ligation, and arterial embolization have largely replaced this procedure.

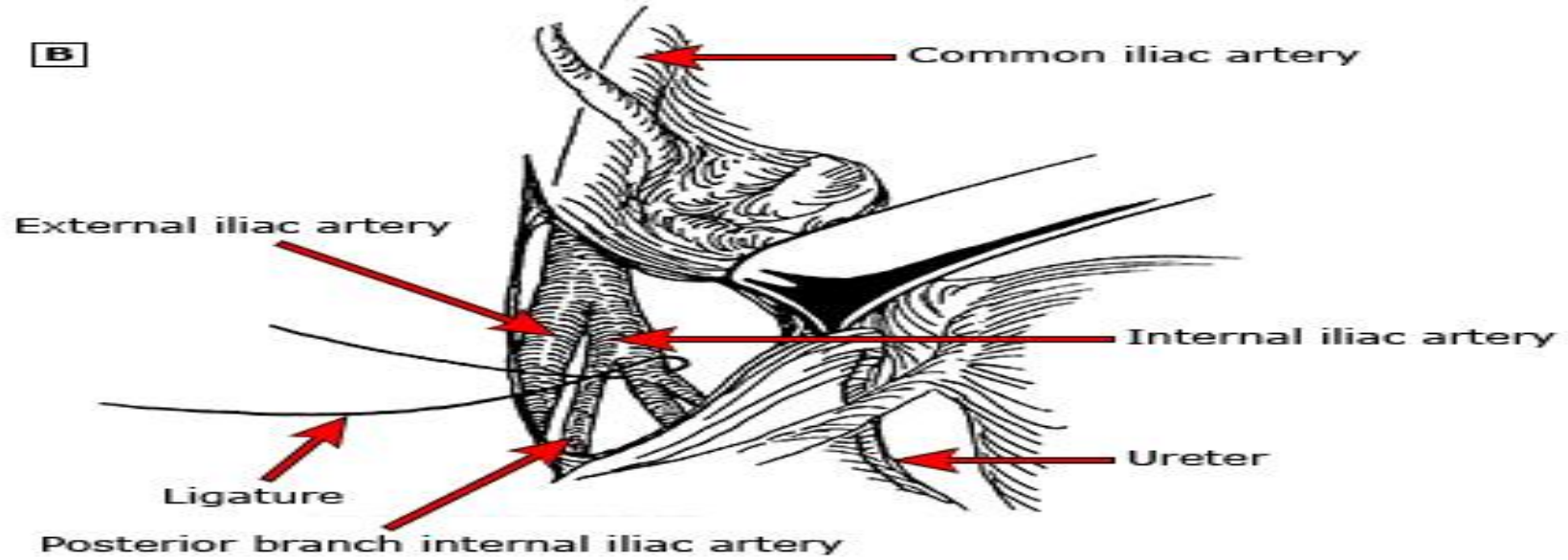
THE TECHNIQUE FOR IAL IS PERFORMED BILATERALLY AS FOLLOWS

- ●Open the anterior leaf of the broad ligament (with a Metzenbaum scissors or electrosurgery) and lyse the areolar tissue of the retroperitoneum.
- ●The external iliac artery is readily identified at the medial margin of the psoas muscle, and is followed to the common iliac artery bifurcation. The internal iliac artery is approximately 4 cm in length before it divides into anterior and posterior branches.
- ●Ideally, the dissection should be carried caudally to the anterior and posterior trunks of the internal iliac artery so that the anterior trunk can be selectively ligated. In practice, this is so difficult that the entire internal iliac artery usually is ligated at its origin.
- ●Dissect away the nodal tissue overlying the internal iliac artery by spreading the tissue with a right angle or tonsil clamp or the tips of Metzenbaum scissors. Continue the dissection anterior and lateral to the internal iliac artery. Proceed in the same plane around the circumference of the artery to separate it from the internal iliac vein, which is slightly medial and posterior to the artery. Pass a number 1 silk or nonabsorbable synthetic suture (eg, polypropylene) around the artery from lateral to medial and tie securely. An alternative technique is to use surgical clips to ligate the internal iliac artery, which eliminates the need for circumferential dissection and thus may reduce the risk of iliac vein injury

A



B



ROLE OF INTRAOPERATIVE CELL SALVAGE

- Arranging for cell salvage in patients at high risk for PPH appears to be economically reasonable, while routine use of cell salvage for all cesarean births probably is not . Intraoperative cell salvage may be arranged before laparotomy or requested during laparotomy. The American College of Obstetricians and Gynecologists has acknowledged the safety and efficacy of intraoperative cell salvage in patients with PPH

ETIOLOGY-BASED MANAGEMENT



MYOMETRIAL LACERATIONS

- Serious hemorrhage from the uterine incision is generally caused by lateral extension of the incision. Bleeding from a hysterotomy incision can generally be controlled by suture ligation. The angles of a transverse incision should be clearly visualized to ensure that they, and any retracted vessels, are completely ligated. This generally requires exteriorization of the uterus with gentle traction and adequate visualization of the lateral areas of the uterus above and below the edges of the incision.

-
- An enlarging hematoma (or swelling beneath the surface of the broad ligament) beyond the end of the incision or laceration suggests a retracted blood vessel with ongoing bleeding. Given the proximity of the ureter to the vaginal angle and bladder reflection, placement of hemostatic sutures laterally to control bleeding from an extension of a hysterotomy laceration or retracted vessel should be carried out with extreme caution. In this circumstance, the ureter should be identified prior to blind placement of additional sutures to "catch" the retracted vessel. This may require placement of ureteric stents to aid palpation of the ureters. In other cases, the ureter(s) may be easily seen and identified. Once the ureters can be seen or felt, the broad ligament may need to be opened to isolate the bleeder, or alternatively, sutures can be placed without opening the retroperitoneum while retracting the ureter safely aside. Once the hemorrhage has been controlled, the integrity of the ureter(s) should be ensured.

LACERATION OF THE UTERINE ARTERY OR UTERO-OVARIAN ARTERY BRANCHES

- Bilateral ligation of the uterine vessels (O'Leary stitch) is the preferred approach for controlling PPH from laceration of the uterine artery or branches of the utero-ovarian artery . It is preferable to internal iliac artery ligation because the uterine arteries are more readily accessible, the procedure is technically easier, and there is less risk to major adjacent vessels and the ureters

-
- After identification of the ureter, a large curved needle with a #0 polyglycolic acid suture is passed through the lateral aspect of the lower uterine segment as close to the cervix as possible and then back through the broad ligament just lateral to the uterine vessels. If this does not control bleeding, the vessels of the utero-ovarian arcade are similarly ligated just distal to the cornua by passing a suture ligature through the myometrium just medial to the vessels, then back through the broad ligament just lateral to the vessels, and then tying to compress the vessels

ATONY

- The nonsurgical interventions for reduction and control of bleeding due to atony are applied in rapid sequence until bleeding is controlled, which may be the result of the cumulative combined effect of multiple interventions. All patients with PPH related to atony receive uterine massage/manual compression and administration of uterotonic drugs and tranexamic acid.

-
- If these measures do not control bleeding, and the patient is hemodynamically stable, we rapidly move on to placement of uterine compression sutures, which are an effective method for reducing uterine blood loss related to atony.
 - If the patient is hemodynamically unstable, temporizing measures such as placement of a uterine tourniquet, insertion of an intrauterine balloon for tamponade, and/or ligation of the uterine and utero-ovarian arteries can reduce ongoing heavy blood loss before placing compression sutures, and may obviate the need for them

UTERINE COMPRESSION SUTURES

- The B-Lynch suture is the most common technique for uterine compression; several variations of this technique have been described and no technique has been proven significantly more effective than another . Generally, longitudinal sutures are easier to place and safer than transverse sutures, but this may not always be the case.

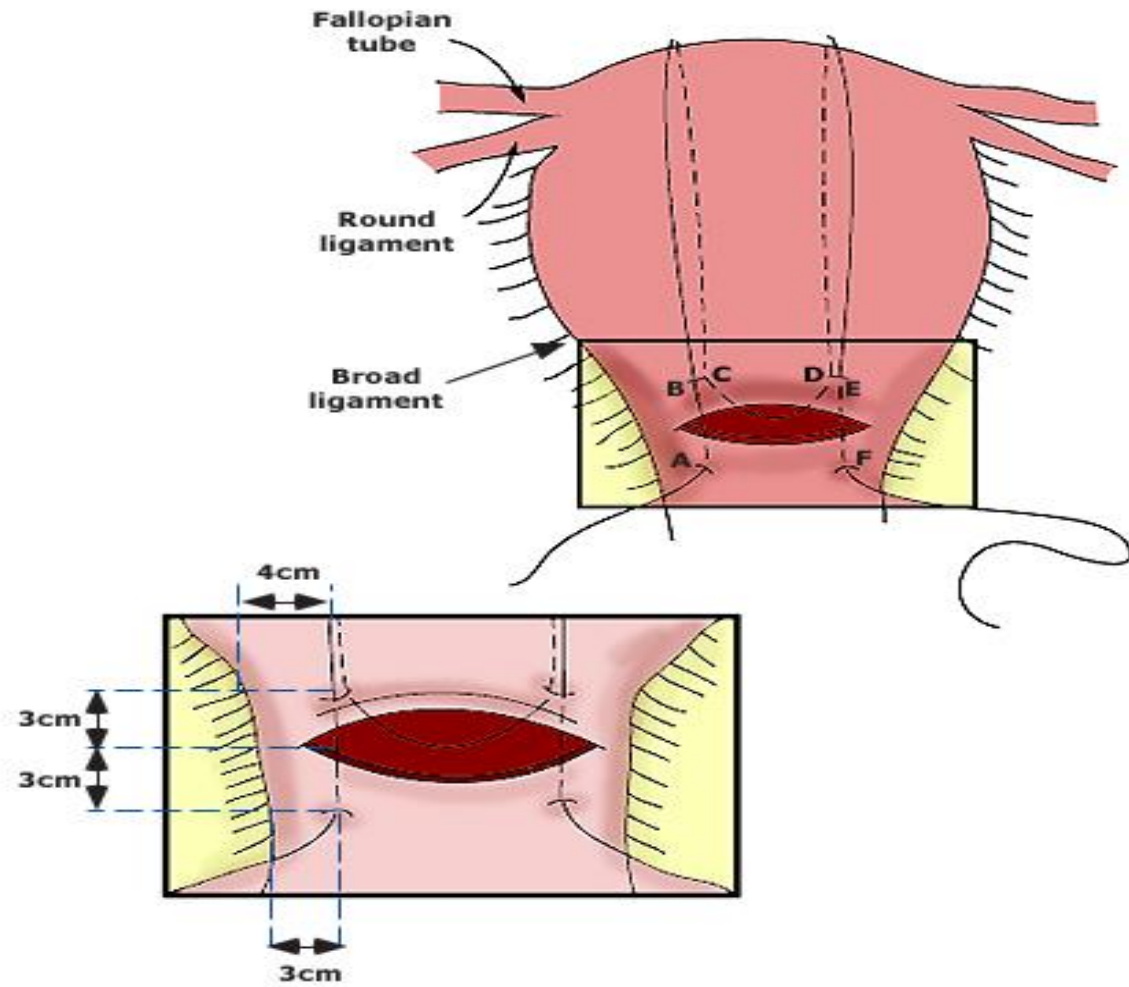
B-LYNCH SUTURE

- The B-Lynch suture (named for Christopher Balogun-Lynch) envelops and compresses the uterus, similar to the result achieved with manual uterine compression . In case reports and small series, it has been highly successful in controlling uterine bleeding from atony when other methods have failed . The technique is relatively simple to learn, appears safe, preserves future reproductive potential, and does increase the risk of placentation-related adverse outcomes in a subsequent pregnancy . It should only be used in cases of uterine atony; it will not control hemorrhage from placenta accreta spectrum. It will not prevent PPH in future pregnancies

-
- A large Mayo needle with #1 or #2 chromic catgut (or any absorbable suture if catgut is unavailable) is used to enter and exit the uterine cavity laterally in the lower uterine segment . A large suture is used to prevent breaking, and a rapid absorption is important to prevent a herniation of bowel through a suture loop after the uterus has involuted.

-
- The suture is looped over the fundus and re-enters the lower uterine cavity through the posterior wall. The suture then crosses to the other side of the lower uterine segment, exits through the posterior wall, and is looped back over the fundus to enter the anterior lateral lower uterine segment opposite and parallel to the initial bites. The free ends are pulled tightly and tied down securely to compress the uterus, assisted by bimanual compression.

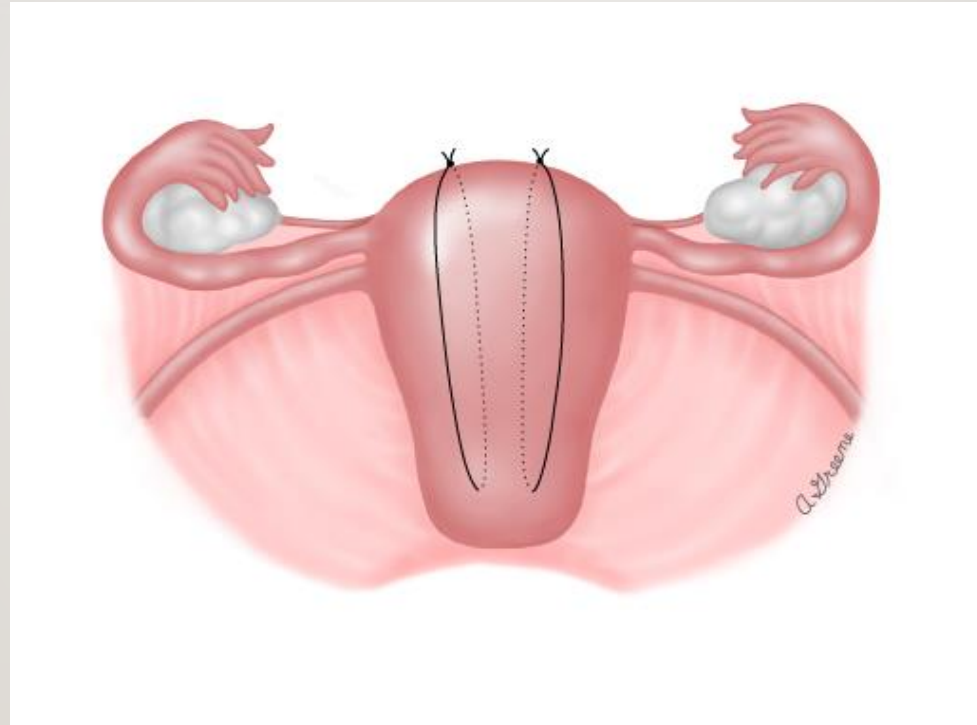
-
- The technique has been used alone and in combination with balloon tamponade. This combination has been called the "uterine sandwich."



HAYMAN

- described placement of two to four vertical compression sutures from the anterior to posterior uterine wall without hysterotomy thus, this is a good choice for surgical treatment of atony after a vaginal birth
- A transverse cervicoisthmic suture can also be placed if needed to control bleeding from the lower uterine segment.

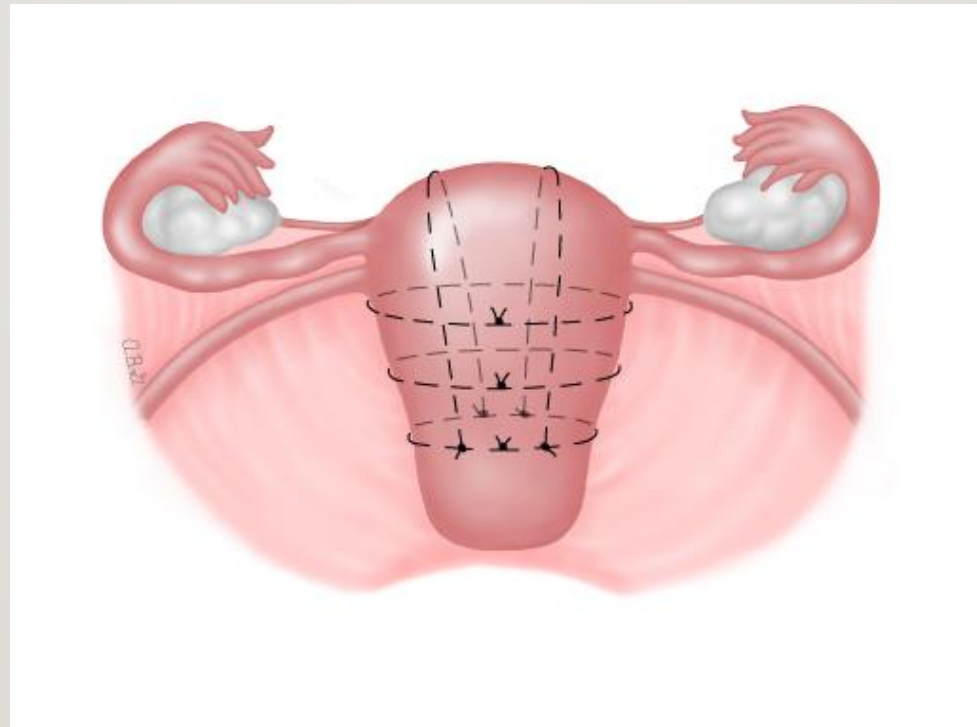
HAYMAN



PEREIRA

- described a technique in which a series of transverse and longitudinal sutures of a delayed absorbable multifilament suture are placed around the uterus via a series of bites into the subserosal myometrium, without entering the uterine cavity. Two or three rows of these sutures are placed in each direction to completely envelope and compress the uterus. The longitudinal sutures begin and end tied to the transverse suture nearest the cervix. When the transverse sutures are brought through the broad ligament, care should be taken to avoid damaging blood vessels, ureters, and fallopian tubes. The myometrium should be manually compressed prior to tying down the sutures to facilitate maximal compression.

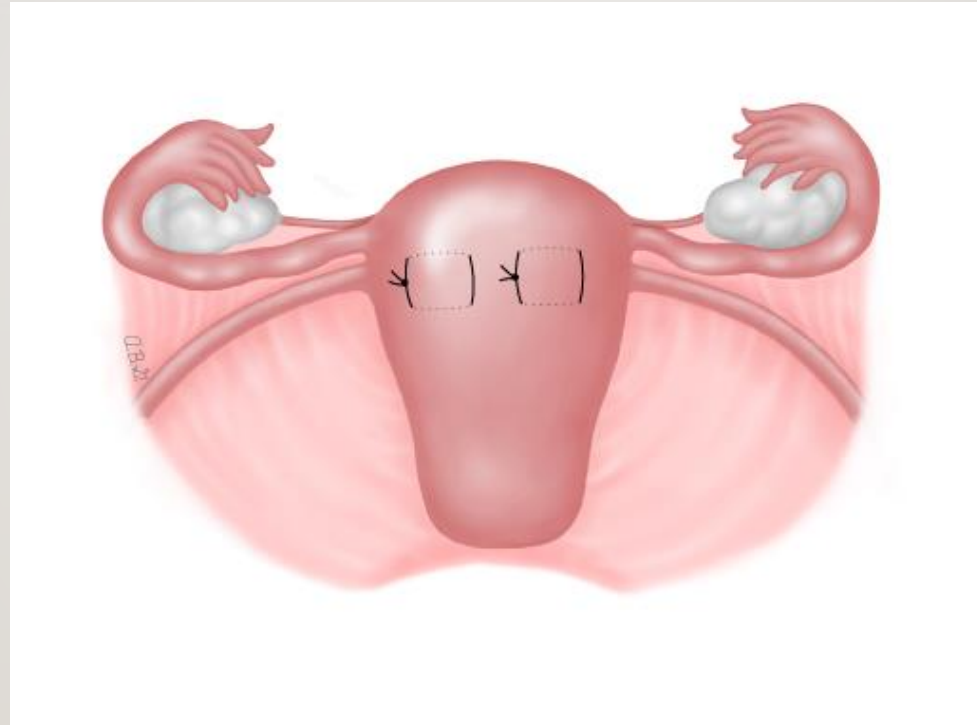
PEREIRA



CHO

- described a technique using multiple squares/rectangles

CHO



RETROPERITONEAL BLEEDING

- Identification of an isolated bleeding point in the retroperitoneum is often impossible. It is rarely advisable to open the retroperitoneum or attempt dissection of any nonexpanding hematoma or an expanding retroperitoneal hematoma in a coagulopathic, hemodynamically unstable patient. The temporizing procedures described above can be used to stabilize the patient before beginning retroperitoneal surgery.

-
- Topical hemostatic agents can be used to control mild diffuse bleeding from peritoneal surfaces

-
- If a discrete retroperitoneal vessel is responsible for hemorrhage, it is clamped and ligated with appropriate suture material. Bleeding adjacent to the uterus without clear bleeding points can be managed by ligation of uterine vessels.

-
- If ineffective, ligation of the ipsilateral internal iliac artery usually stops the bleeding and avoids the delay associated with searching for the discrete source of bleeding. If bleeding does not respond to ipsilateral internal iliac artery ligation, then bilateral internal iliac artery ligation and/or pelvic packing may be necessary. If time allows, when retroperitoneal bleeding is present and efforts at controlling retroperitoneal bleeding are necessary, ureteral stents may allow palpation of the ureters and placement of hemostatic sutures with more confidence.

-
- Given the technical difficulties of safely ligating the internal iliac arteries, especially in the setting of disseminated intravascular coagulation and ongoing bleeding, this should only be attempted by surgeons with experience in the procedure and only when adequate blood products and facilities are available.

-
- For surgeons without the necessary experience, pressure over the bleeding point or area, resuscitation and reversal of any coagulopathy, and calling for help from an experienced surgeon are key temporizing measures. If the hospital has the capability for performing arterial embolization in the operating room, this may be an option. Removal of a hemodynamically unstable patient from an operating room to transport to an interventional radiology suite is not advised.

ROLE OF HYSTERECTOMY

- Hysterectomy is a definitive treatment of uterine bleeding. Regardless of the etiology of postpartum hemorrhage (PPH), continued blood loss can lead to severe coagulopathy due to massive loss of coagulation factors. Severe hypovolemia, tissue hypoxia, hypothermia, electrolyte abnormalities, and acidosis can result, which further compromise the patient's status. If the patient is not already at laparotomy and has developed these additional complications, then correction of the severe physiological deficits before hysterectomy, if possible, could be life-saving

-
- In patients with placenta accreta spectrum or uterine rupture, early resort to hysterectomy may be the least morbid approach for controlling hemorrhage and may prevent deaths and morbidity caused by delays while ineffective fertility-preserving procedures are attempted. With improving prenatal diagnosis of placental attachment disorders, hysterectomy can often be anticipated and discussed with the patient before planned cesarean birth.

-
- By contrast, uterine atony can usually be controlled by uterotonic drugs alone or in combination with fertility-preserving procedures (eg, uterine compression sutures, uterine artery/utero-ovarian artery ligation, arterial embolization, intrauterine balloon tamponade), as described above. Once the patient is resuscitated and the coagulopathy is reversed, hysterectomy may no longer be required to control hemorrhage

PERSISTENT BLEEDING AFTER HYSTERECTOMY

- Patients with continued severe bleeding after hysterectomy can enter a lethal downward spiral characterized by hypothermia, coagulopathy, and metabolic acidosis . Criteria proposed for this "in extremis" state include pH <7.30, temperature <35°C, combined resuscitation and procedural time >90 minutes, nonmechanical bleeding, and transfusion requirement >10 units packed red blood cells (RBCs)

TO ABORT THE CYCLE

- the bleeding area is tightly packed, and the skin is closed to prevent heat and moisture loss (either with large sutures or with towel clamps).
Placement of a large bore drainage catheter (such as a large Jackson-Pratt drain or a chest tube) in the pelvis at the time of temporary closure will allow early recognition of the need to return to the operating room.

-
- Variations of the abdominal packing procedure have been published ("umbrella pack") . One such variation is to fill a sterile plastic bag (eg, drawstring bag used to cover radiographic film) or cloth container with gauze (wet gauze gives it more weight) and place it against the pelvic bleeders. The drawstrings are pulled through the vagina and attached to a weight, which provides traction so that the pack exerts pressure against the pelvic floor.

-
- A balloon tamponade device has also been used as a pelvic pressure pack after hysterectomy for PPH

-
- Under most circumstances, the patient should remain in the operating room with continuous monitoring, while replacement of appropriate blood products and correction of physiologic derangements ("damage control") occur . This approach halts the downward spiral and lessens the risk of abdominal compartment syndrome, which is more likely if the fascia is closed. Abdominal compartment syndrome is more difficult to define postpartum since postcesarean intra-abdominal pressure appears to be higher than in the general surgical population, especially in patients with elevated body mass index and hypertensive disorders

-
- The patient can leave the operating room after they have been stabilized, as evidenced by cessation of active bleeding, maintenance of hemodynamic stability, and satisfactory progress in the management/reversal of any coagulopathy. Depending on the degree of blood loss, the amount of resuscitation required, the risk of resumption of bleeding, and the need for ventilation, they can be transferred to a high-care post-anesthesia care unit (PACU) or an intensive care unit (ICU) for one-to-one nursing and close observation by the physician team as appropriate

-
- The need for ≥ 2 units packed RBCs per hour for three hours is a sign of significant ongoing bleeding and need to return to the operating room or arterial embolization by an interventional vascular specialist. In one study, bleeding did not stop in 20 of 53 patients despite abdominal packing; six required a second surgical intervention, six underwent pelvic artery embolization, and eight had further intensive resuscitation and pharmacologic treatments .

-
- Patients who have been stabilized are returned to the operating room to undergo definitive surgical care in approximately 48 hours. Packing should not be removed until coagulation defects have been corrected. If the packing has controlled bleeding, it generally is removed at this time. If it is removed too soon (<24 hours), bleeding will resume, whereas if it is removed too late (>72 hours), pelvic infection or abscess may ensue.
 - Under general anesthesia, the wound is opened and the gauze is removed with gentle traction. The pelvis is irrigated with saline to clear loose clots and other debris, but aggressive exploration of the pelvis is not performed if no pooling of blood is noted. The wound is then reapproximated in the usual manner.

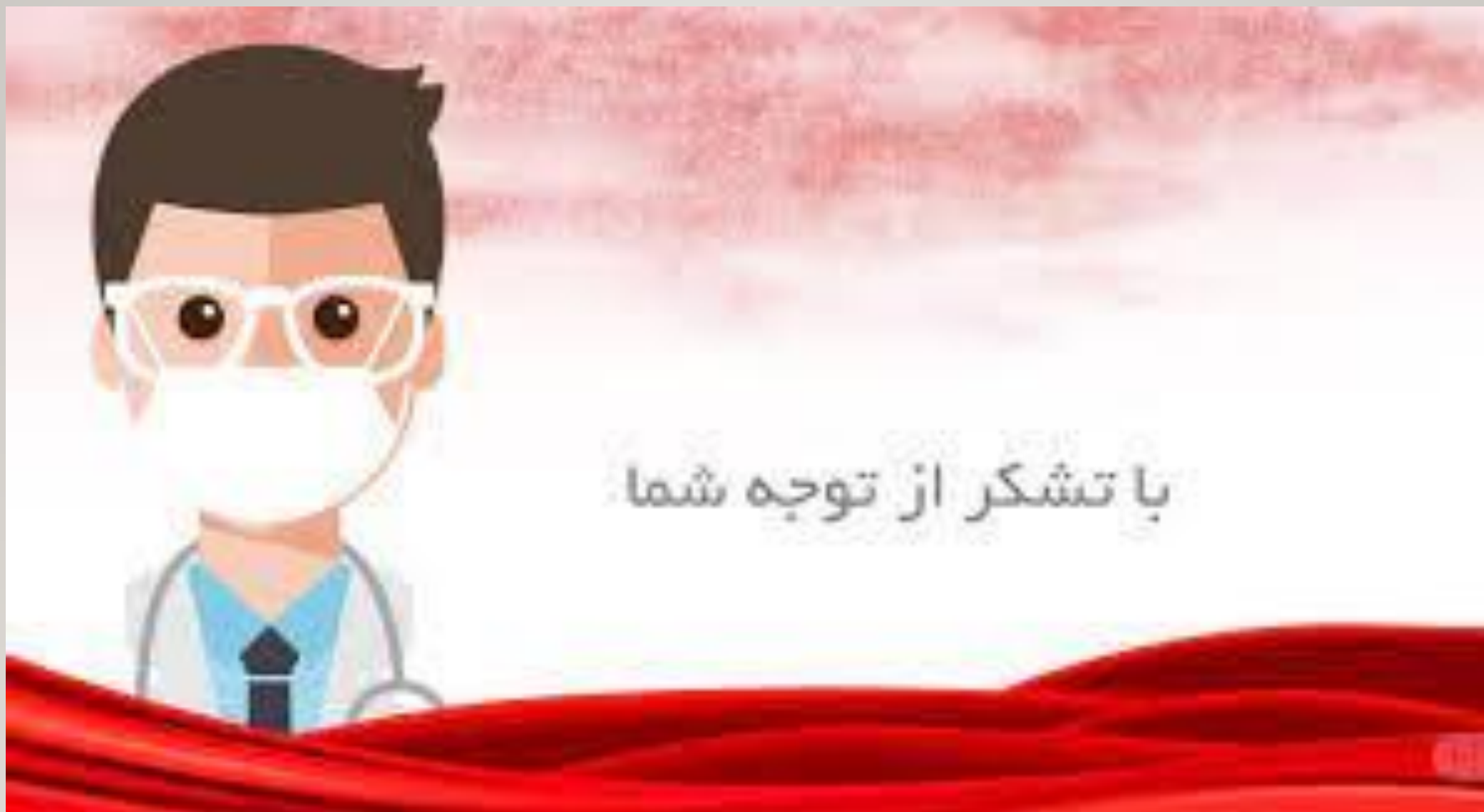ROLE OF EMBOLIZATION

- At laparotomy, when persistent non-life-threatening deep pelvic bleeding occurs after repair of lacerations or hysterectomy and cannot be controlled by surgical ligation or ablation.
- Embolization is an option if the facility has an appropriately equipped operating room (hybrid operating room, or an appropriately sensitive portable C-arm and carbon fiber table).

-
- After laparotomy, when persistent slow internal bleeding is suspected in a hemodynamically stable patient. The patient can be transferred to the interventional radiology suite for a diagnostic angiogram and embolization (if a bleeding source is seen).

-
- Hemodynamically unstable patients should be evaluated in the operating room, not the interventional radiology suite. If the facility has an appropriately equipped operating room, performing uterine or internal iliac artery embolization in an operating room with the full surgical team in attendance is an option. Laparotomy is performed if the patient deteriorates during evaluation and embolization or if the embolization fails.

-
- In patients with a placenta accreta spectrum. Embolization can reduce bleeding before and during hysterectomy or when conservative management (leaving the placenta in situ) is attempted. Direct arterial puncture of the internal iliac artery and embolization at cesarean birth has been described in 16 cases of placenta accreta spectrum . The procedure was successful in all of the cases and no complications (eg, fever, buttock pain, acute limb ischemia) occurred.



با تشکر از توجه شما