Pancreas Anatomy

B. Badakhsh Associate Prof. of medicine University of Ilam

- The pancreas is a compound exocrine and endocrine gland ,
- located in the retro peritoneum at the level of the second lumbar vertebrae.
- Exocrine pancreatic secretion is composed ;
- of enzymes, water, electrolytes, and bicarbonate,
- which are delivered to the duodenum via the pancreatic duct of Wirsung and aid with digestion.

- Endocrine secretions include ;
- insulin, glucagon, and somatostatin from the islets of Langerhans, A cells, and D cells, respectively.
- Removal of up to 90 percent of the mass of the pancreas can be performed without resulting in diabetes.

- The pancreas is divided into five parts including the head, uncinate process, neck, body, and tail.

- The head of the pancreas lies to the right of the superior mesenteric artery.
- The uncinate process is a variable posterolateral extension of the head that passes behind the retropancreatic vessels and anterior to the inferior venacava and aorta.

- The neck is defined as the portion of the gland overlying the superior mesenteric vessels.
- The body and tail lie to the left of the mesenteric vessels;
- there is no meaningful anatomic division between the body and tail.

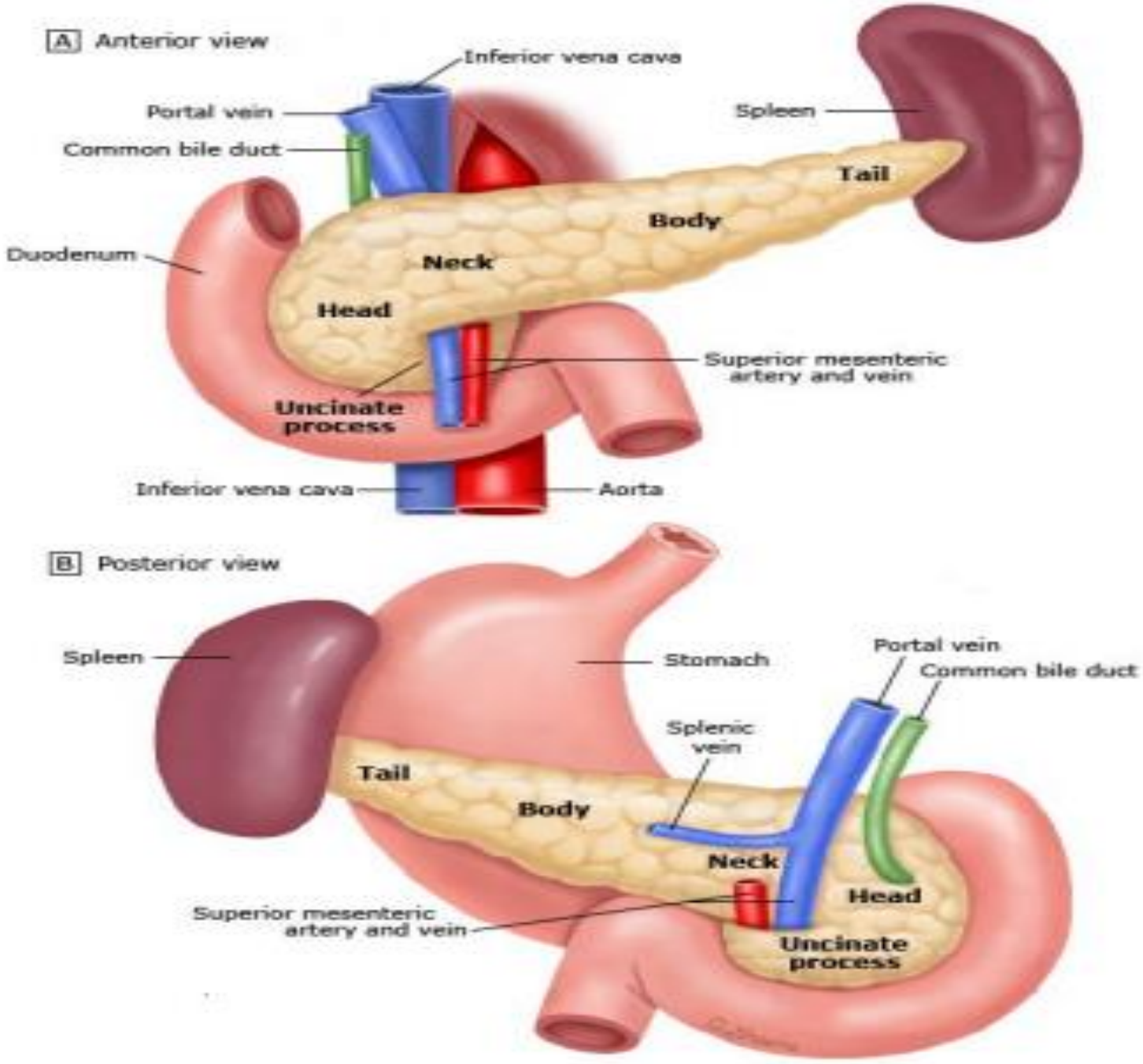
A Anterior view
Inferior vena cava
Portal vein
Common bile duct
Spleen
Tail
Body
Duodenum
Neck
Head
Superior mesenteric artery and vein
Uncinate process
Inferior vena cava
Aorta
B Posterior view
Spleen
Stomach
Portal vein
Common bile duct
Splenic vein
Tail
Body
Neck
Head
Superior mesenteric artery and vein
Uncinate process

- **Ductal anatomy**
- The pancreatic duct, located at the posterior (dorsal) aspect of the gland,
- joins the common bile duct to drain into the duodenum via the major papilla (ampulla of Vater)

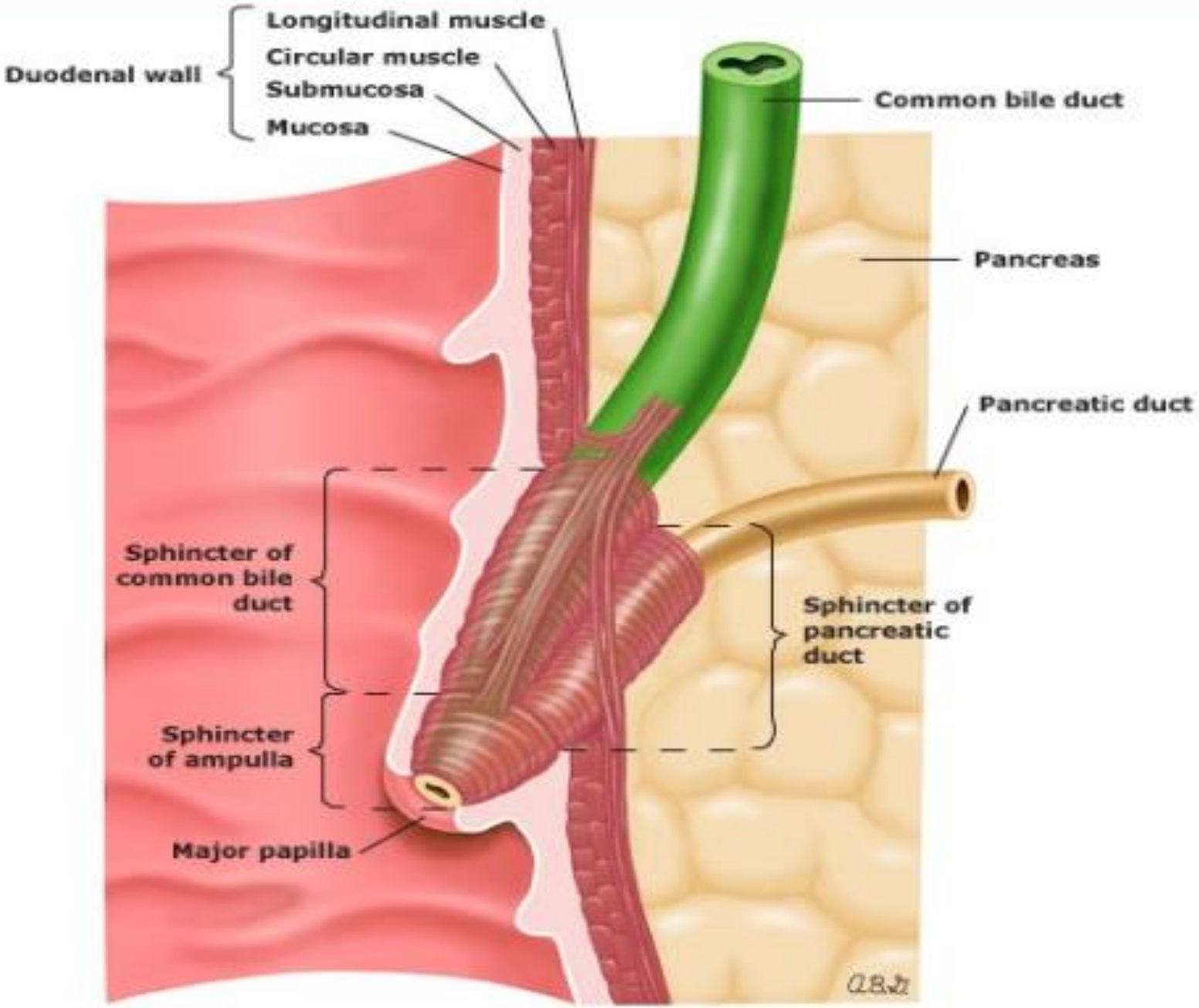
Duodenal wall
Longitudinal muscle
Circular muscle
Submucosa
Mucosa
Common bile duct
Pancreas
Pancreatic duct
Sphincter of common bile duct
Sphincter of ampulla
Sphincter of pancreatic duct
Major papilla

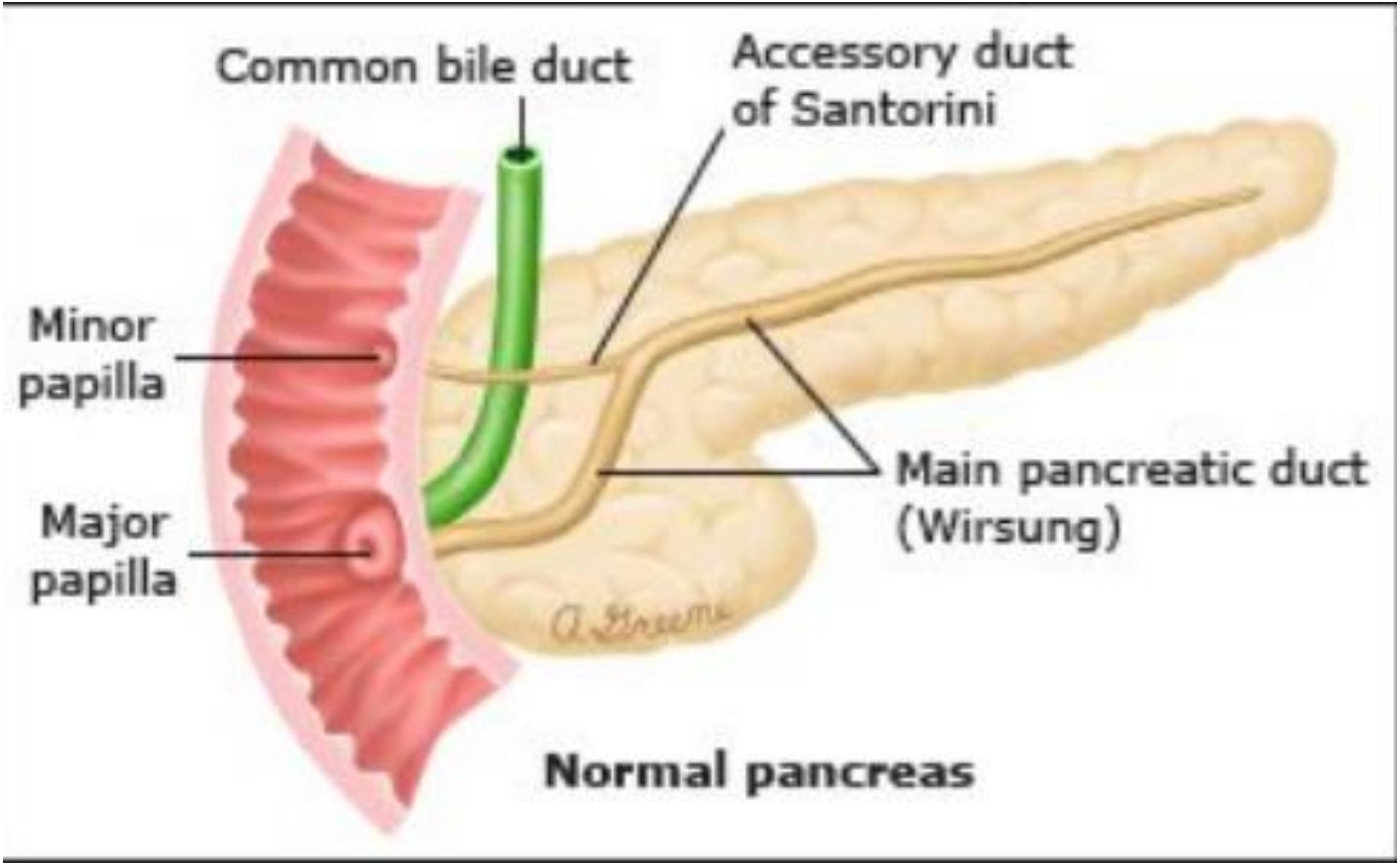
Common bile duct
Accessory duct of Santorini
Minor papilla
Major papilla
Main pancreatic duct (Wirsung)
Normal pancreas

- The anatomy of these ducts can vary.
- In 85 percent of individuals, the pancreatic duct and the common bile duct enter the duodenum through a common channel.

- In 5 percent of patients, both ducts enter the duodenum through the same ampulla but via separate channels.
- In the remaining 10 percent of patients, each duct enters the duodenum through a separate ampulla.

- The papilla of Vater, also known as the ampulla,
- is a small nipple-like structure located in the duodenum (first part of the intestine).

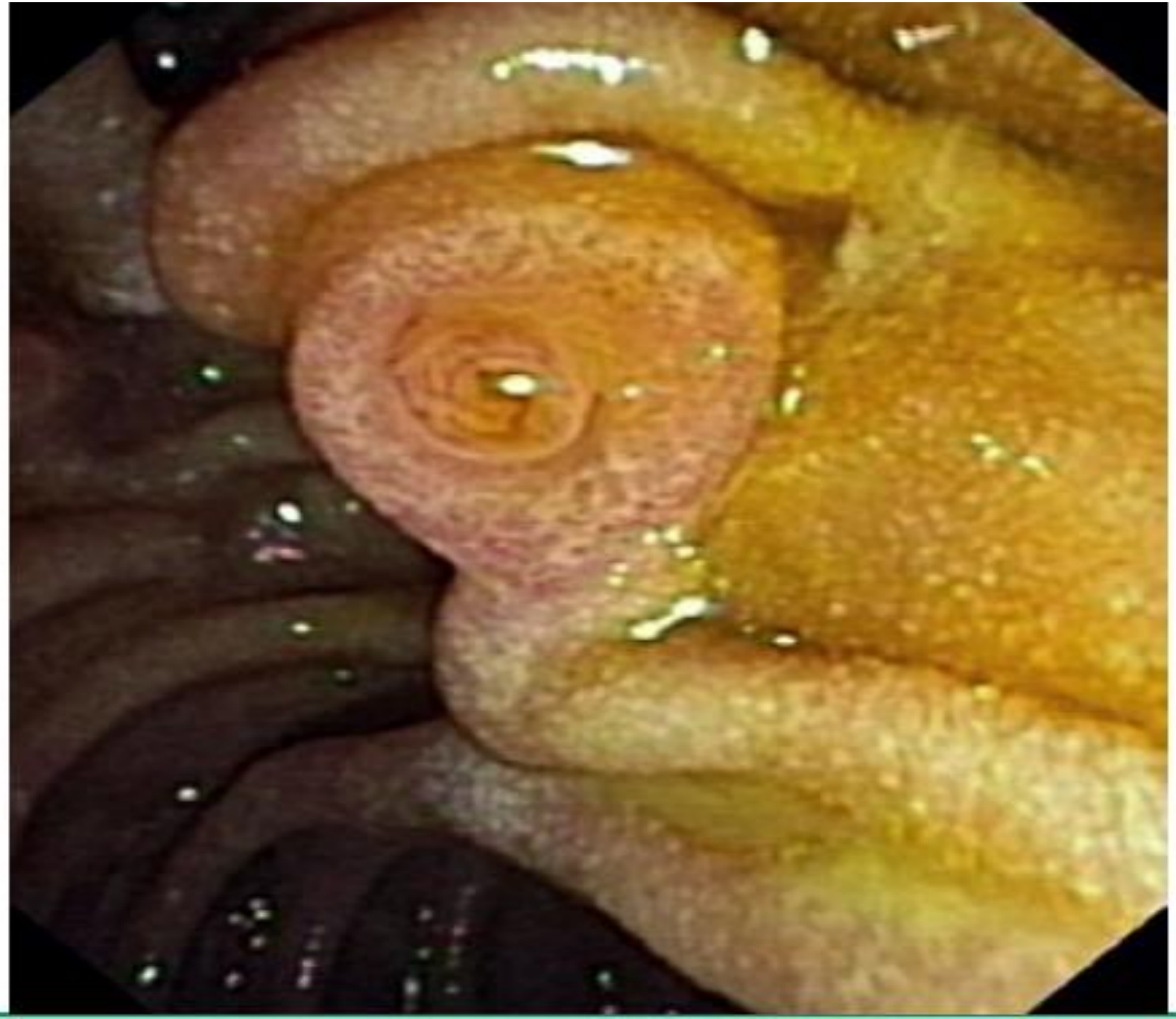

- The entry of the common bile duct into the pancreatic tissue posteriorly can also vary;

- Variations of the retropancreatic segment of the common bile duct;
  (A) The duct is partially covered by pancreatic tissue.
- (B) The duct is completely covered by pancreas.
- (C) The duct runs freely behind the pancreas.

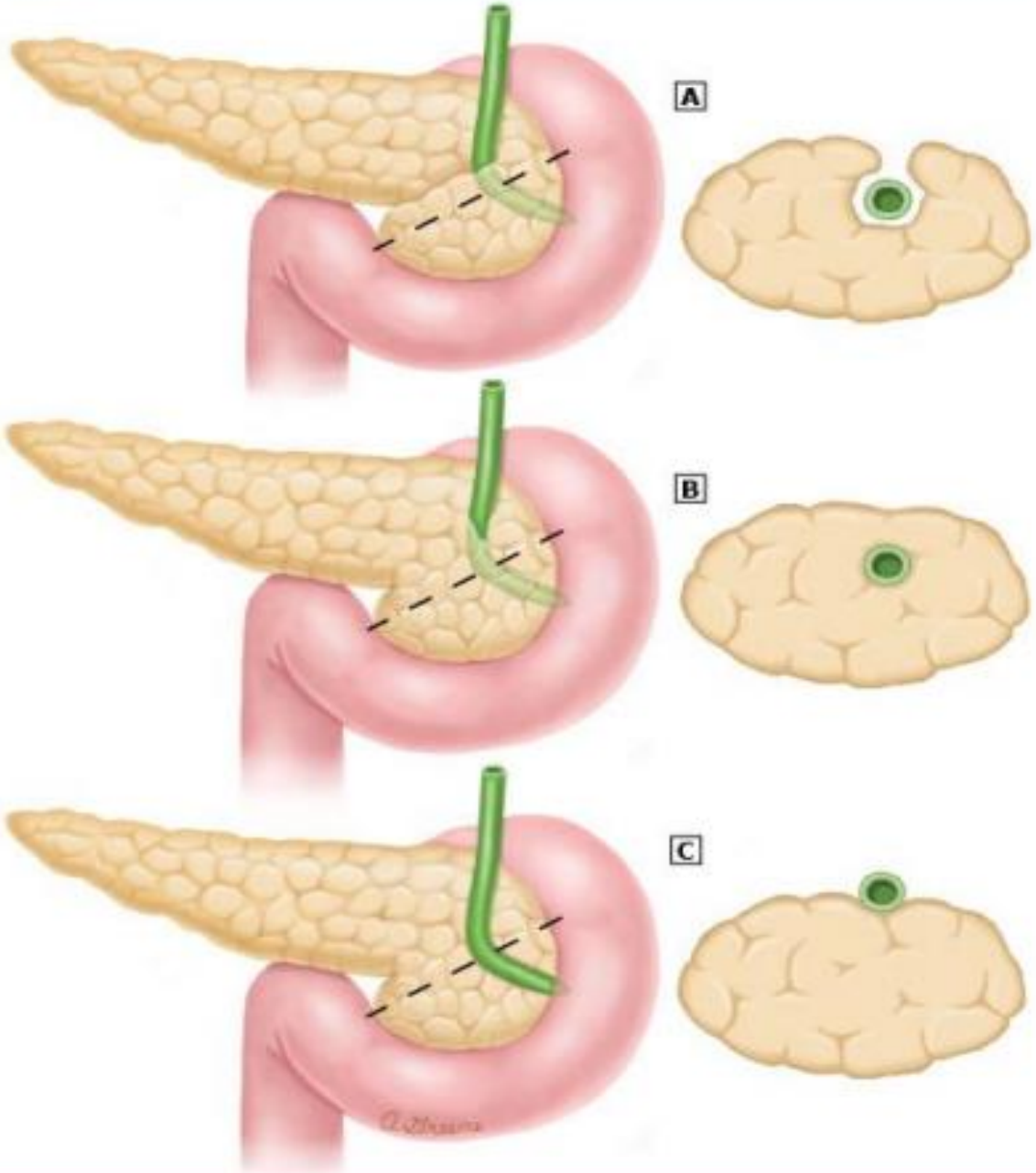
A
B
C

- **Neurovascular supply;**
- The arterial supply to the duodenum and pancreas is derived from the celiac artery ;
- providing the superior pancreaticoduodenal arteries (anterior and posterior branches),
- and the superior mesenteric artery;
- providing the inferior pancreaticoduodenal arteries (anterior and posterior branches) .

- The splenic artery supplies primarily the body and tail of the pancreas.

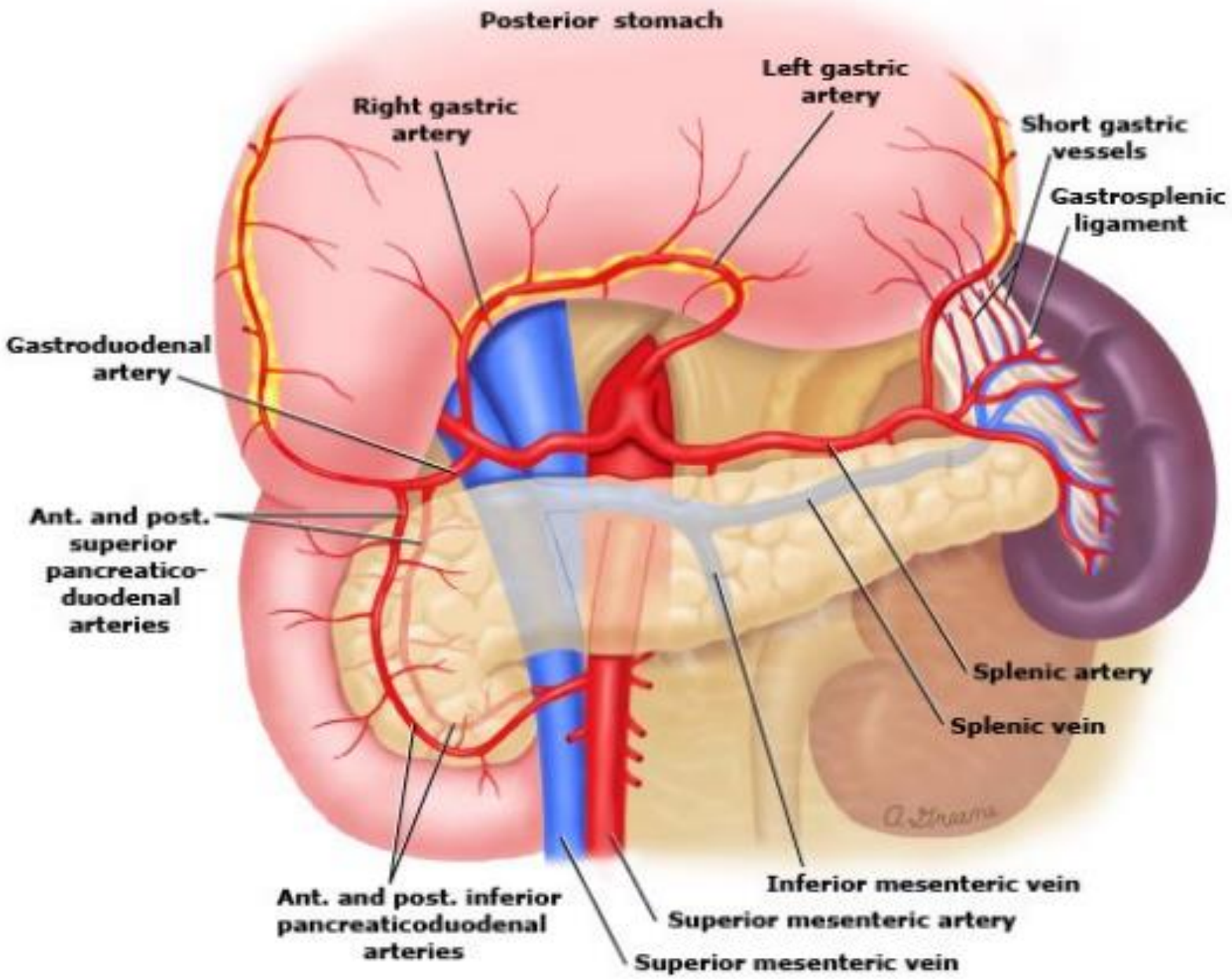
Posterior stomach
Left gastric artery
Right gastric artery
Short gastric vessels
Gastrosplenic ligament
Gastroduodenal artery
Ant. and post. superior pancreatico-duodenal arteries
Splenic artery
Splenic vein
Inferior mesenteric vein
Ant. and post. inferior pancreaticoduodenal arteries
Superior mesenteric artery
Superior mesenteric vein

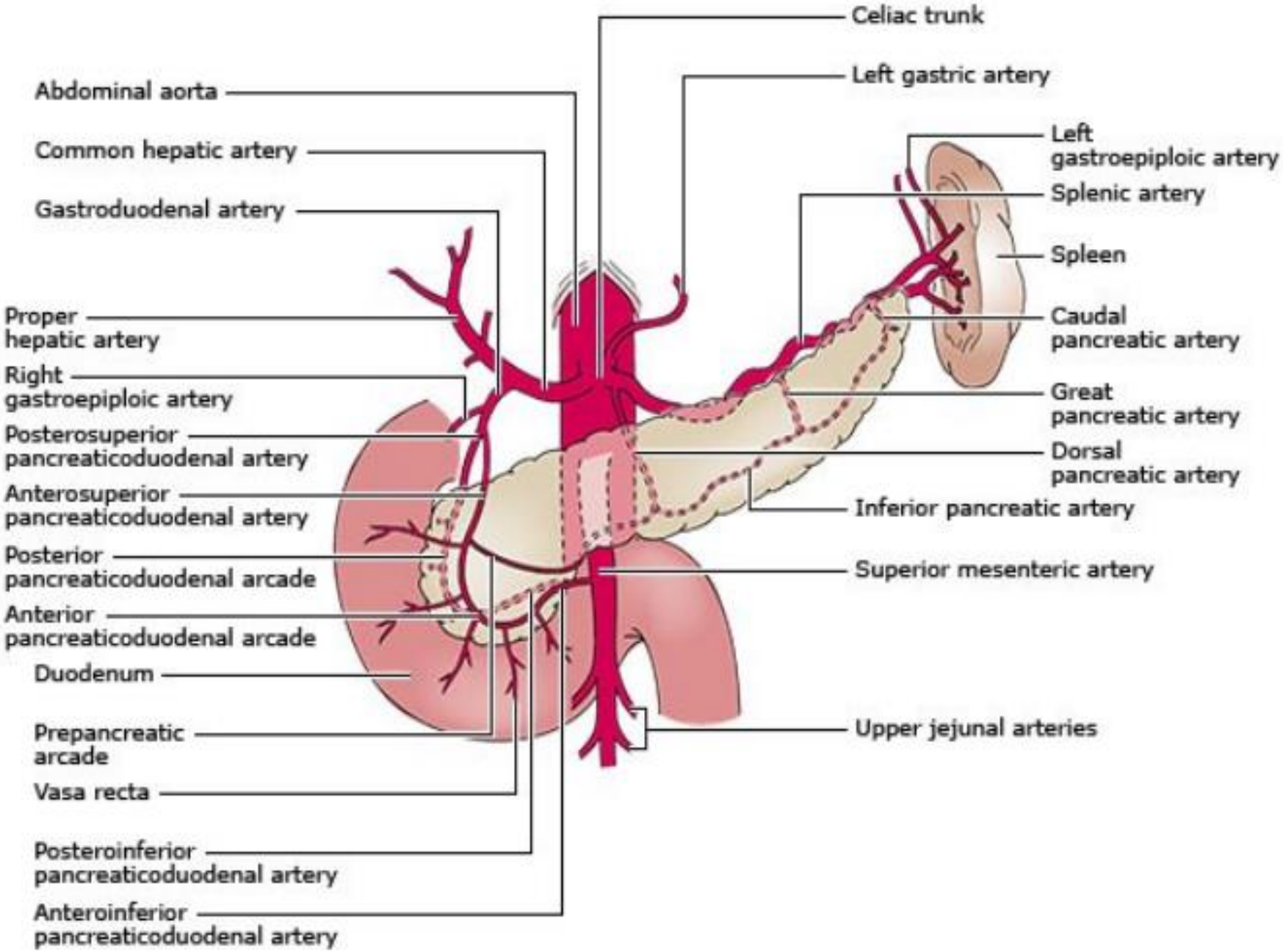
Celiac trunk
Left gastric artery
Abdominal aorta
Common hepatic artery
Gastroduodenal artery
Left gastroepiploic artery
Splenic artery
Spleen
Proper hepatic artery
Caudal pancreatic artery
Right gastroepiploic artery
Great pancreatic artery
Posterosuperior pancreaticoduodenal artery
Dorsal pancreatic artery
Anterosuperior pancreaticoduodenal artery
Inferior pancreatic artery
Posterior pancreaticoduodenal arcade
Superior mesenteric artery
Anterior pancreaticoduodenal arcade
Duodenum
Upper jejunal arteries
Prepancreatic arcade
Vasa recta
Posteroinferior pancreaticoduodenal artery
Anteroinferior pancreaticoduodenal artery

- The venous drainage follows the arteries ,
- to provide tributaries to the splenic vein and superior mesenteric vein, which drain into the portal vein.

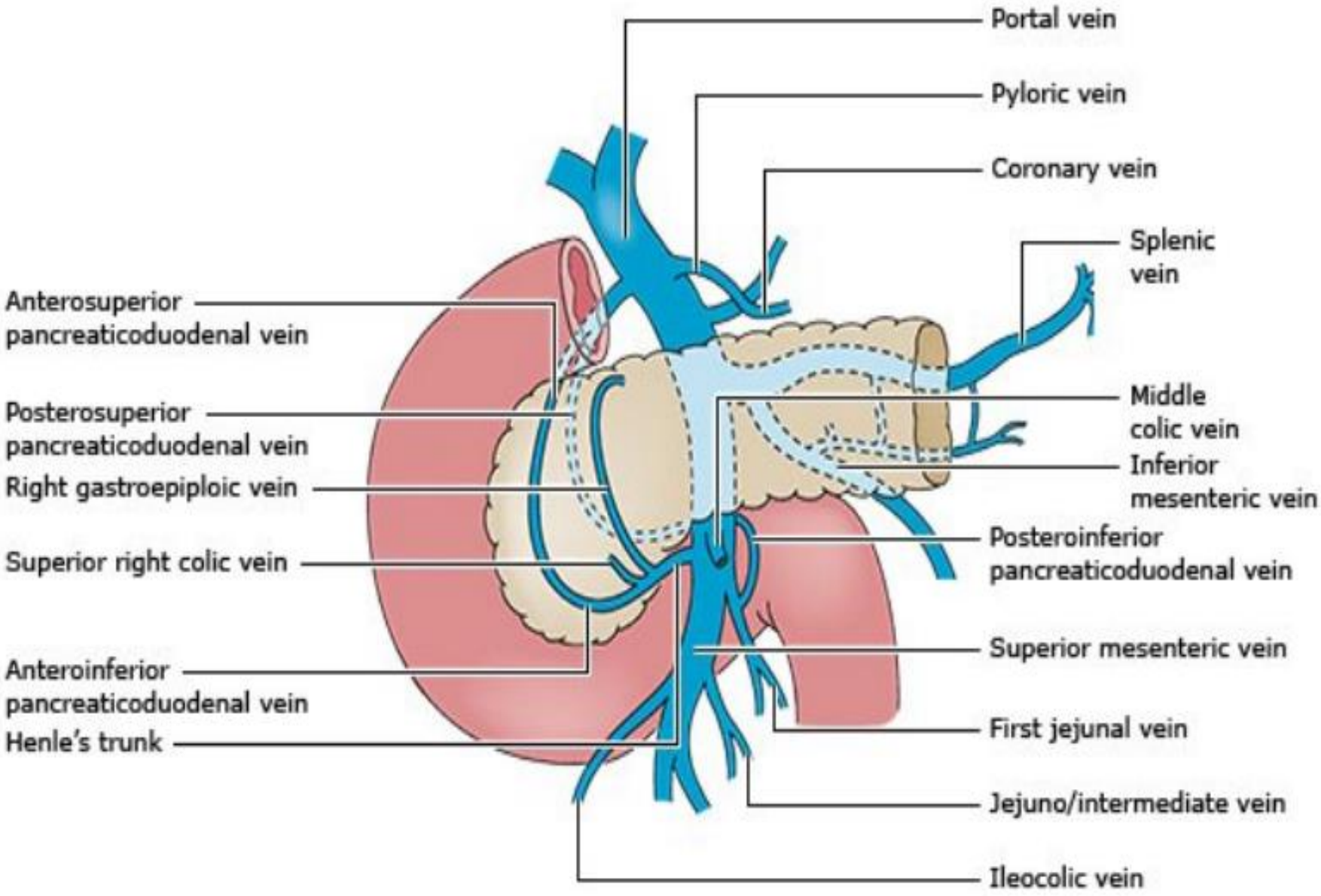
Portal vein
Pyloric vein
Coronary vein
Splenic vein
Anterosuperior pancreaticoduodenal vein
Posterosuperior pancreaticoduodenal vein
Right gastroepiploic vein
Superior right colic vein
Anteroinferior pancreaticoduodenal vein
Henle's trunk
Middle colic vein
Inferior mesenteric vein
Posteroinferior pancreaticoduodenal vein
Superior mesenteric vein
First jejunal vein
Jejuno/intermediate vein
Ileocolic vein

- Variations in the relation of the portal, splenic, superior mesenteric, and inferior mesenteric veins .

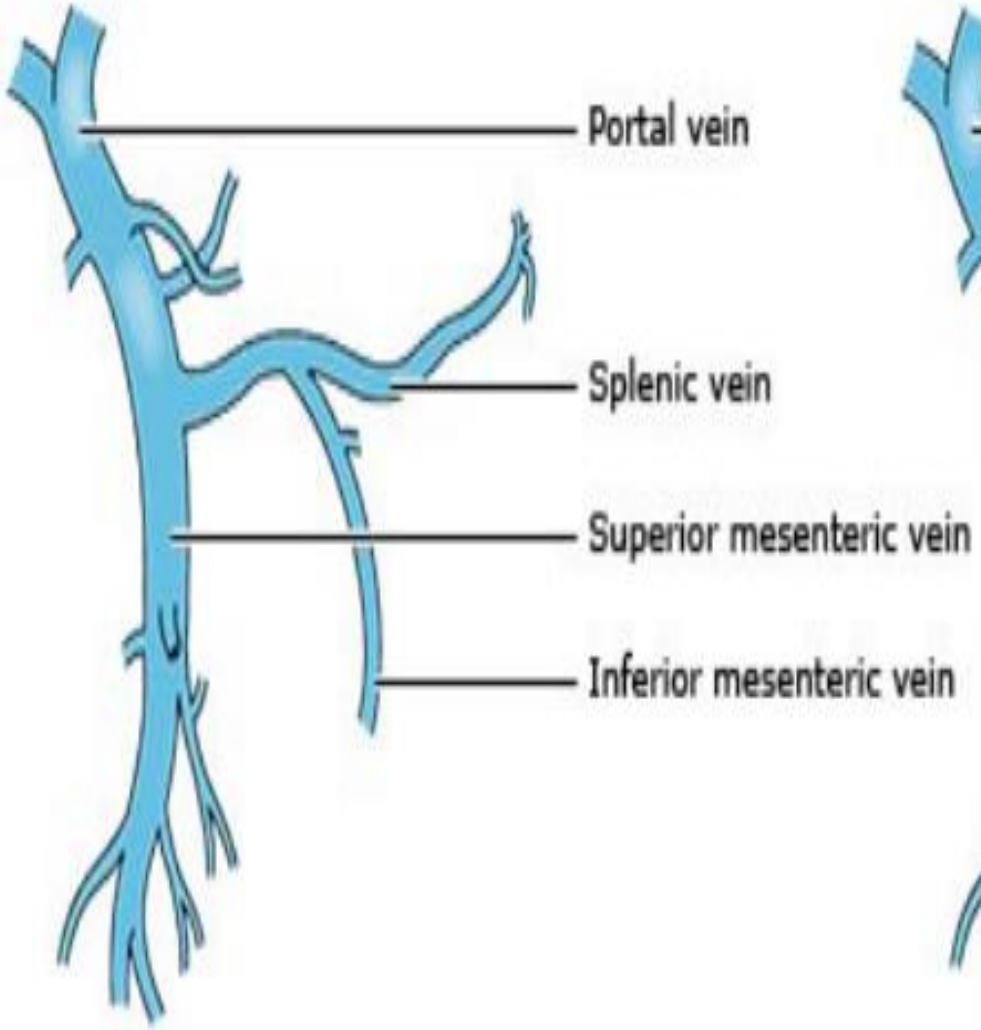
Portal vein
Splenic vein
Superior mesenteric vein
Inferior mesenteric vein

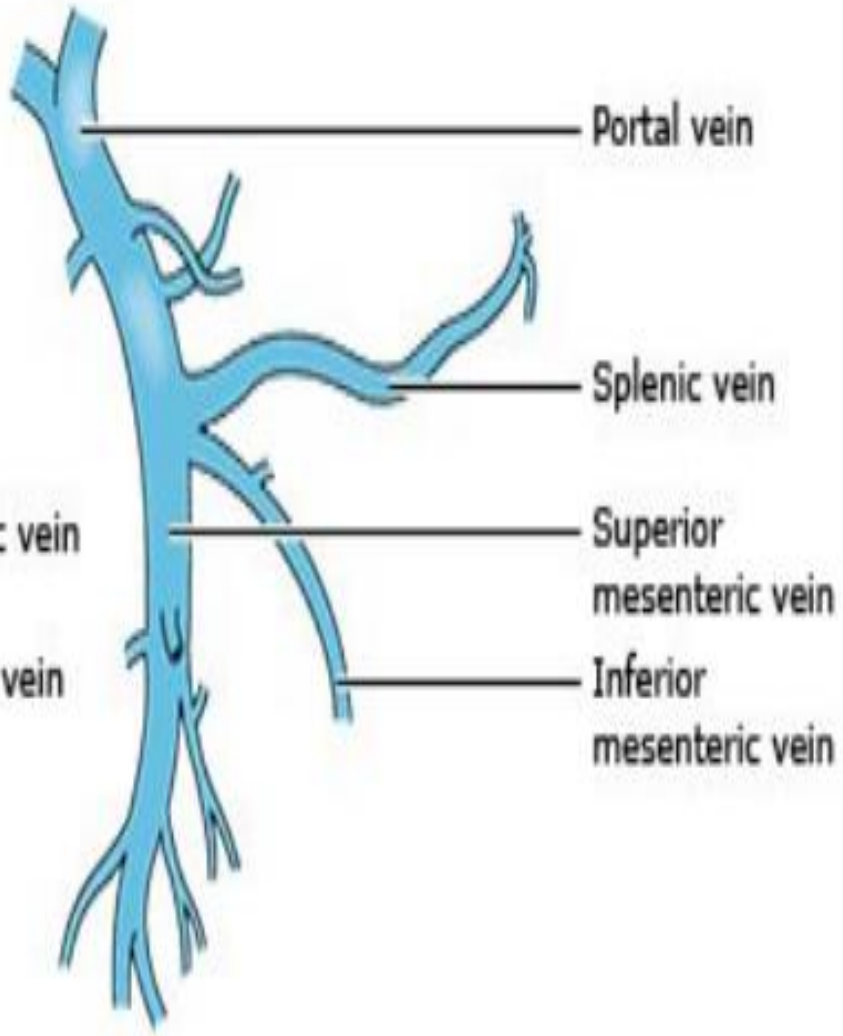
Portal vein
Splenic vein
Superior mesenteric vein
Inferior mesenteric vein

- The pancreas is innervated by sympathetic fibers from the splanchnic nerves,
- and parasympathetic fibers from the vagus,
- both of which give rise to intrapancreatic and periacinar nerve plexuses.

- The parasympathetic fibers stimulate exocrine and endocrine function,
- whereas the sympathetic fibers have an inhibitory effect.

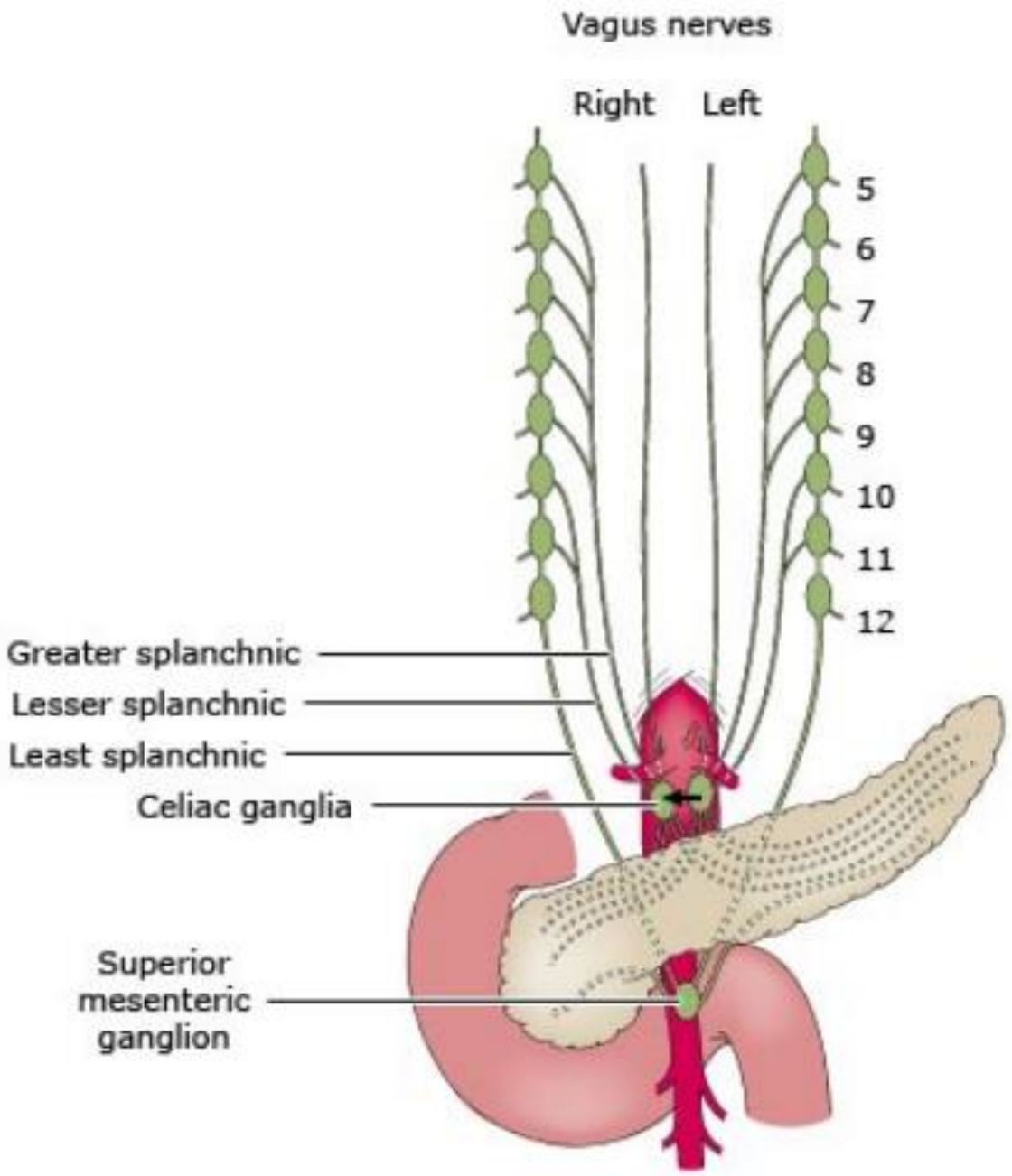
Vagus nerves
Right
Left
5
6
7
8
9
10
11
12
Greater splanchnic
Lesser splanchnic
Least splanchnic
Celiac ganglia
Superior mesenteric ganglion

- Acute pancreatitis is an inflammatory condition of the pancreas characterized by abdominal pain and elevated levels of pancreatic enzymes in the blood.
- Acute Several conditions are associated with acute pancreatitis.
- Of these, gallstones and chronic alcohol use disorder account for approximately two thirds of cases.

- The reported annual incidence of acute pancreatitis ranges from 4.9 to 35 per 100,000 population .
- The incidence of acute pancreatitis is increasing worldwide due to increased rates of obesity and gallstones .

- Smoking may increase the risk for non-gallstone-related pancreatitis by mechanisms that are unclear ,
- and may potentiate alcohol-induced damage to the pancreas .

- acute pancreatitis, overall mortality was approximately 5 percent,
- with mortality rates in patients with interstitial, and necrotizing pancreatitis, of 3 percent, and 17 percent, respectively .
- Mortality in acute pancreatitis is usually due to systemic inflammatory response syndrome and organ failure in the first two-week period,
- while after two weeks it is usually due to sepsis and its complications .

- **CLASSIFICATION :**
  — According to the Atlanta classification, acute pancreatitis can be divided into two broad categories :
- Interstitial edematous acute pancreatitis, which is characterized by acute inflammation of the pancreatic parenchyma and peripancreatic tissues, but without recognizable tissue necrosis.
- Necrotizing acute pancreatitis, which is characterized by inflammation associated with pancreatic parenchymal necrosis and/or peripancreatic necrosis.

- According to the severity, acute pancreatitis is divided into the following:
- Mild acute pancreatitis, which is characterized by the absence of organ failure and local or systemic complications,
- Moderately severe acute pancreatitis, which is characterized by no organ failure or transient organ failure (<48 hours) and/or local complications.
- Severe acute pancreatitis, which is characterized by persistent organ failure (>48 hours) that may involve one or multiple organs.

- CT Severity index (Balthazar Score):
- Grade of pancreatitis on CT
- A Normal pancreas (0 point)
- B Pancreatic enlargement (1 point)
- C Pancreatic enlargement with peripancreatic inflammation (2 points)
- D Extrapancreatic changes plus 1 fluid collection (3 points)
- E More than 1 fluid collection (4 points)

- **Interstitial edematous pancreatitis:**
  Acute inflammation of the pancreatic parenchyma and peripancreatic tissues,
- but without recognizable tissue necrosis ,
- *Contrast-enhanced computed tomography criteria:*
  Pancreatic parenchyma enhancement by intravenous contrast agent,
- No findings of peripancreatic necrosis

- The computed tomography (CT) scan in a 75-year-old man with acute interstitial pancreatitis reveals heterogeneous appearance of the pancreas (arrow) and peripancreatic fat stranding (arrowhead).

- **Necrotizing pancreatitis:**
  Inflammation associated with pancreatic parenchymal necrosis and/or peripancreatic necrosis,
- *Contrast-enhanced computed tomography criteria:*
  Lack of pancreatic parenchymal enhancement by intravenous contrast agent,
- and/or Presence of findings of peripancreatic necrosis

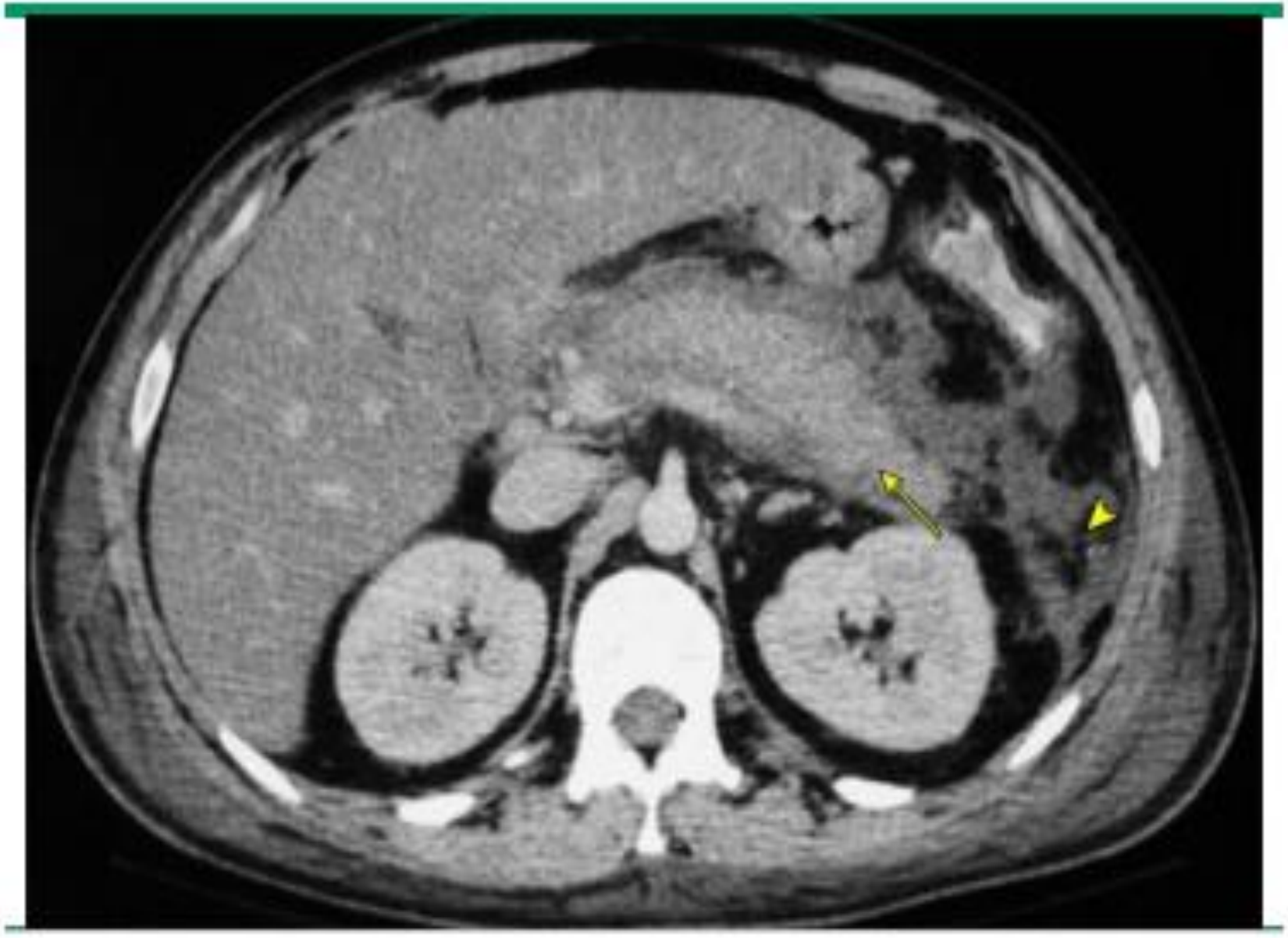

- Computed tomography (CT) scan of a 34-year-old male with acute pancreatitis reveals the pancreas enhances homogeneously (arrow) but there is evidence of peripancreatic necrosis (arrowhead).

- **Acute peripancreatic fluid collection (APFC):**
  Peripancreatic fluid associated with interstitial edematous pancreatitis with no associated peripancreatic necrosis.
- This term applies only to areas of peripancreatic fluid seen within the first four weeks after onset of interstitial edematous pancreatitis ,
- and without the features of a pseudocyst.
- *Contrast-enhanced computed tomography criteria:*
  Occurs in the setting of interstitial edematous pancreatitis,
- Homogeneous collection with fluid density
- Confined by normal peripancreatic fascial planes
- No definable wall encapsulating the collection Adjacent to pancreas (no intrapancreatic extension)

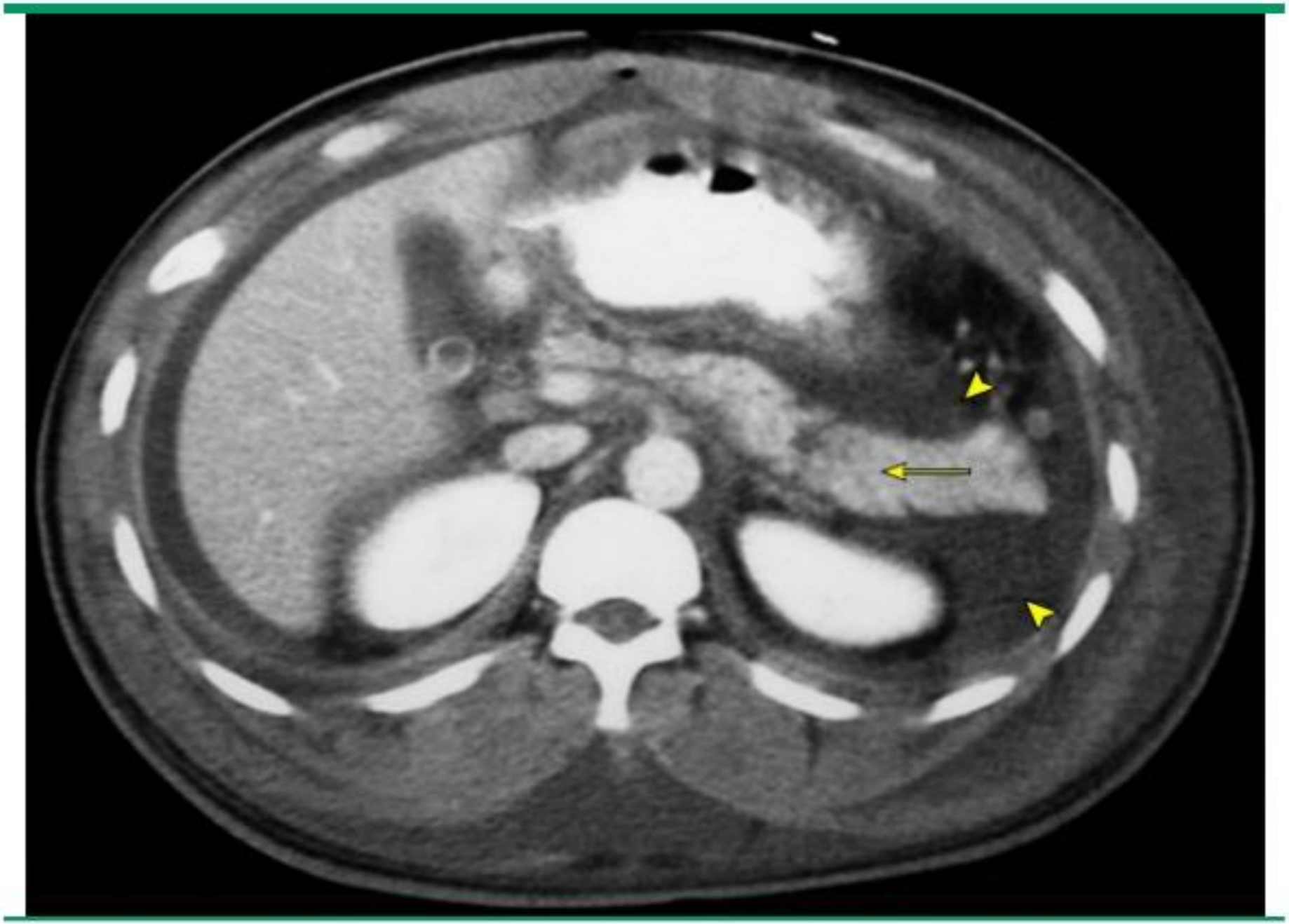

- Computed tomography (CT) scan reveals acute interstitial pancreatitis with an acute peripancreatic fluid collections (APFC) around the body and tail of the pancreas (arrowheads). There is mild heterogeneity of the enhanced pancreas (arrow).

- **Pancreatic pseudocyst:**
  An encapsulated collection of fluid with a well defined inflammatory wall usually outside the pancreas with minimal or no necrosis.
- This entity usually occurs more than four weeks after onset of interstitial edematous pancreatitis to mature.
- *Contrast-enhanced computed tomography criteria:*
  Well circumscribed, usually round or oval ,
- Homogeneous fluid density
- No non-liquid component
- Well defined wall (ie, completely encapsulated),
- Maturation usually requires >4 weeks after onset of acute pancreatitis;
- occurs after interstitial edematous pancreatitis

- **Acute necrotic collection (ANC):**
  A collection containing variable amounts of both fluid and necrosis associated with necrotizing pancreatitis;
- the necrosis can involve the pancreatic parenchyma and/or the peripancreatic tissues,
- *Contrast-enhanced computed tomography criteria:*
- Occurs only in the setting of acute necrotizing pancreatitis ,
- Heterogeneous and non-liquid density of varying degrees in different locations (some appear homogeneous early in their course)
- No definable wall encapsulating the collection
- Location—intrapancreatic and/or extra pancreatic .

- Computed tomography (CT) scan reveals an acute necrotic collection in a 20-year-old female with acute pancreatitis. The axial CT image shows pancreatic necrosis with a nonenhancing region in the neck and the body of the pancreas (between arrowheads). In the surrounding anterior pararenal space, there is a large fluid accumulation that contains islands of necrosis (arrow).

- **Walled-off necrosis (WON) :**
  A mature, encapsulated collection of pancreatic and/or peripancreatic necrosis that has developed a well defined inflammatory wall.
- WON usually occurs >4 weeks after onset of necrotizing pancreatitis.
- *Contrast-enhanced computed tomography criteria:*
- Heterogeneous with liquid and non-liquid density with varying degrees of loculations (some may appear homogeneous)
- Well defined wall, that is, completely encapsulated,
- Location—intrapancreatic and/or extrapancreatic ,
- Maturation usually requires four weeks after onset of acute