

A photograph of a winter forest scene. The ground is covered in a thick layer of white snow. Several large, dark tree trunks stand in the foreground, their branches heavily laden with snow. The background shows more trees and a soft, hazy light, suggesting a misty or snowy day. The overall atmosphere is serene and quiet.

In the name of god

Radiographic Features of the Inflammatory Lesions of the jaws

Dr. Farnoosh Khaksari

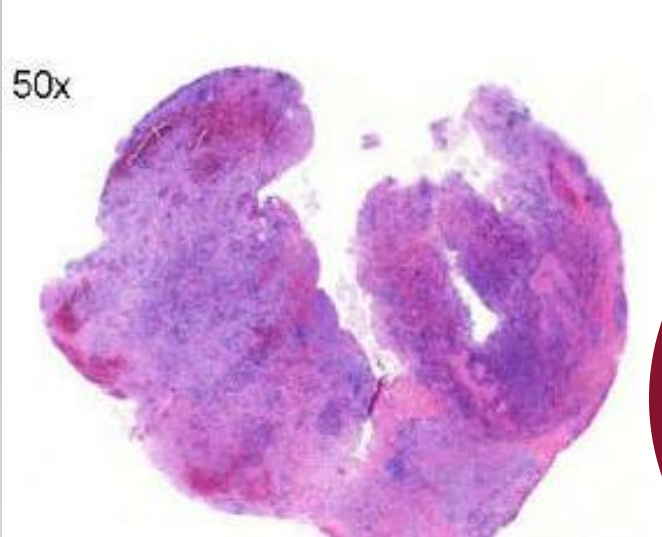
Oral and Maxillofacial Radiologist

Assistant Professor

Guilan University of Medical Sciences

3

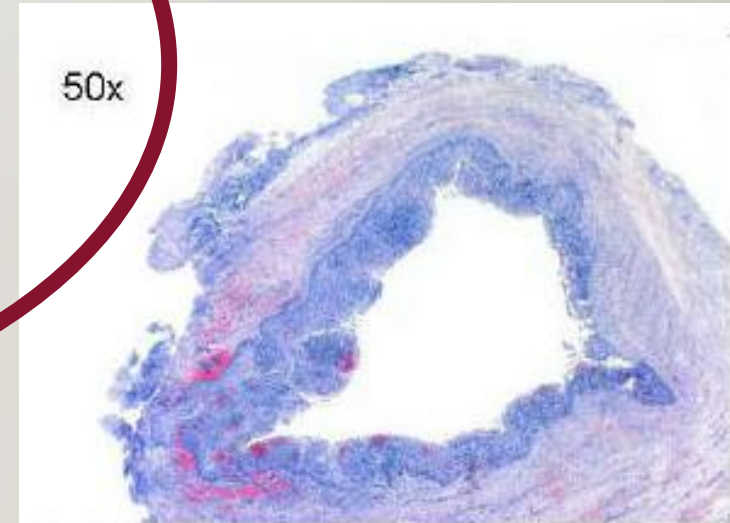
Periapical inflammatory lesions



Periapical Granuloma ?

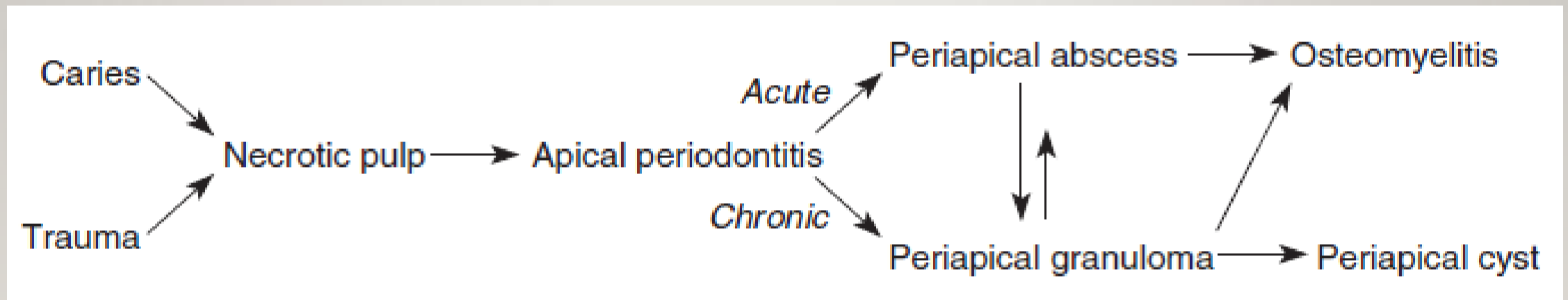
Radicular Cyst ?

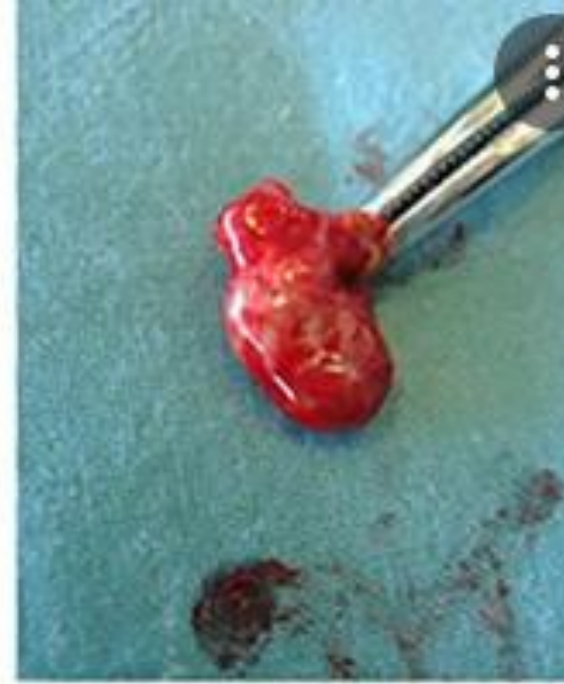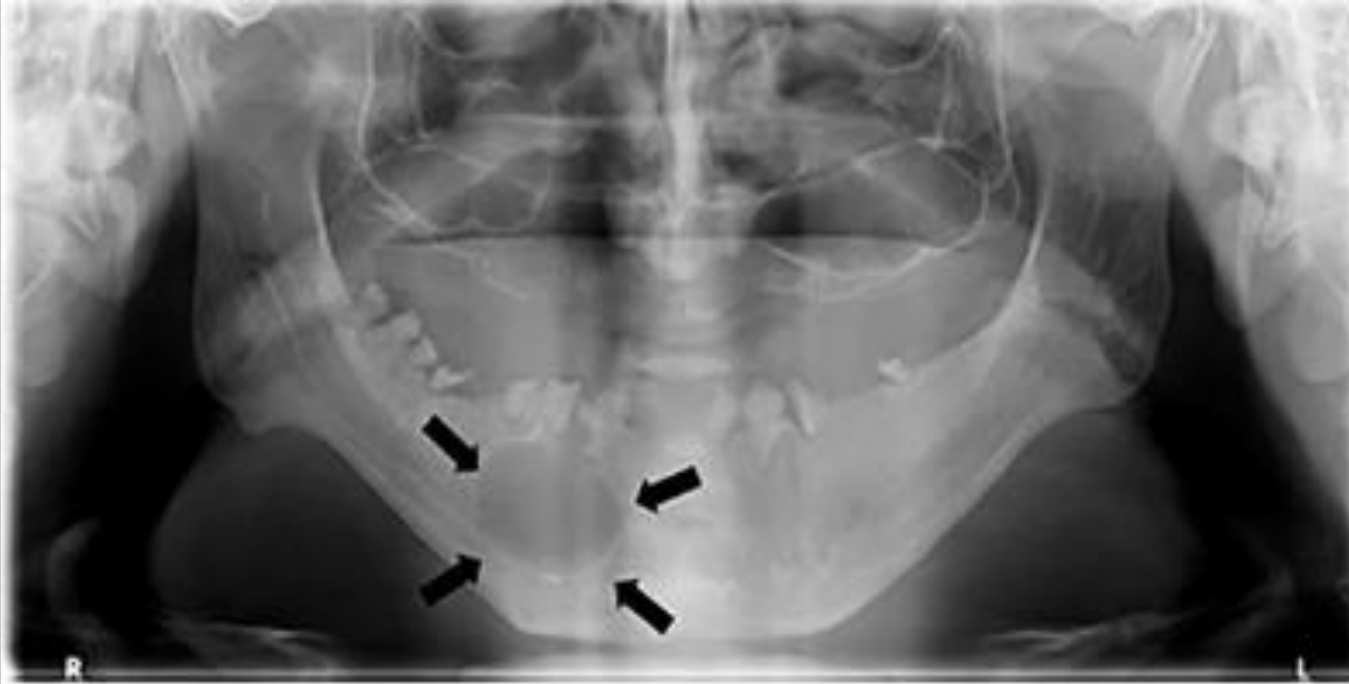Abscess ?



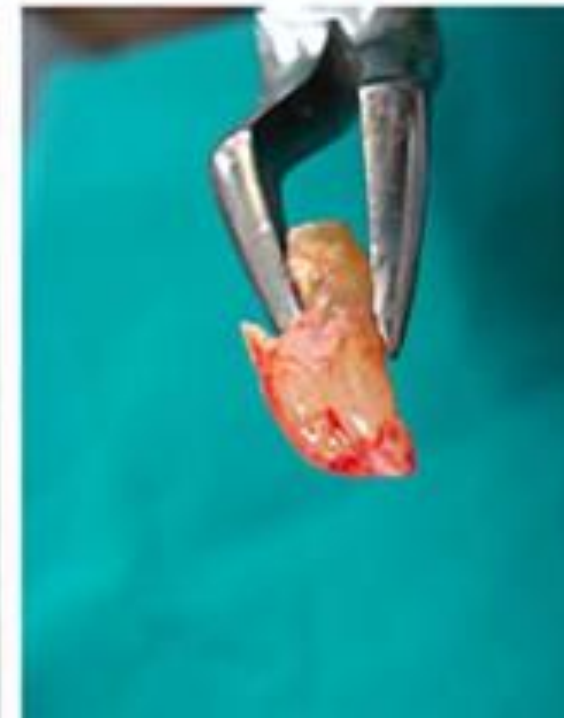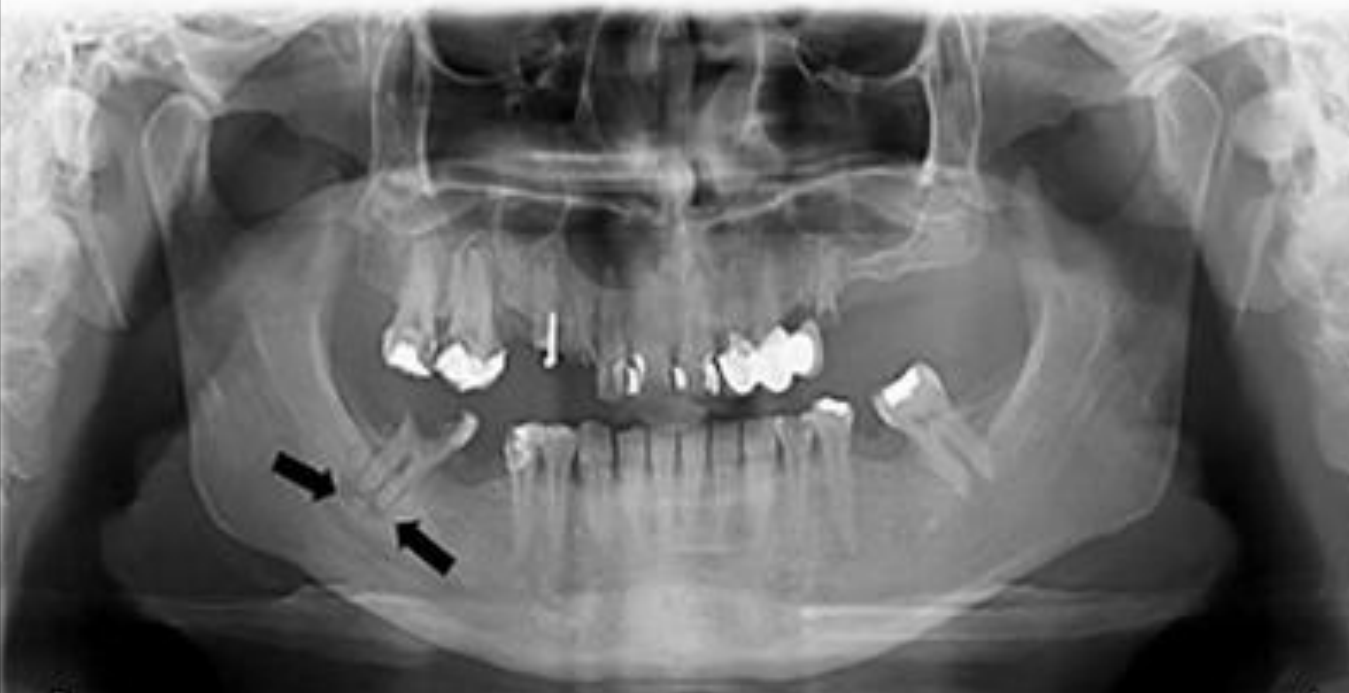4

Periapical inflammatory lesions



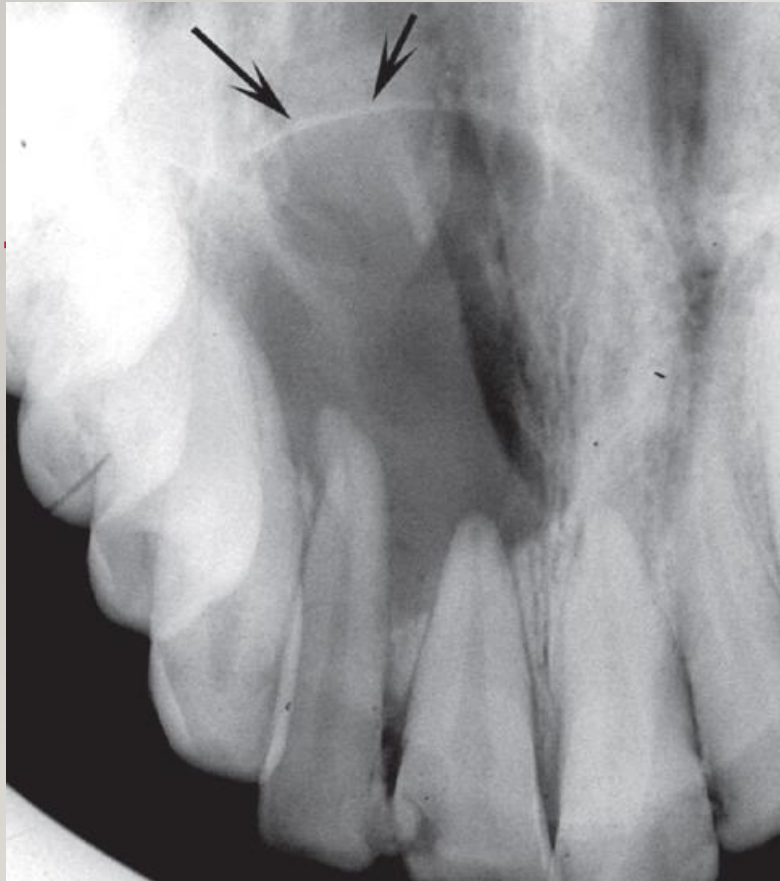

Cyst



Granuloma

6

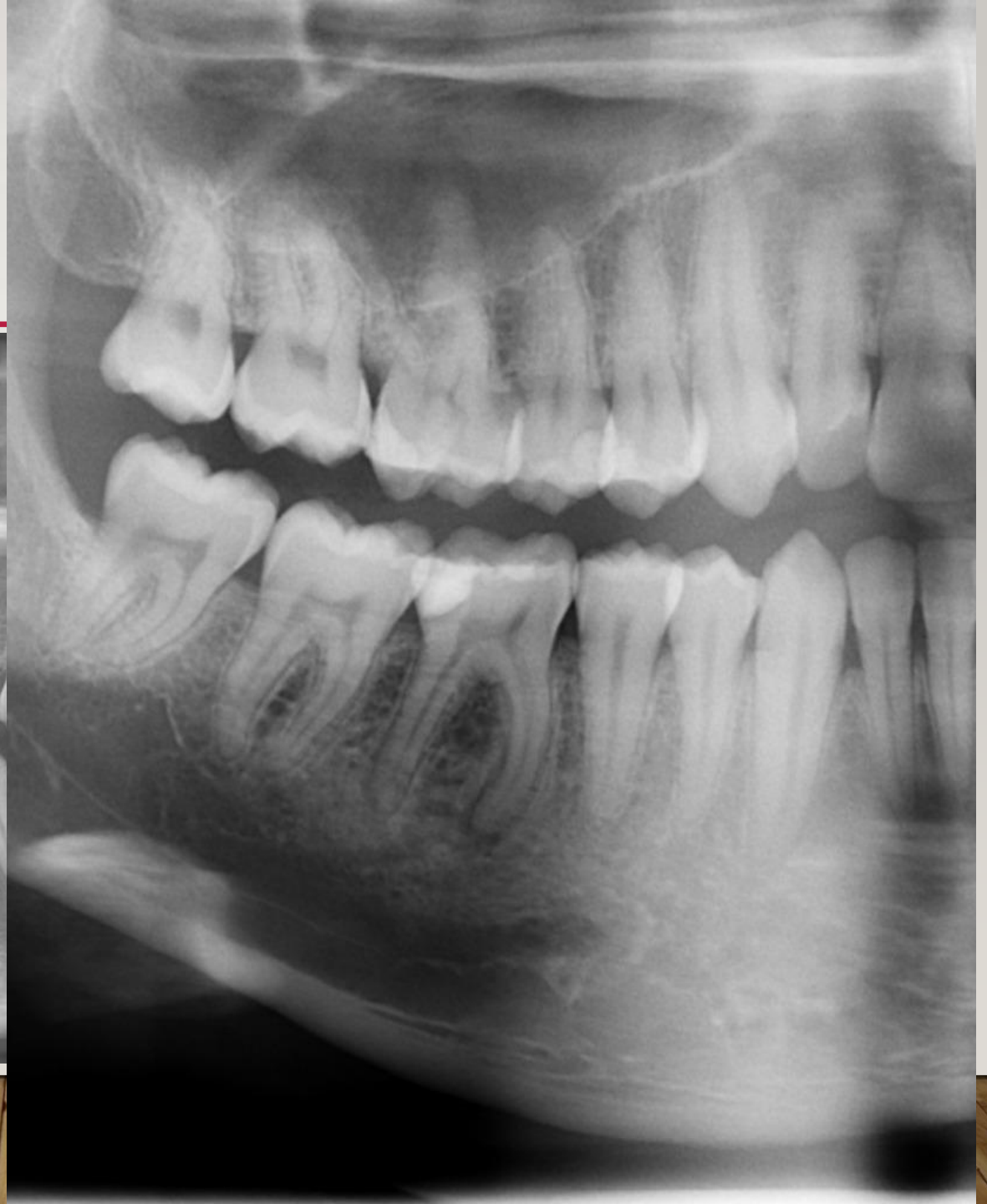
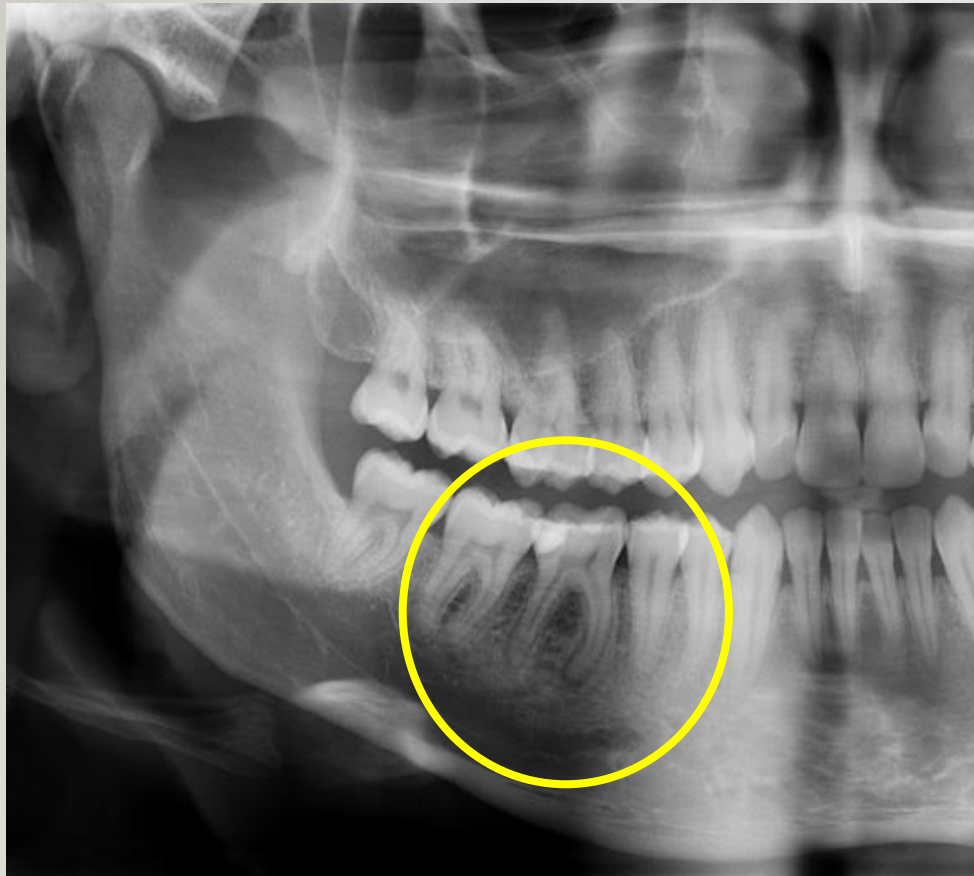
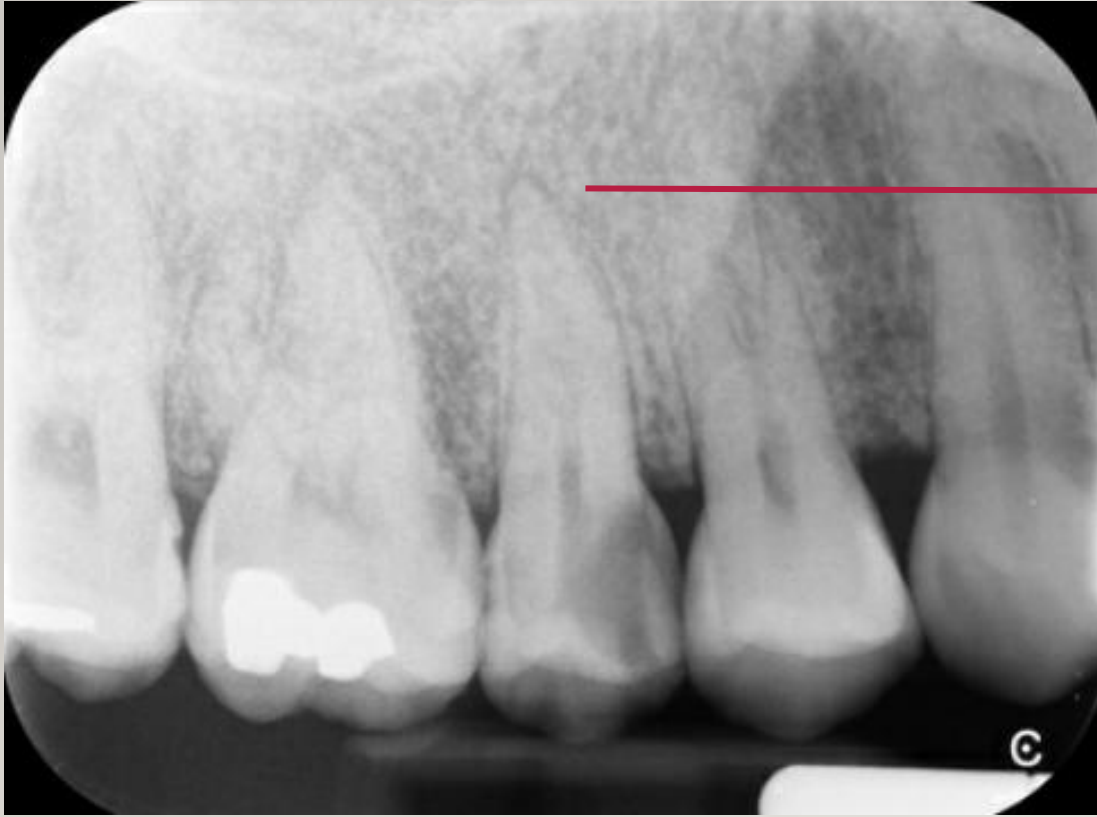Radicular cyst

- ☐ round shape
- ☐ well-defined cortical border
- ☐ size greater than 2 cm in diameter

7

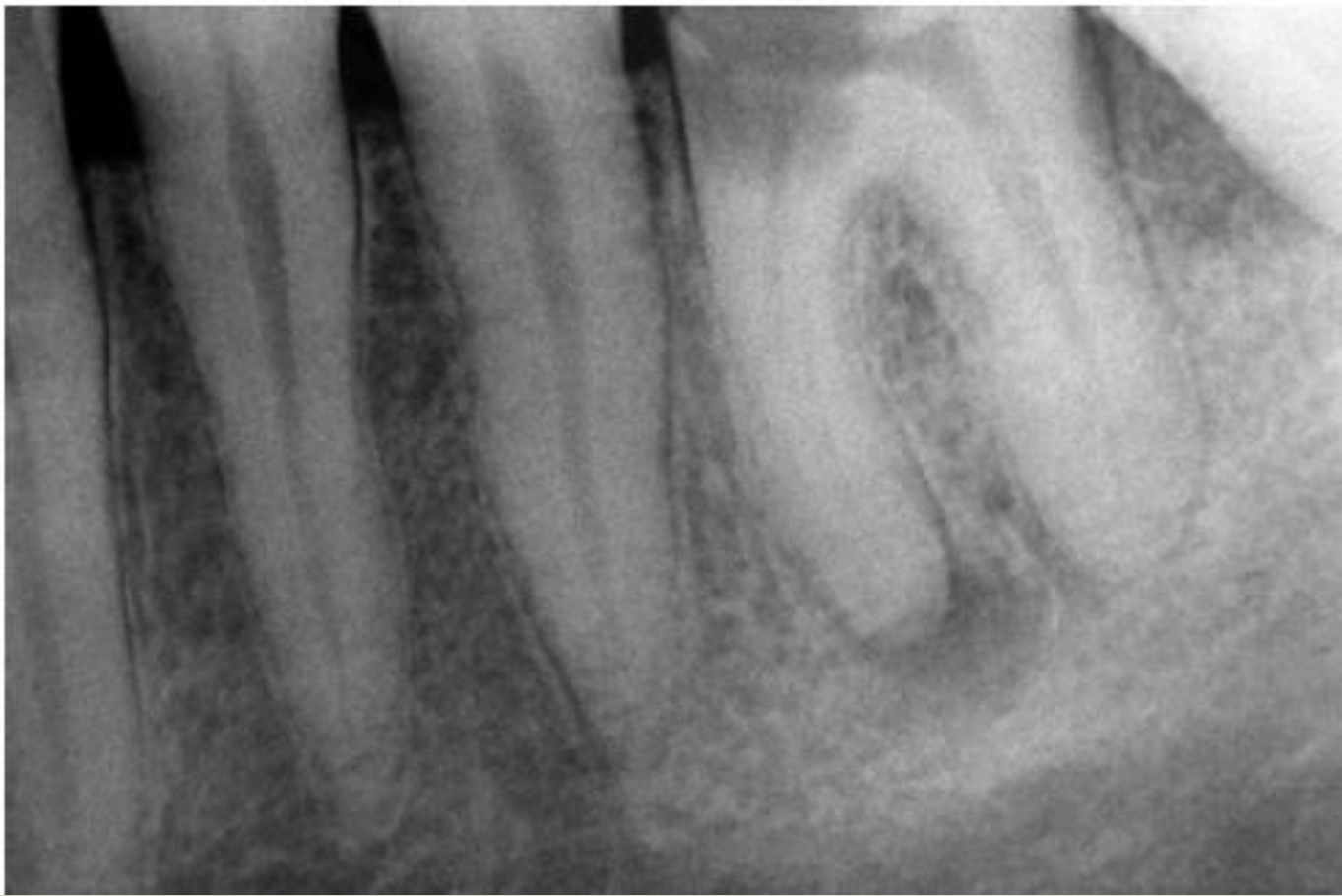Dental abscess





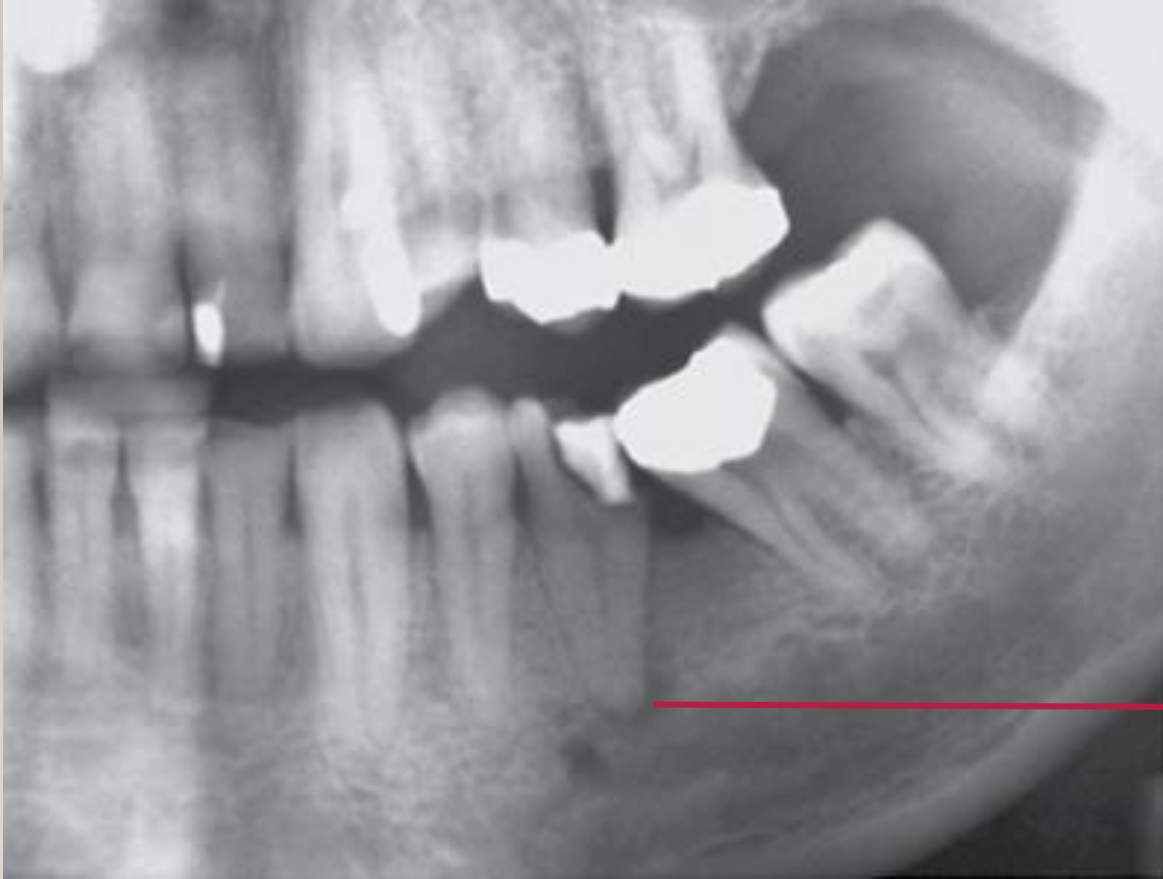A

**Early
inflammatory lesions**



rarefying osteitis

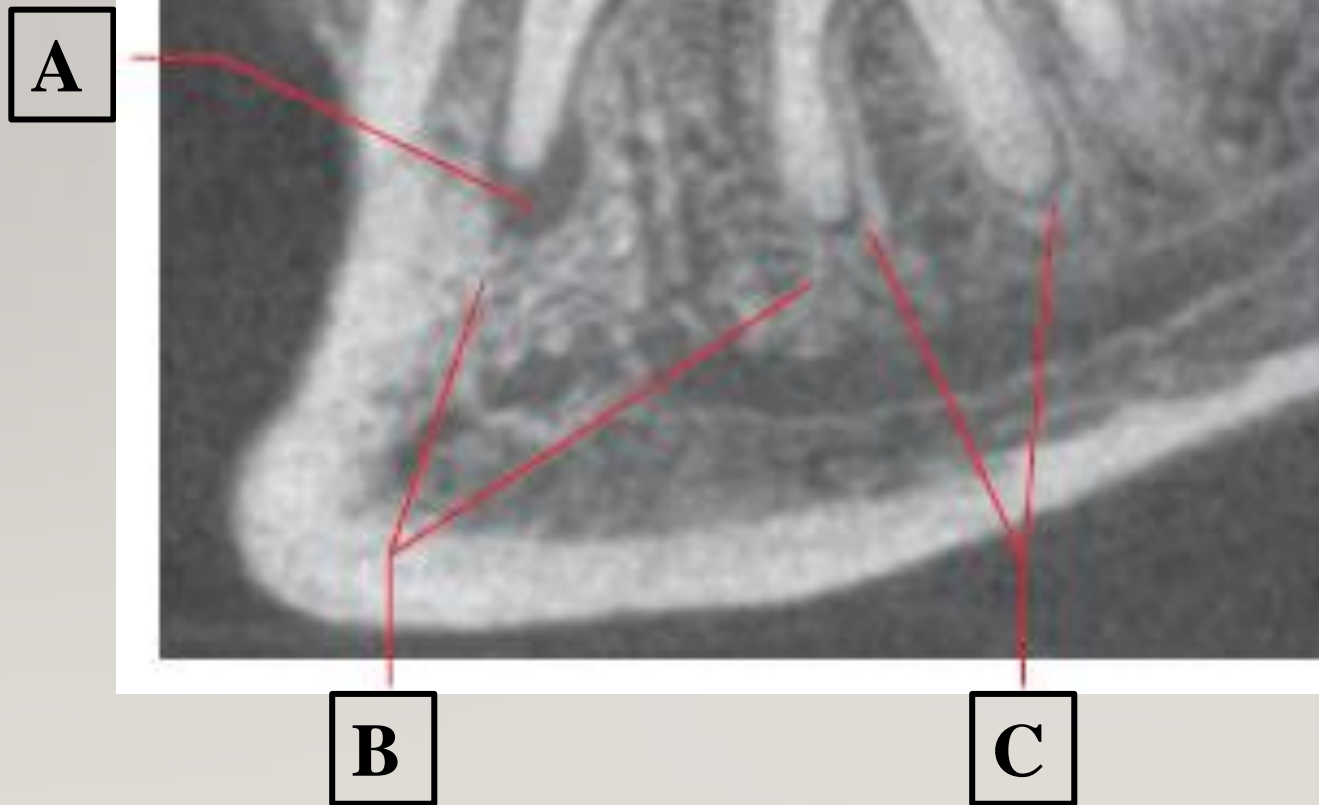
Sclerosing Osteitis

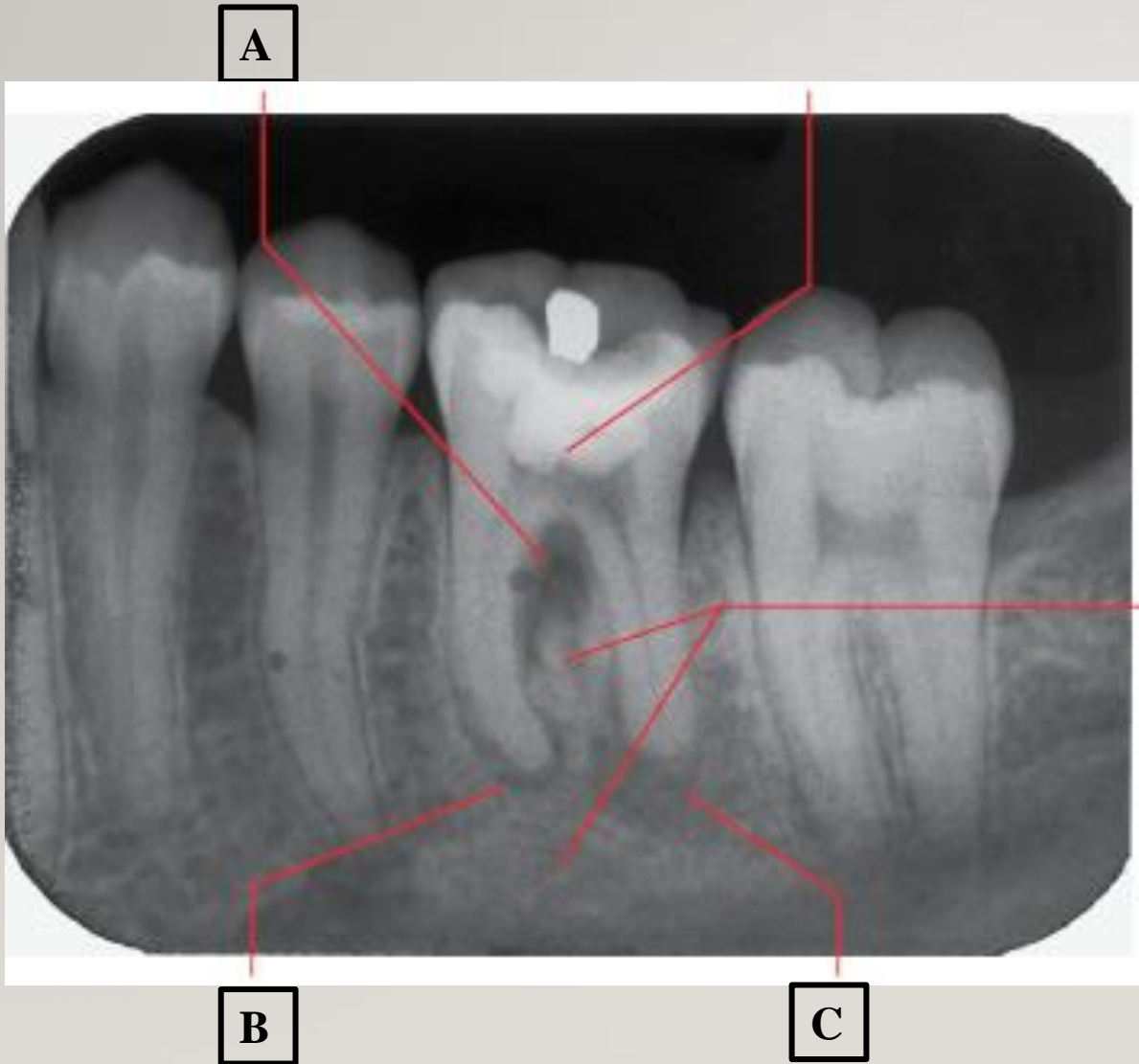


Periapical **chronic** inflammatory lesions

A

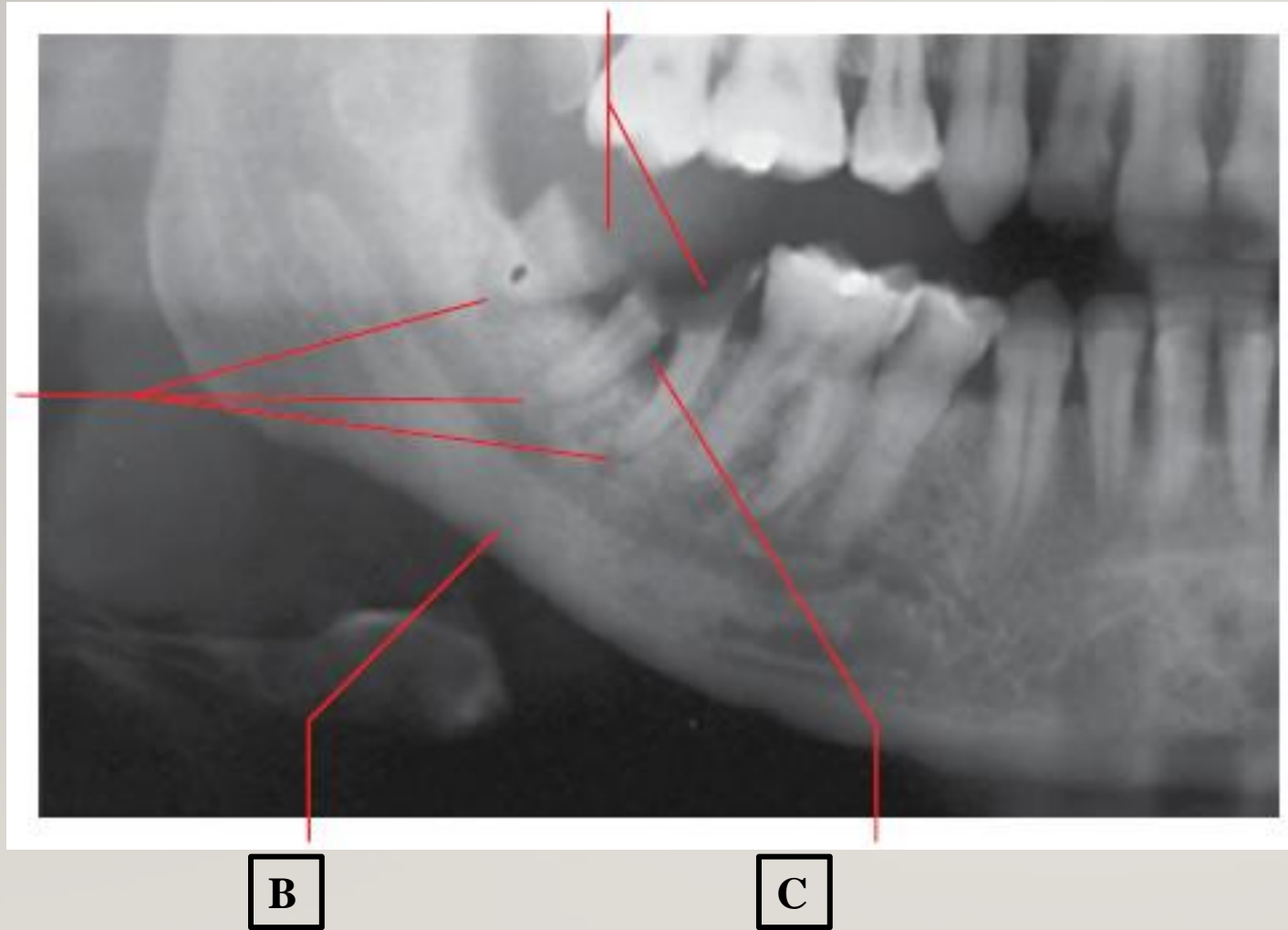
Periapical inflammatory lesions



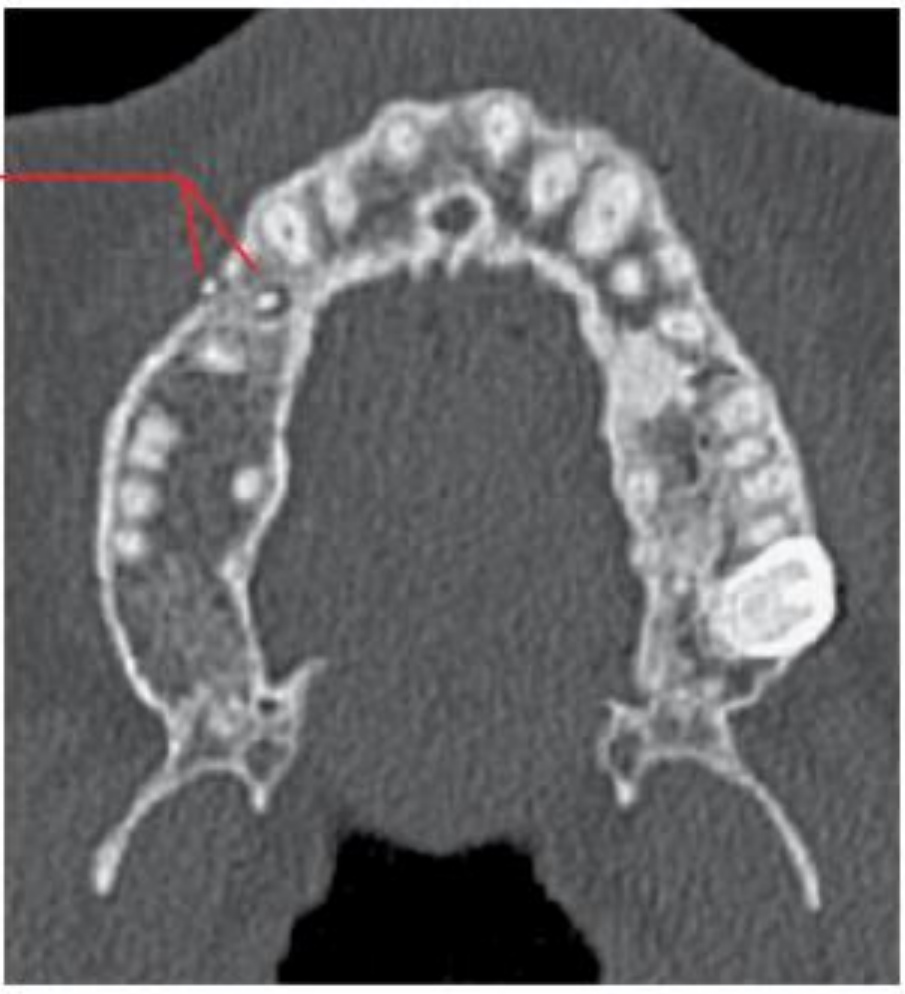

Periapical and furcation inflammatory lesions

Periapical and furcation inflammatory lesions

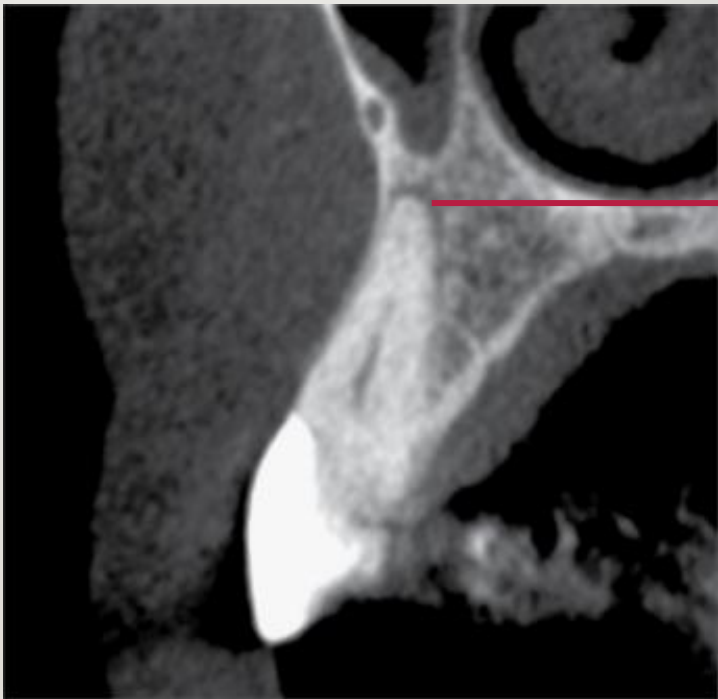


A

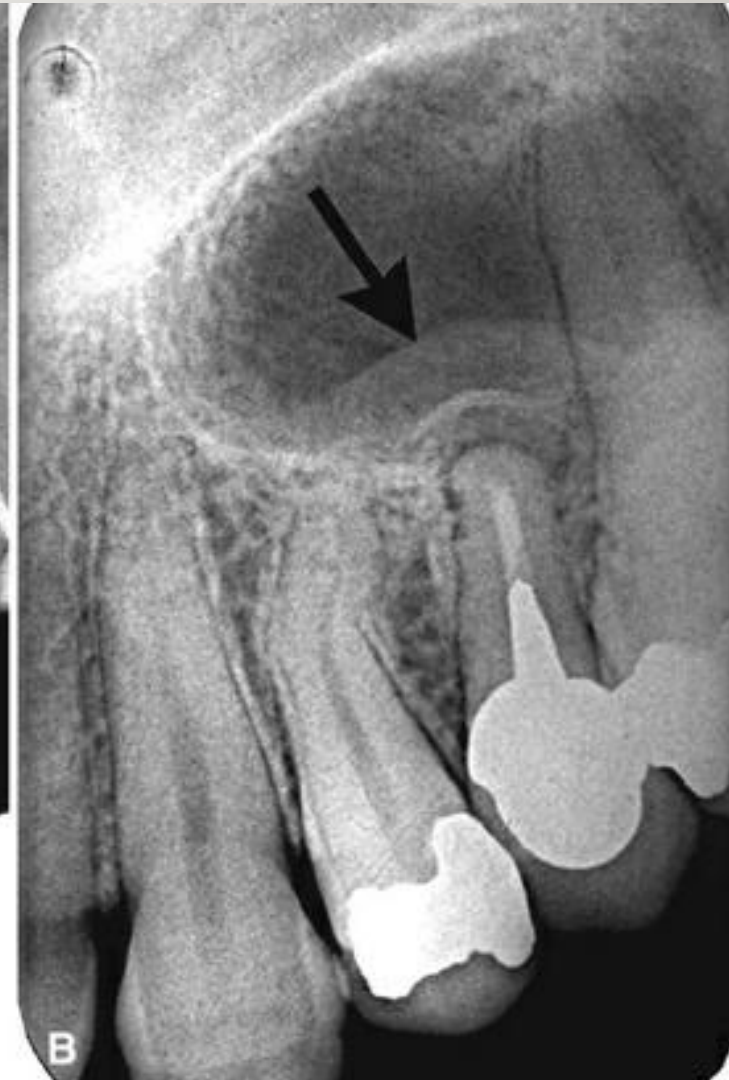
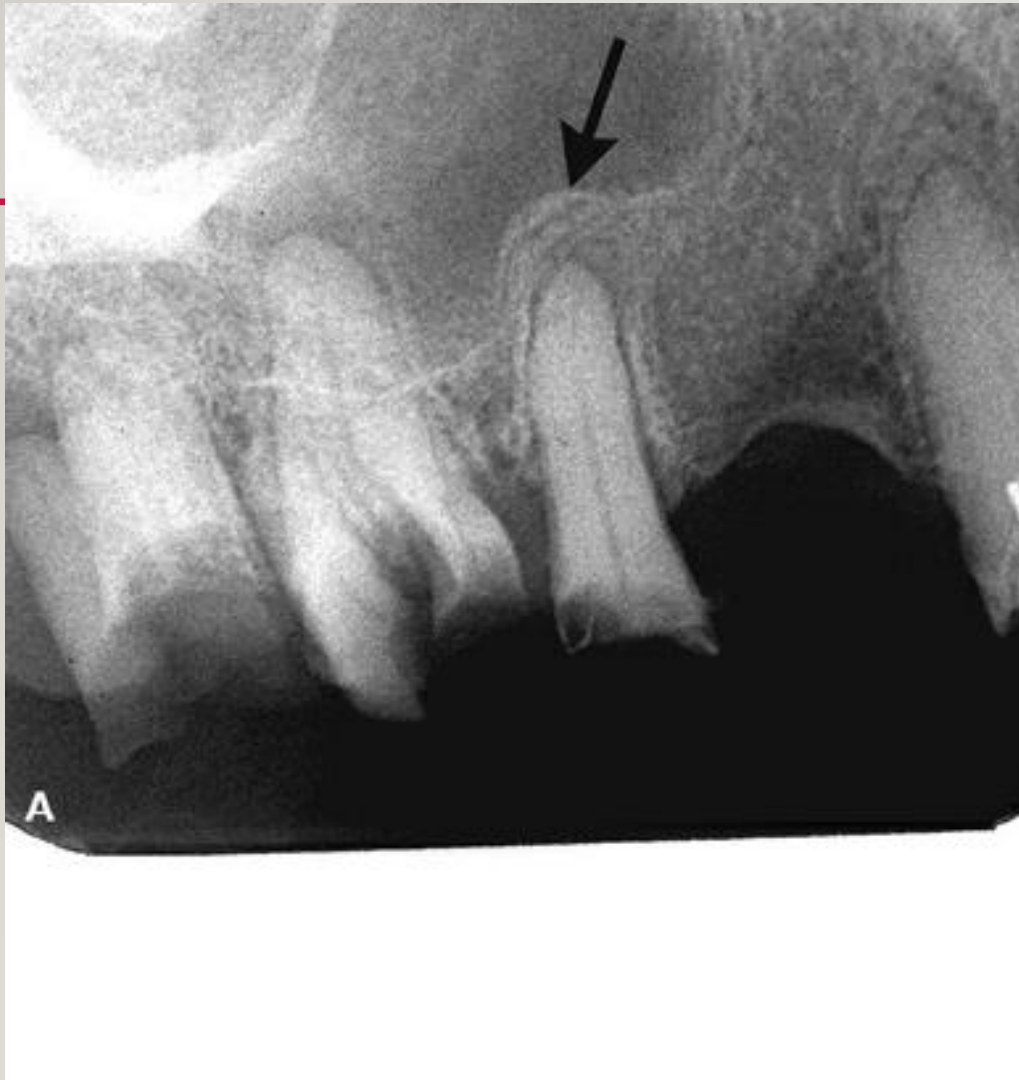

Periapical inflammatory lesions

B

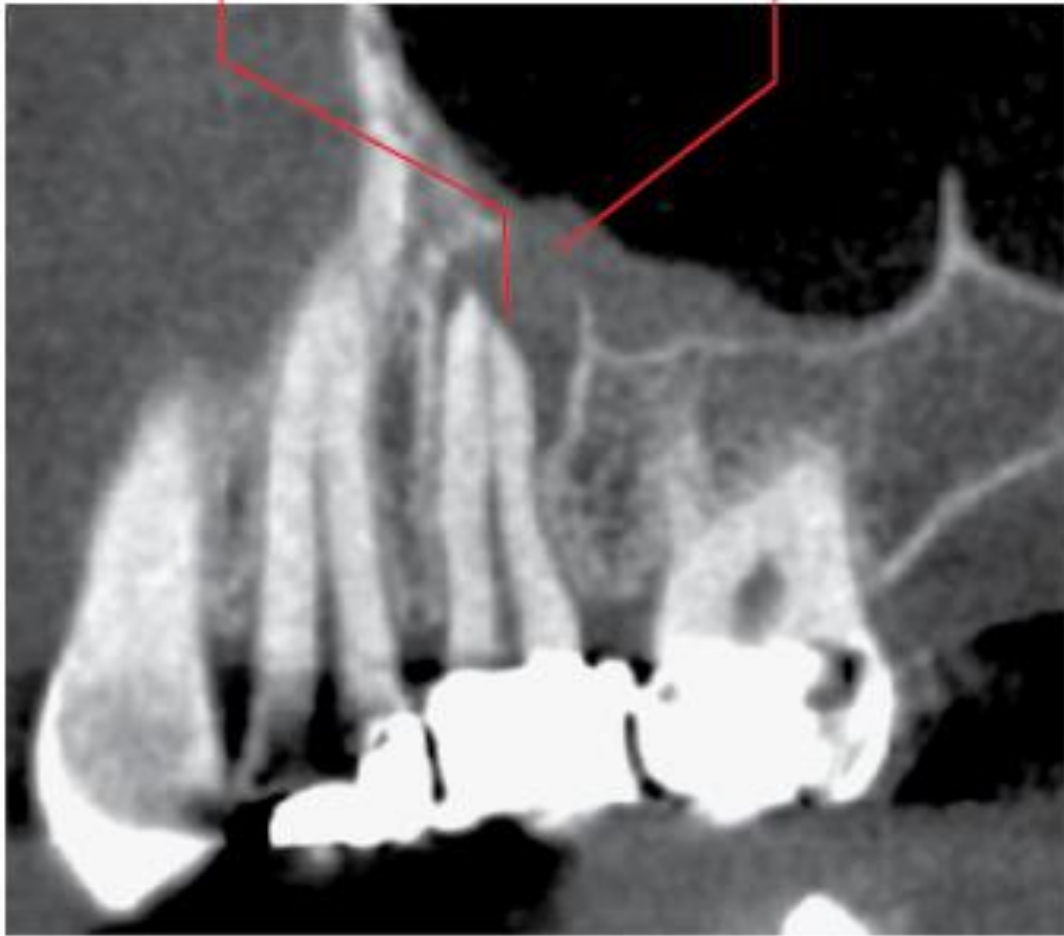


Periapical inflammatory lesions with reactive changes at the maxillary sinus base



A

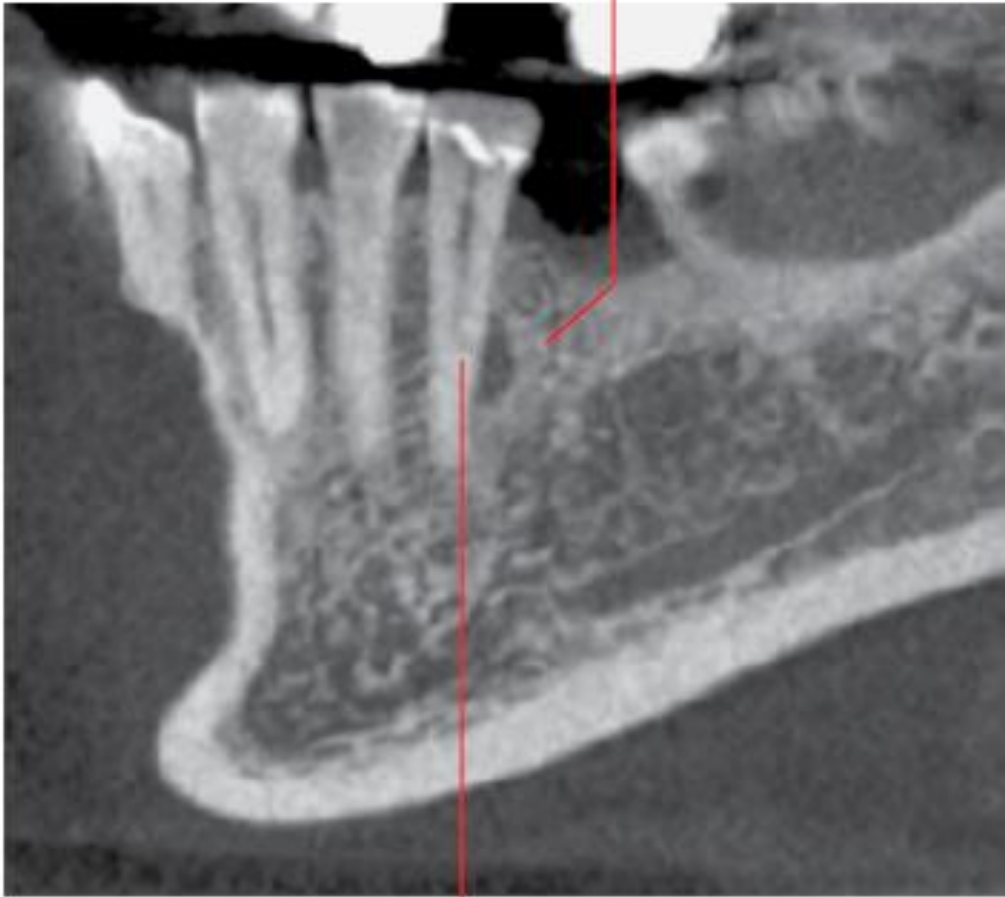B



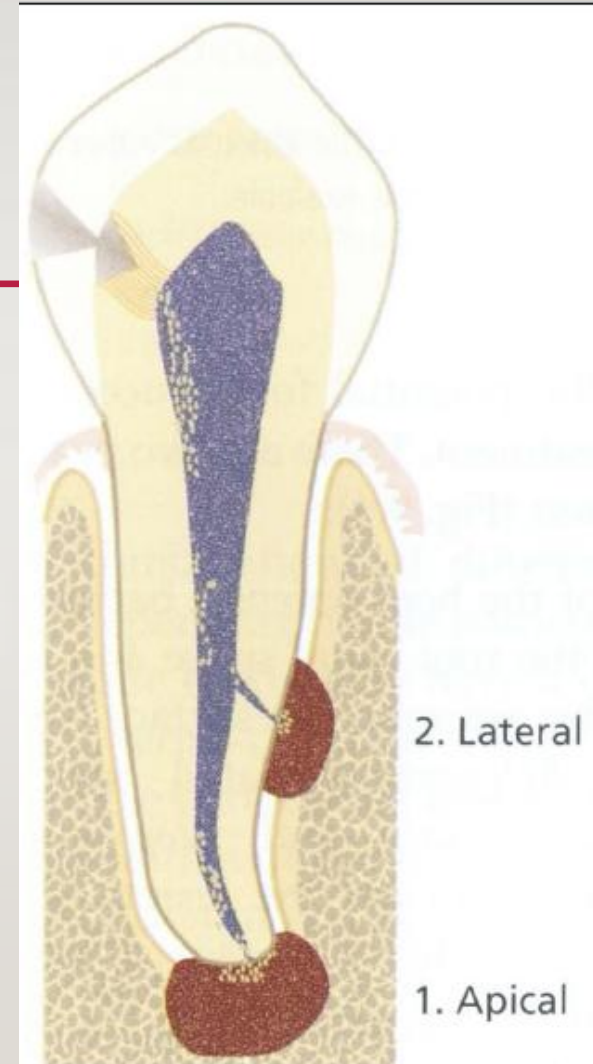
Periapical inflammatory lesions
with reactive changes at the
maxillary sinus base

Inflammatory lesion related to a **lateral canal**

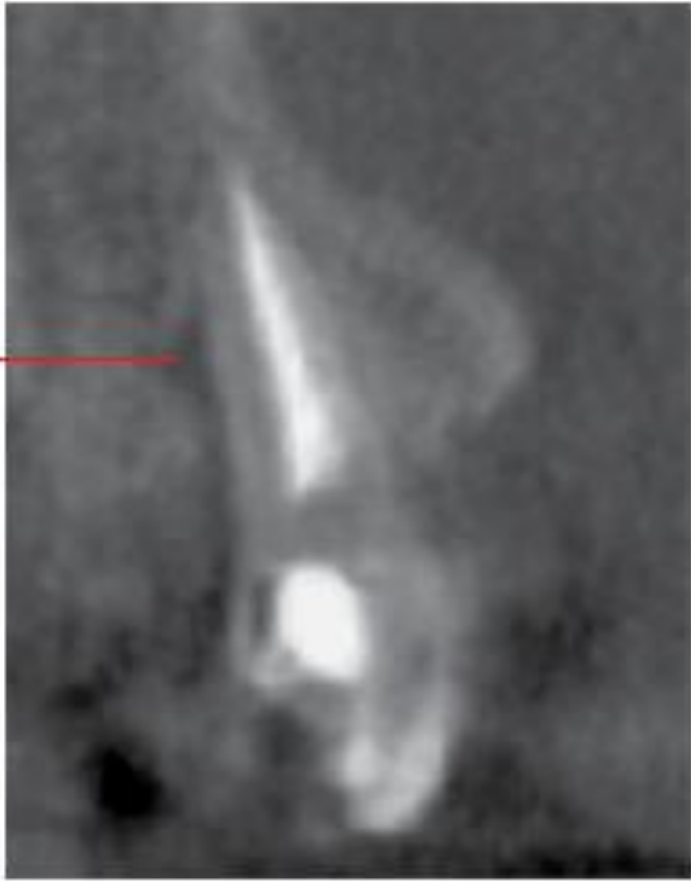
A



B

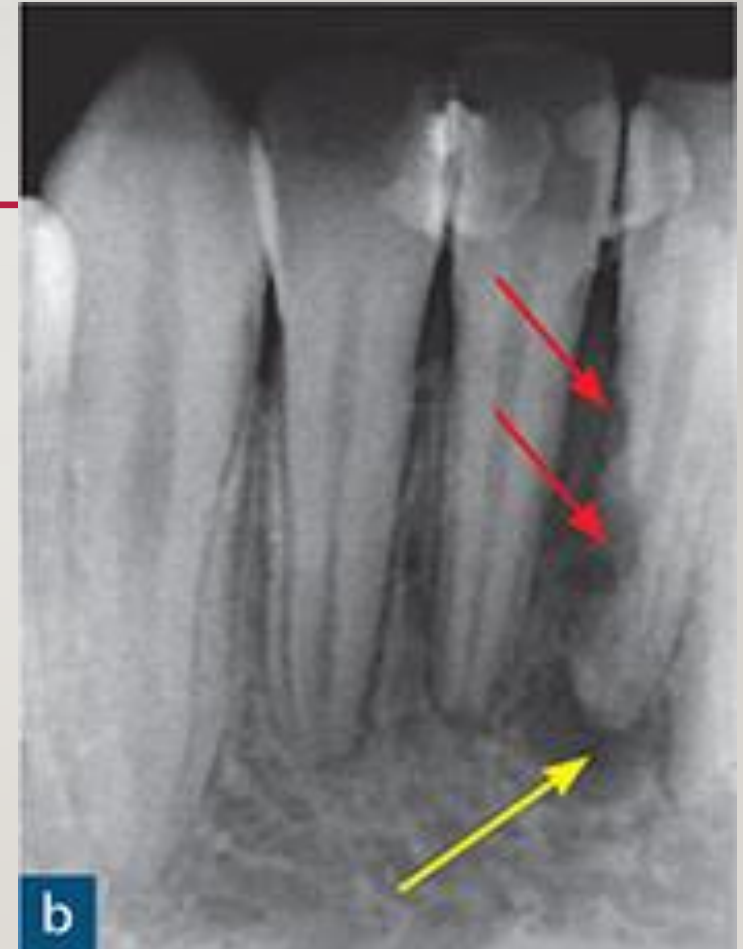
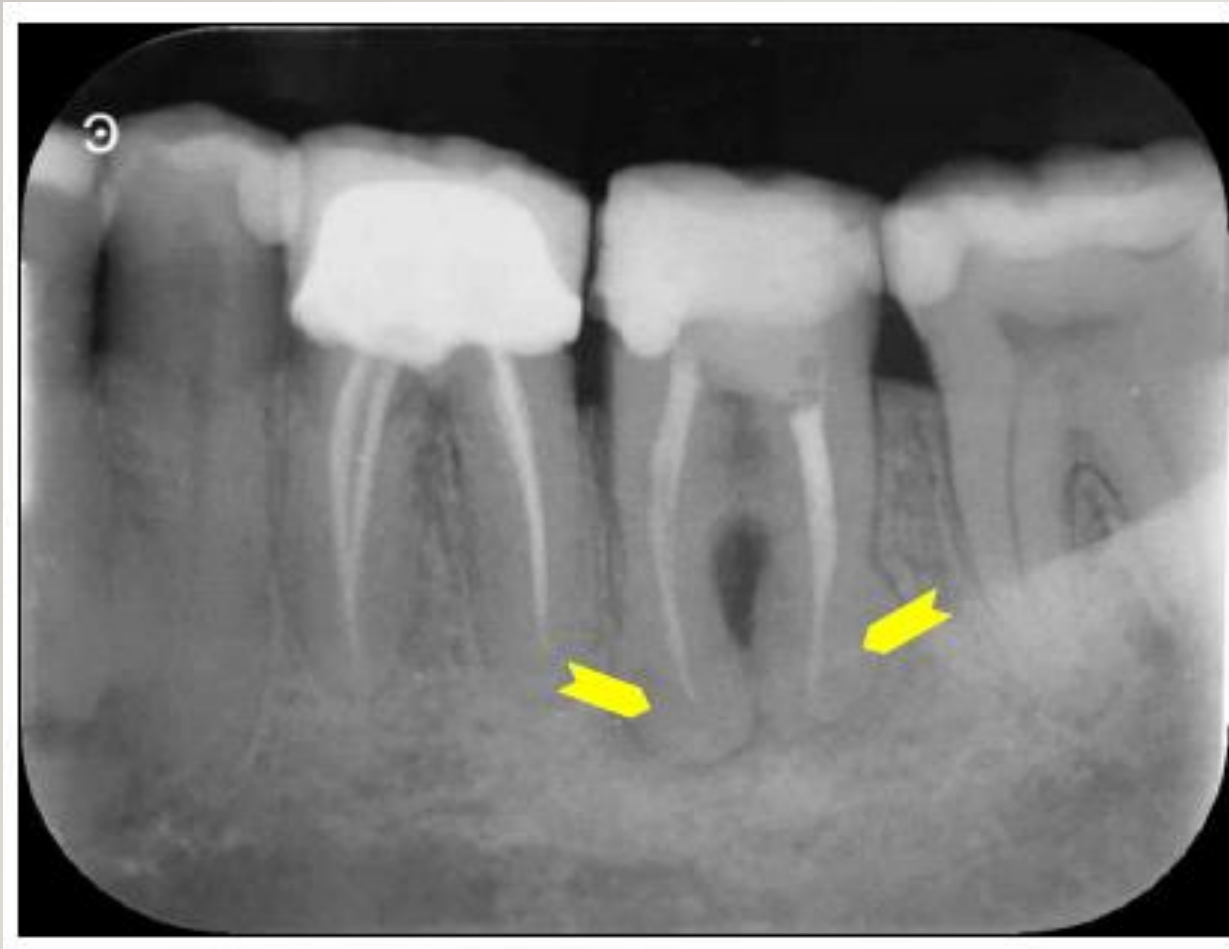
A

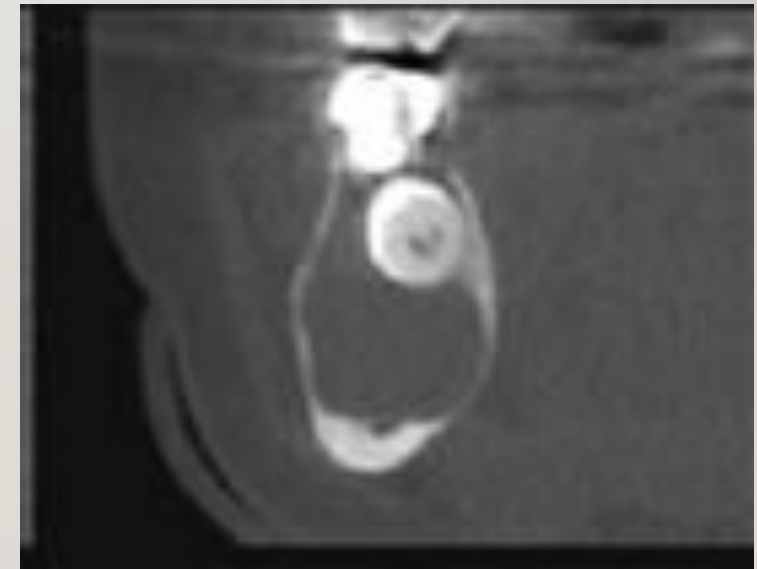
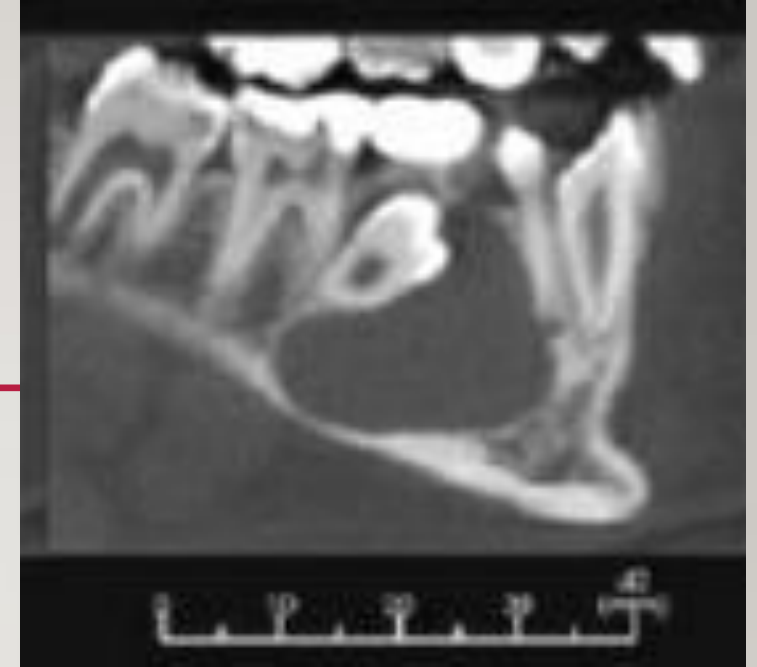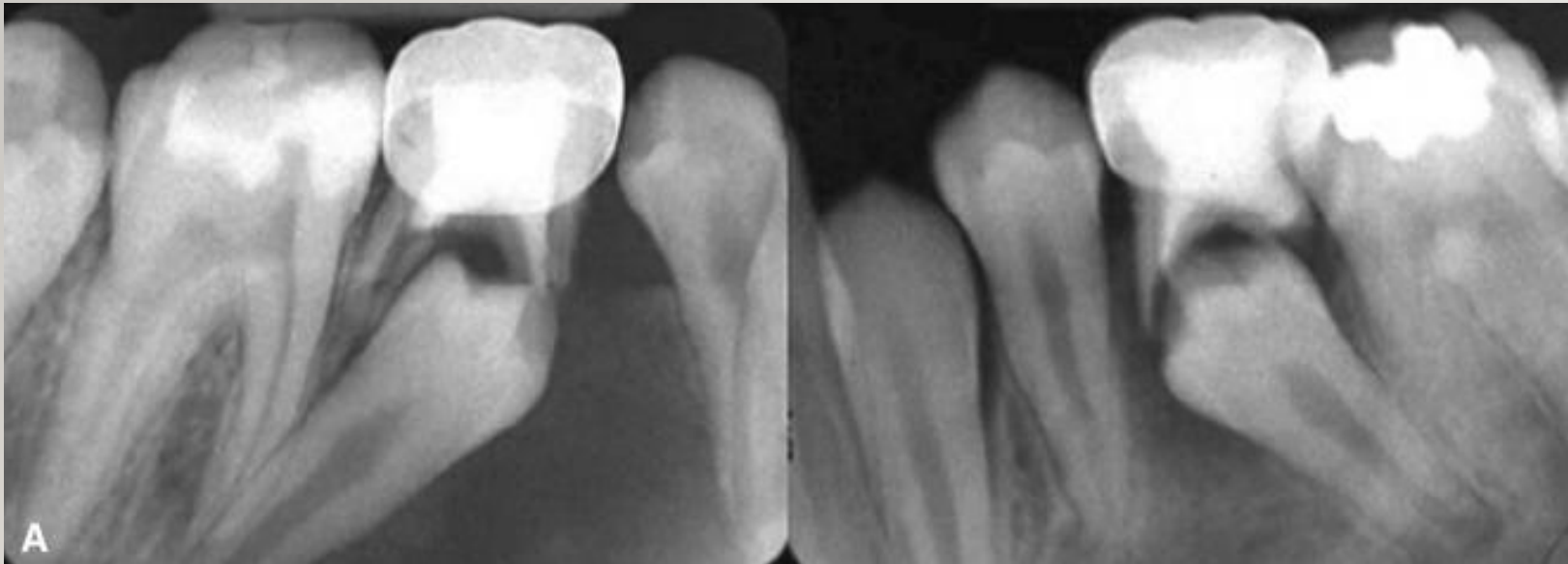


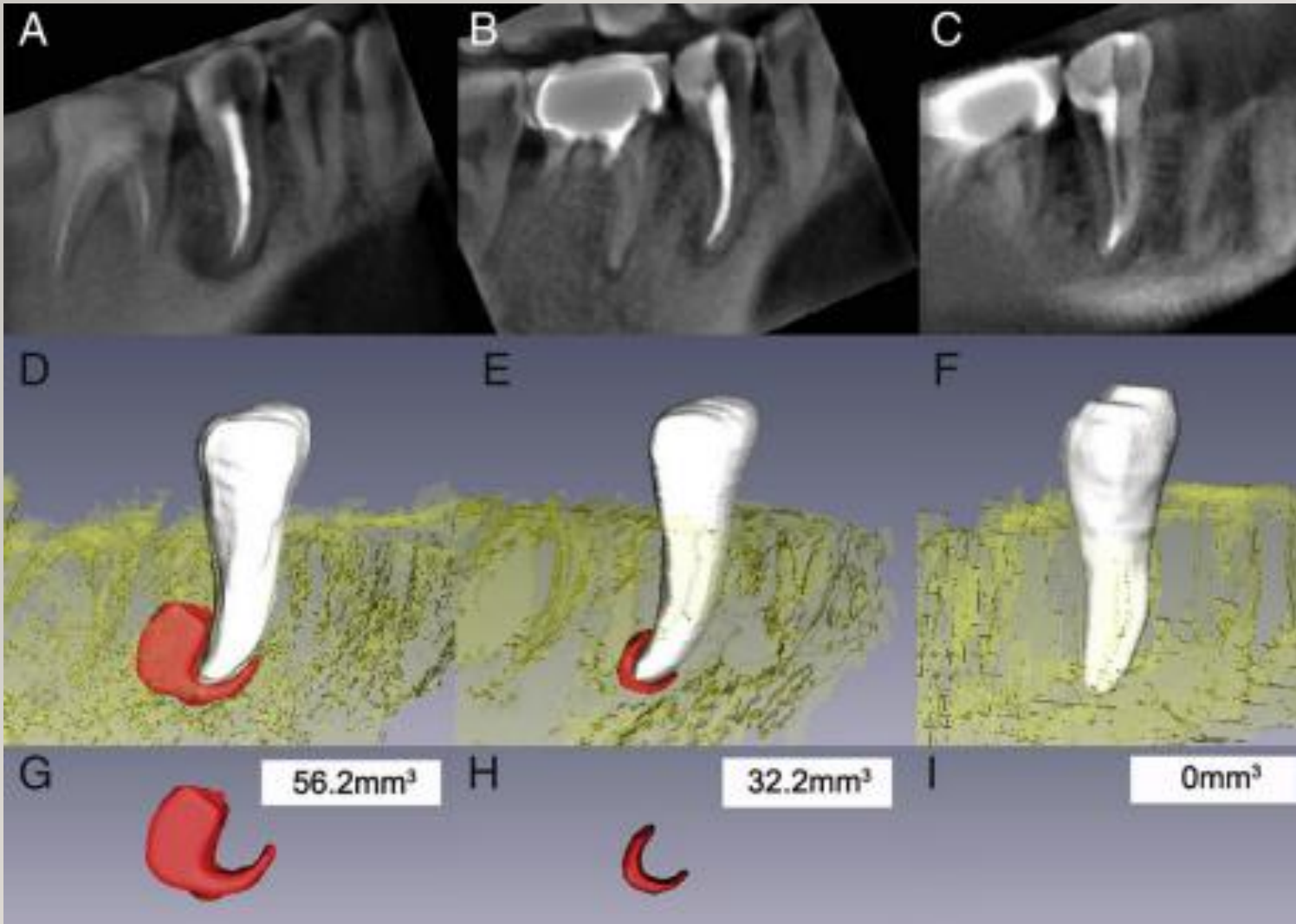
Inflammatory lesion
related to a lateral canal

Hypercementosis / External root resorption

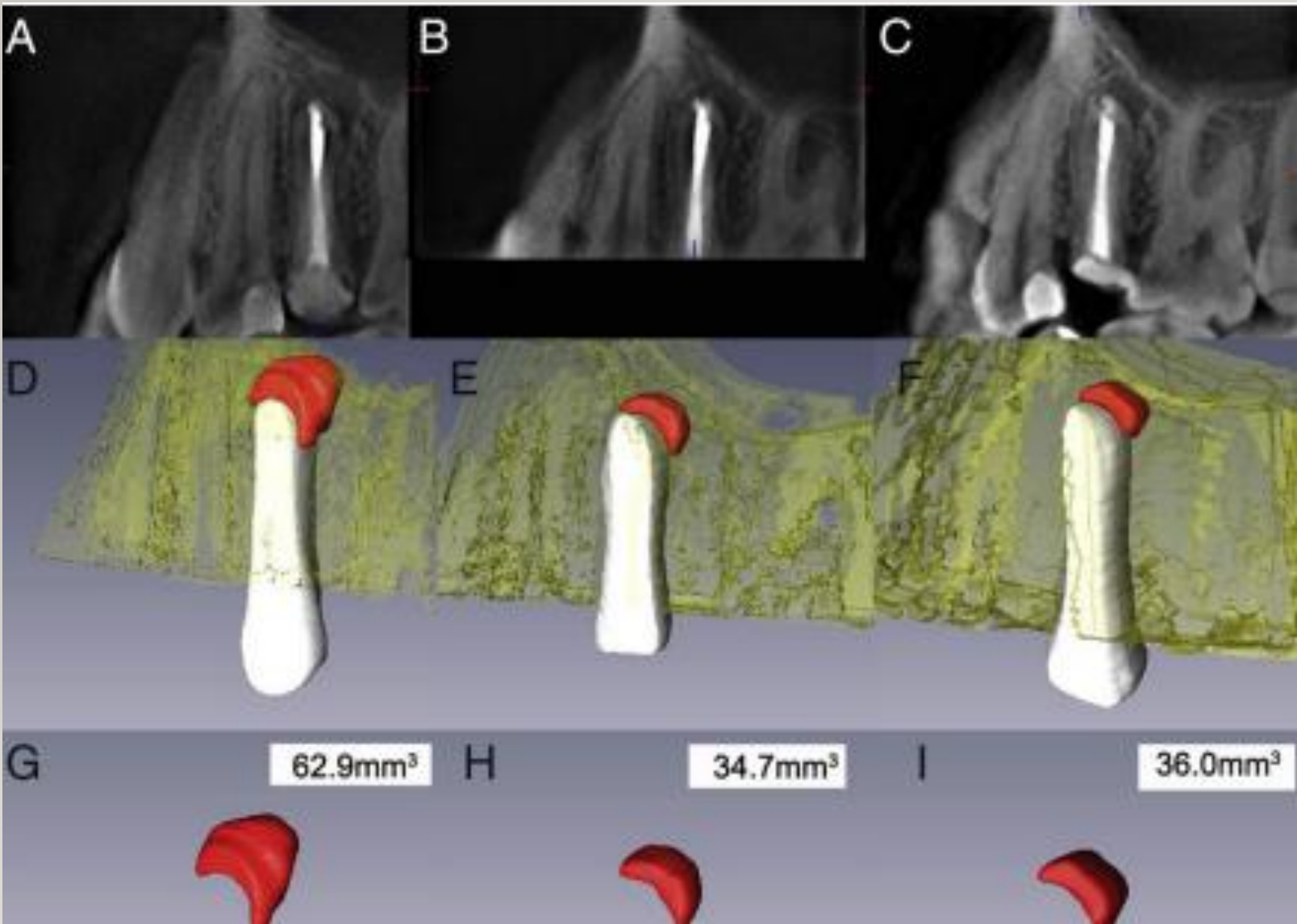


Disruption of permanent tooth eruption



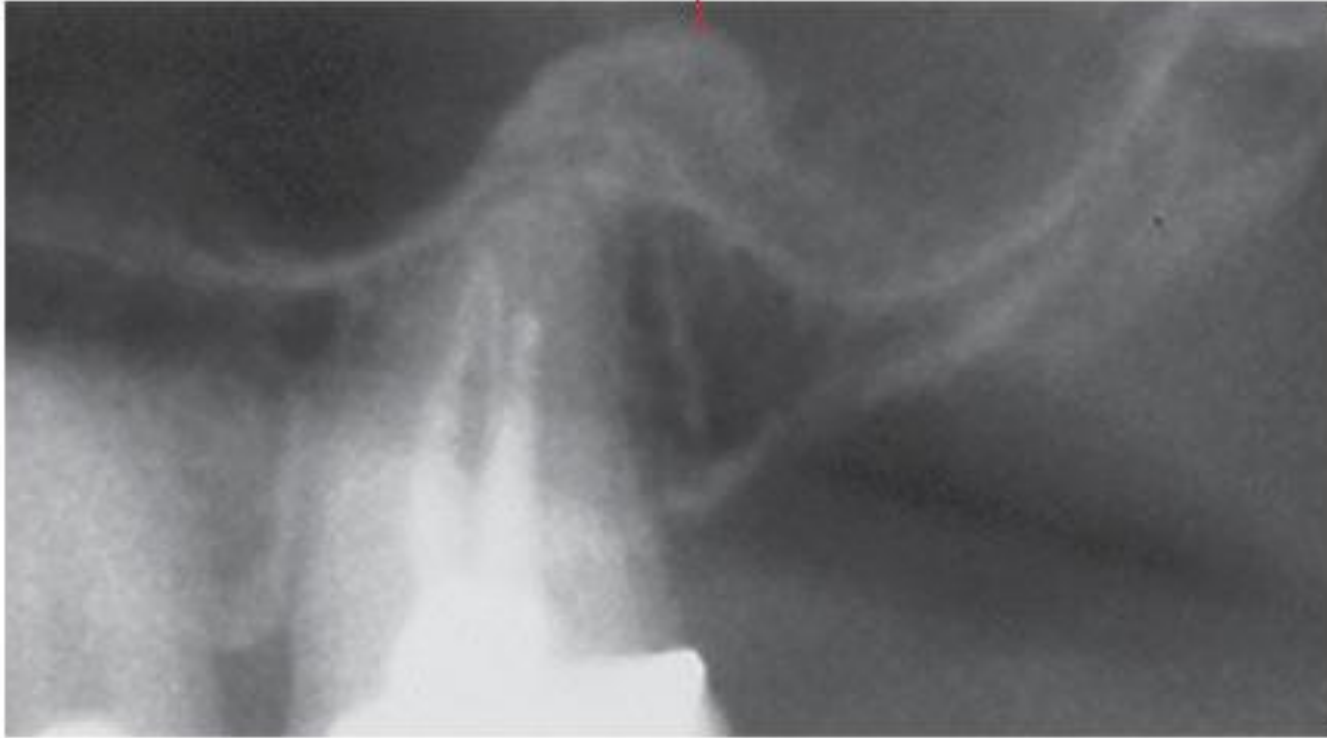

Periapical Lesion **After** Endodontic Treatment

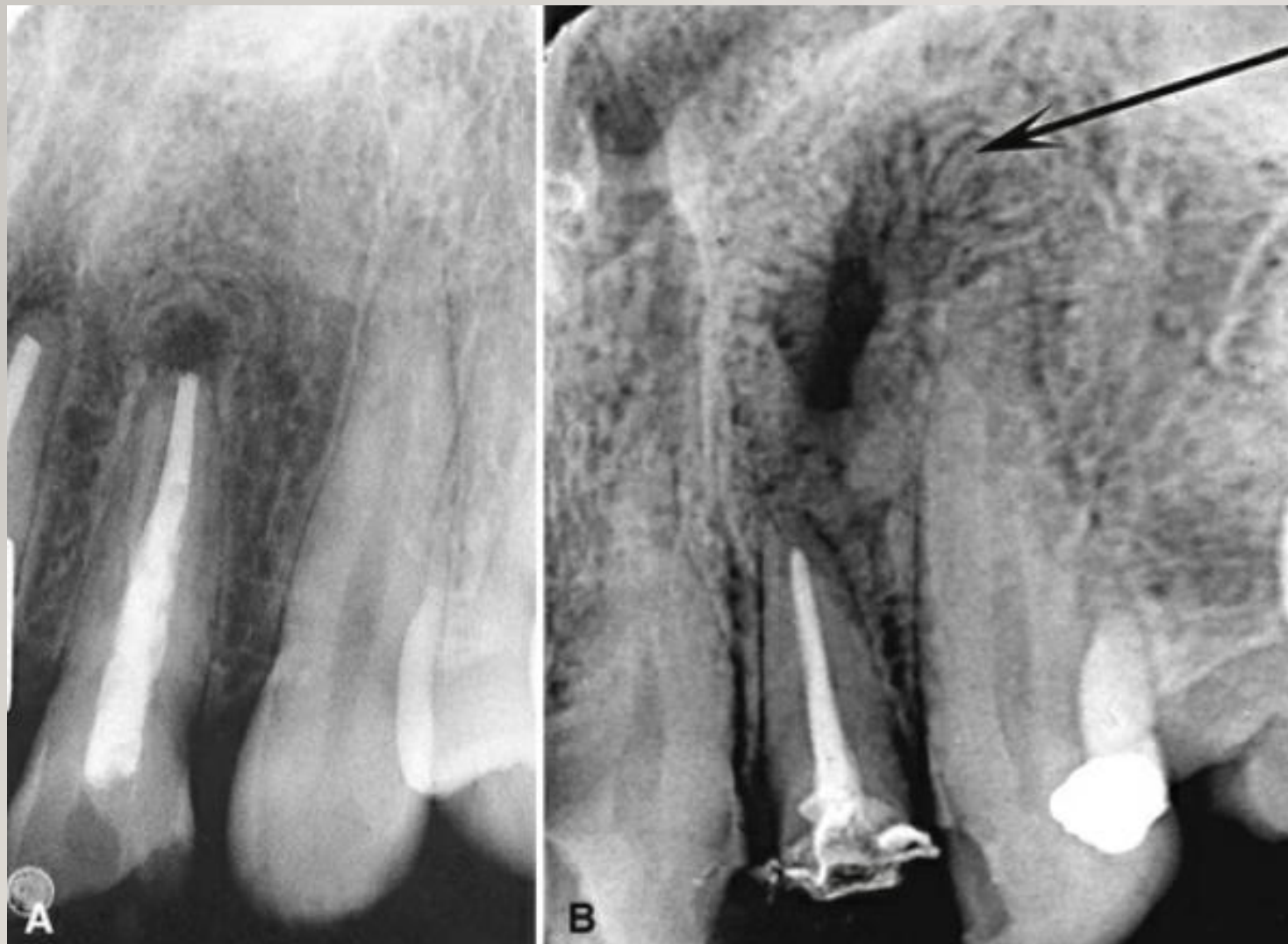

**Periapical Lesion After
Endodontic Treatment**

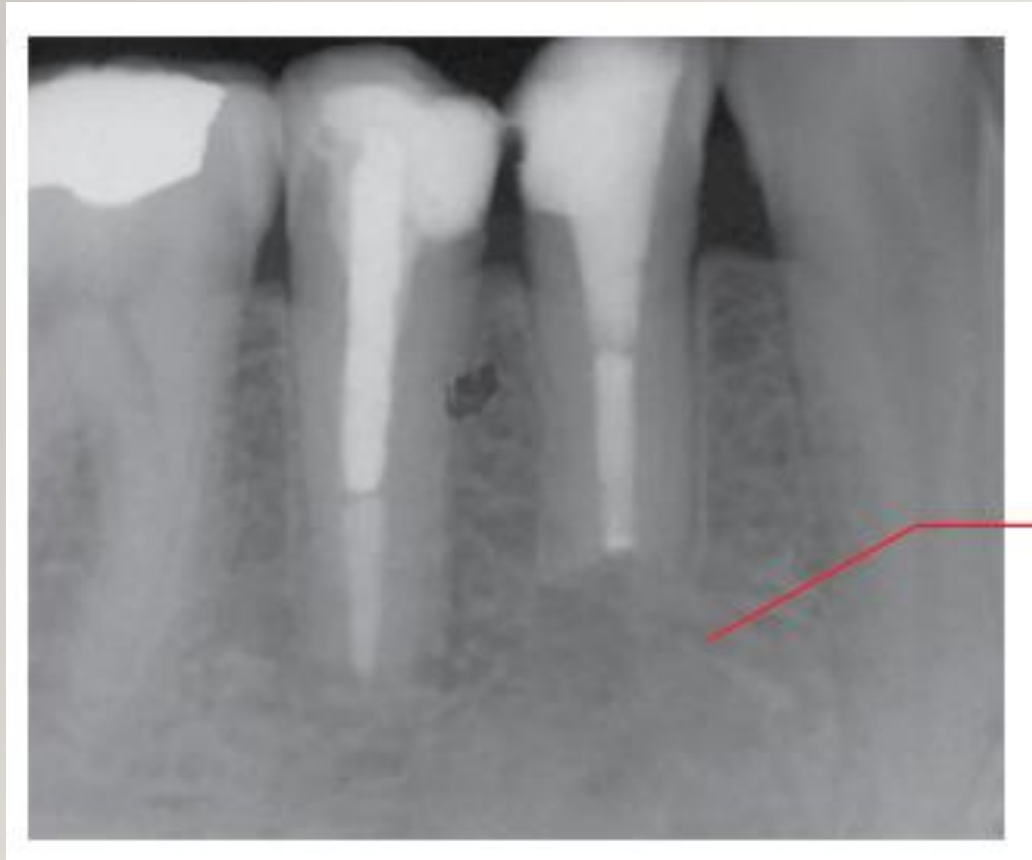
A



Postendodontic therapy
healed apical lesion



Fibrous scar

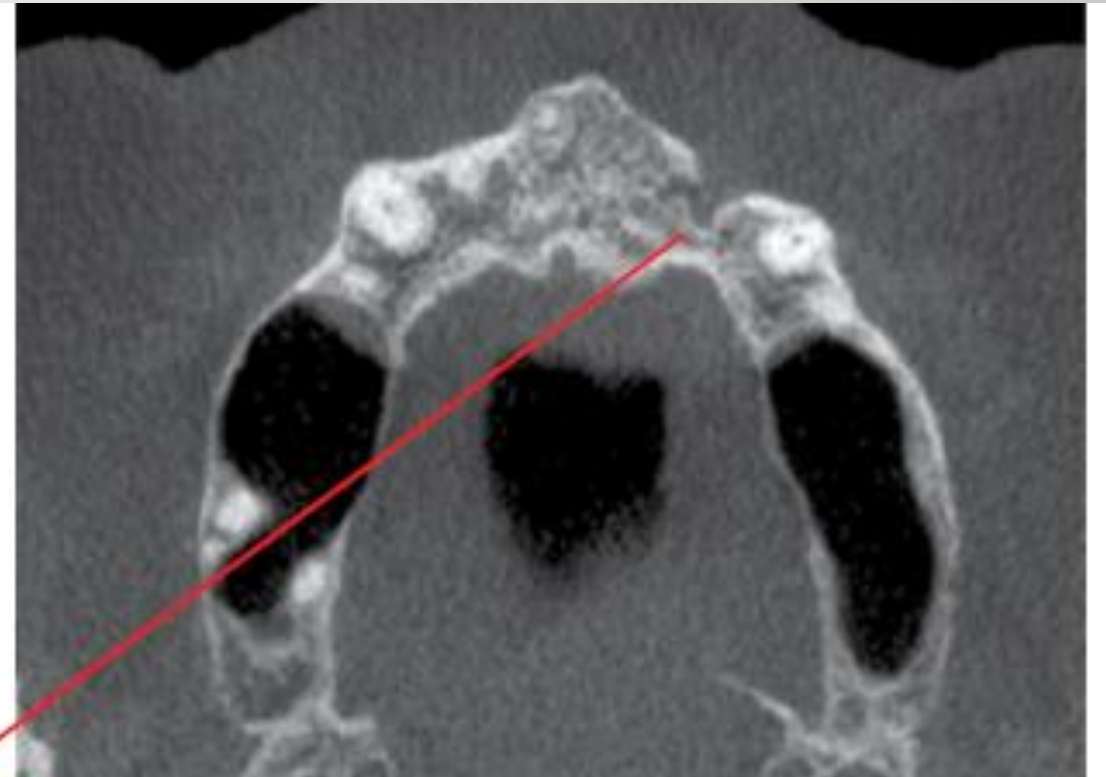
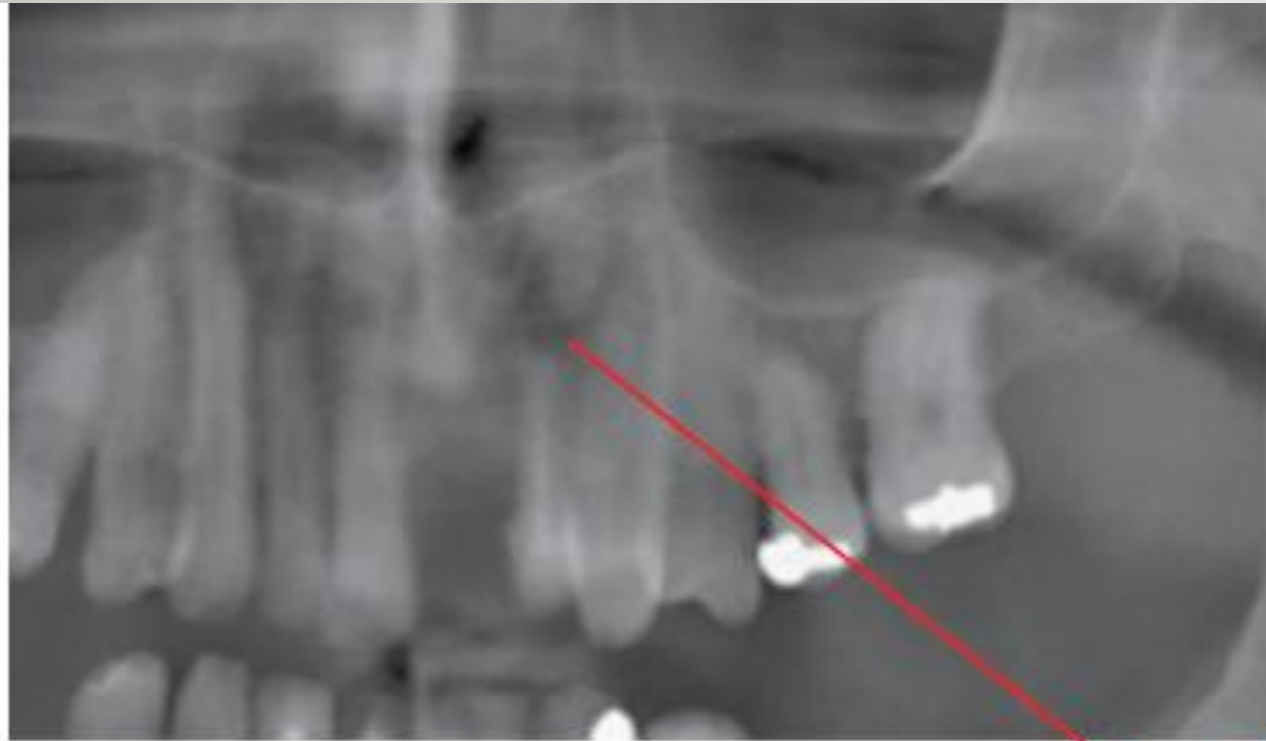

Post endodontic therapy

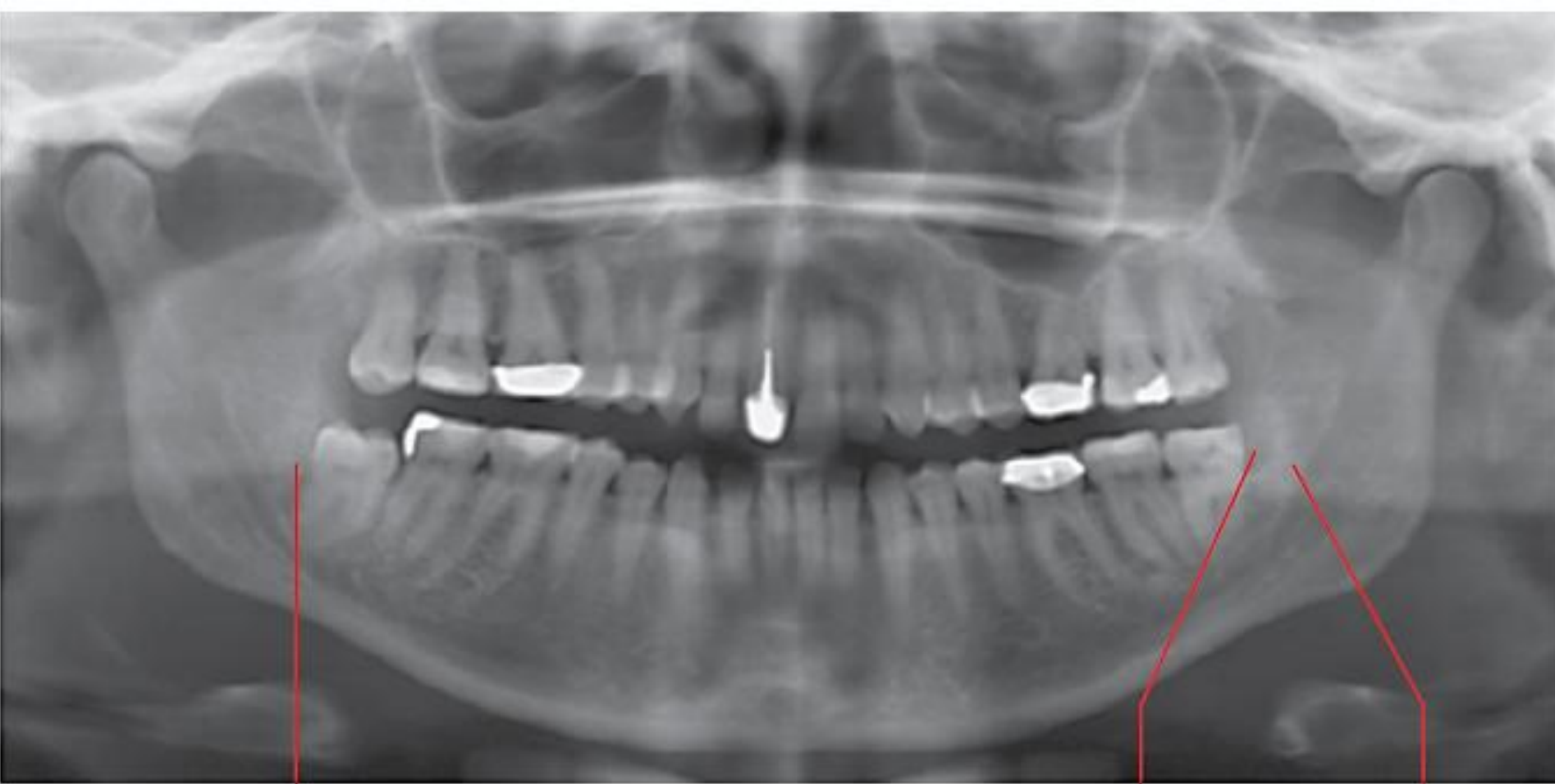healed apical lesion

A

Postendodontic therapy **healed** apical lesion



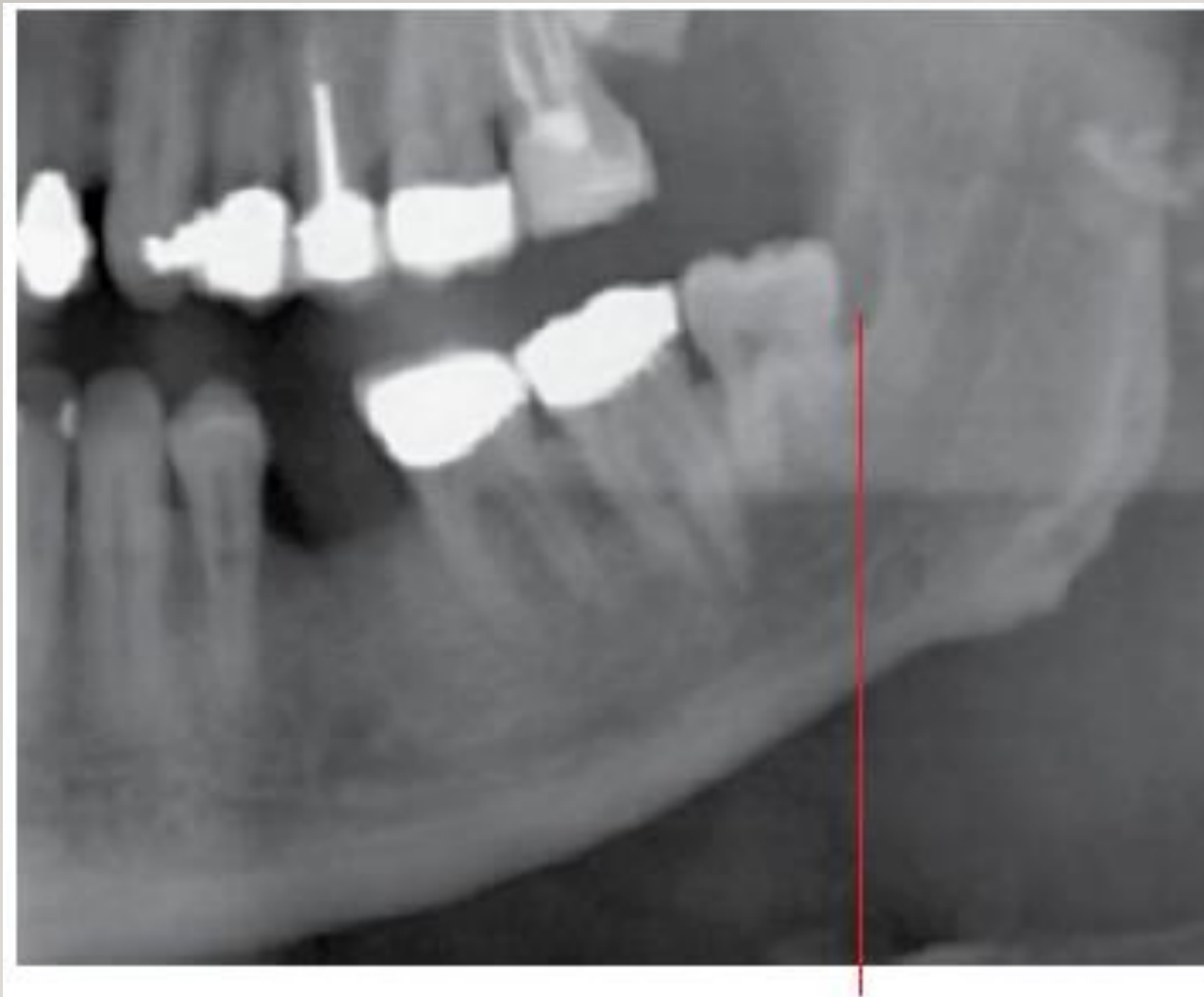Chronic pericoronitis



A

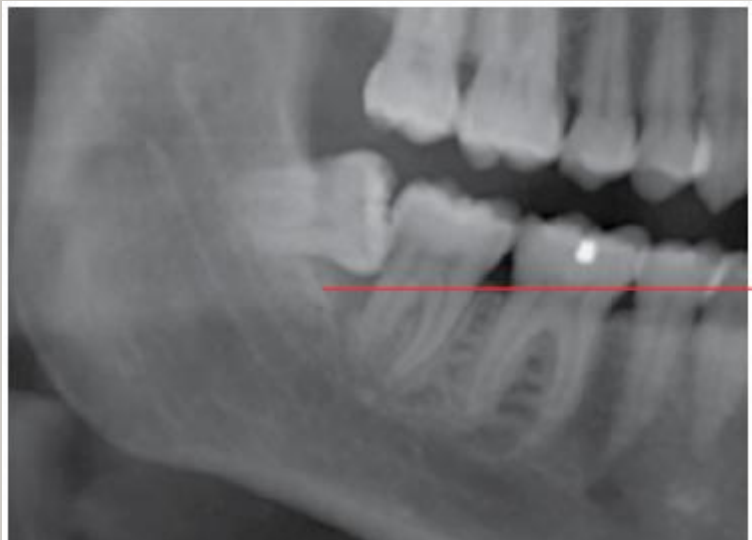B

C



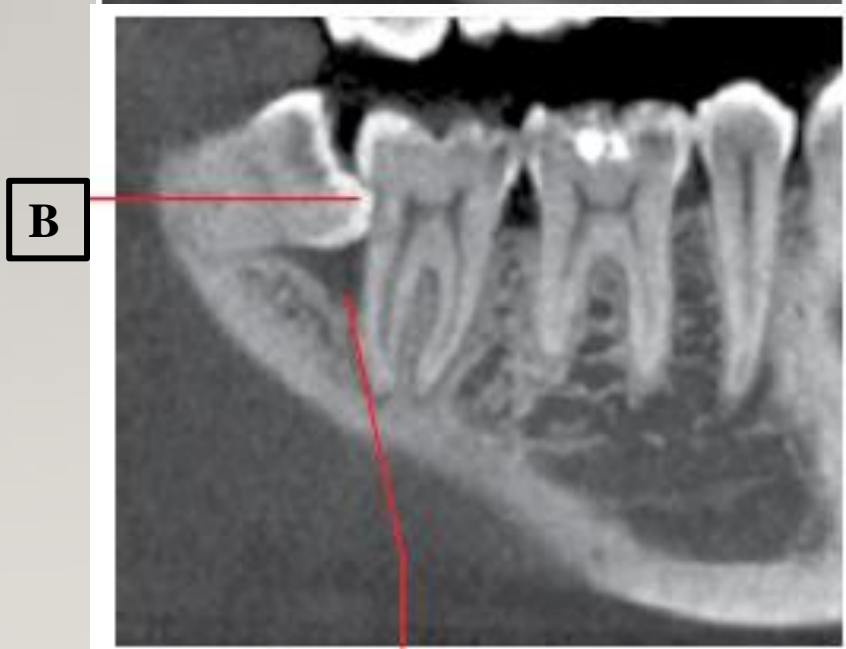Chronic pericoronitis

A



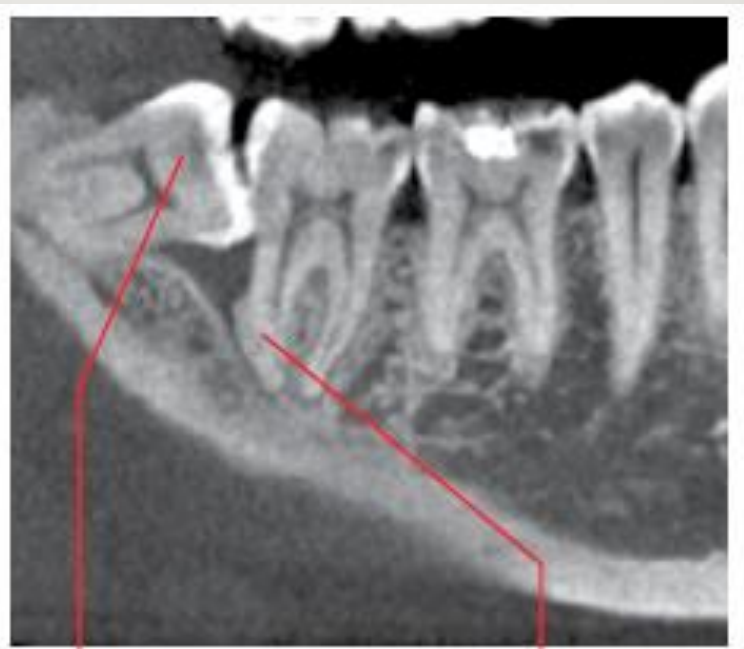A

Chronic pericoronitis



B

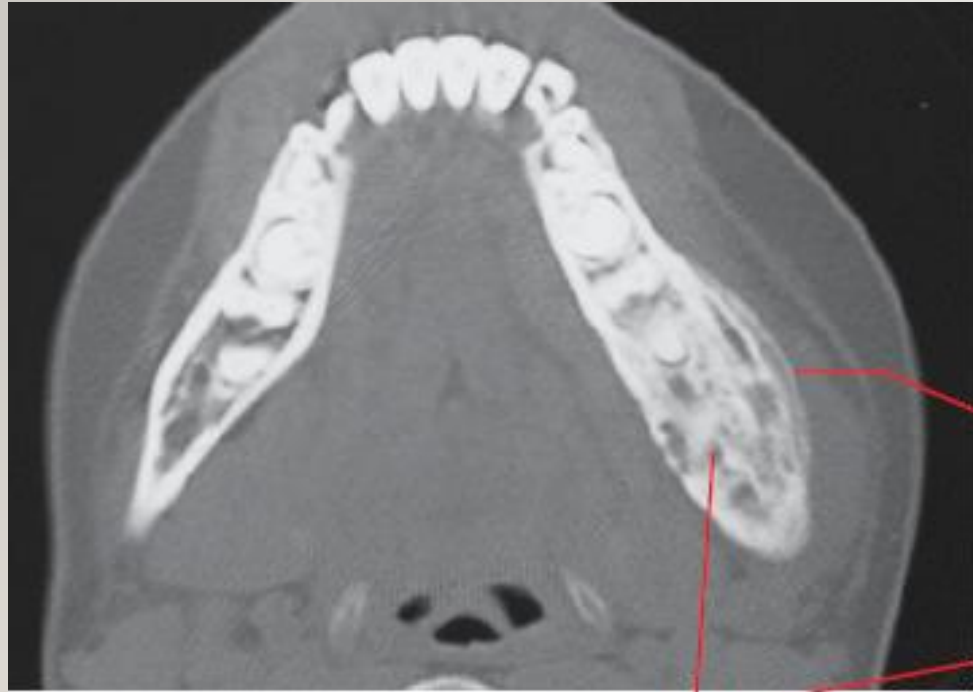C



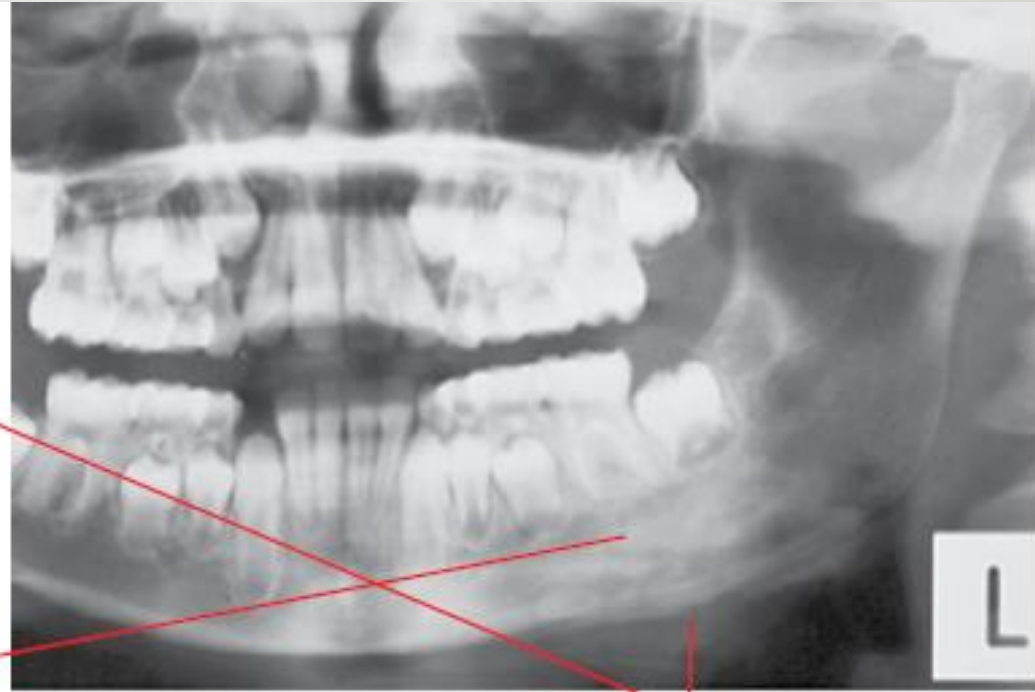D

E

Chronic Osteomyelitis

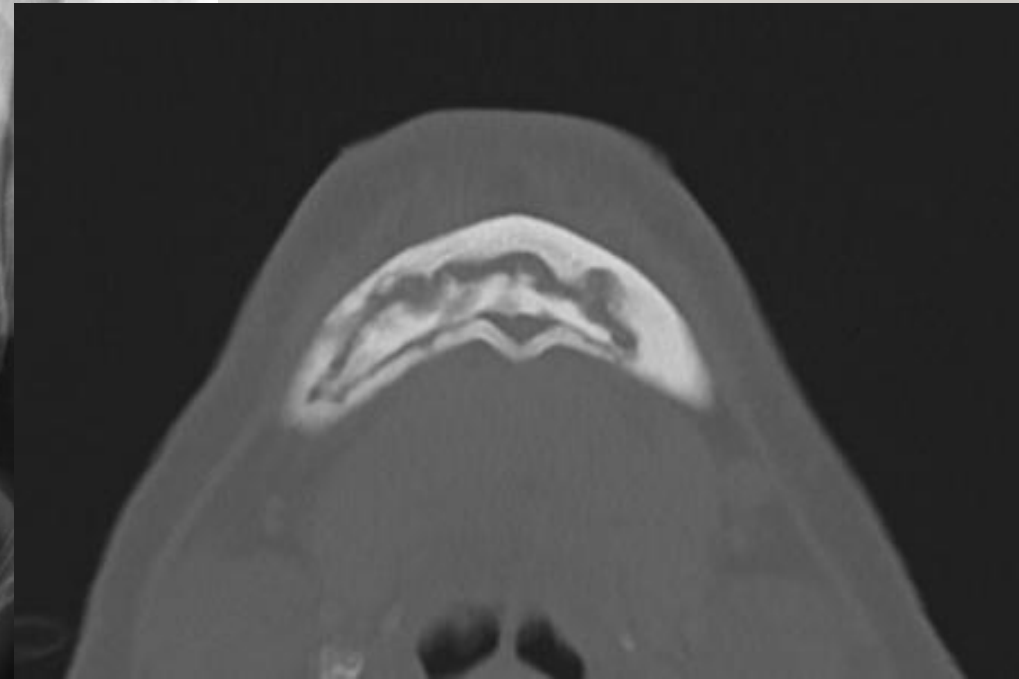
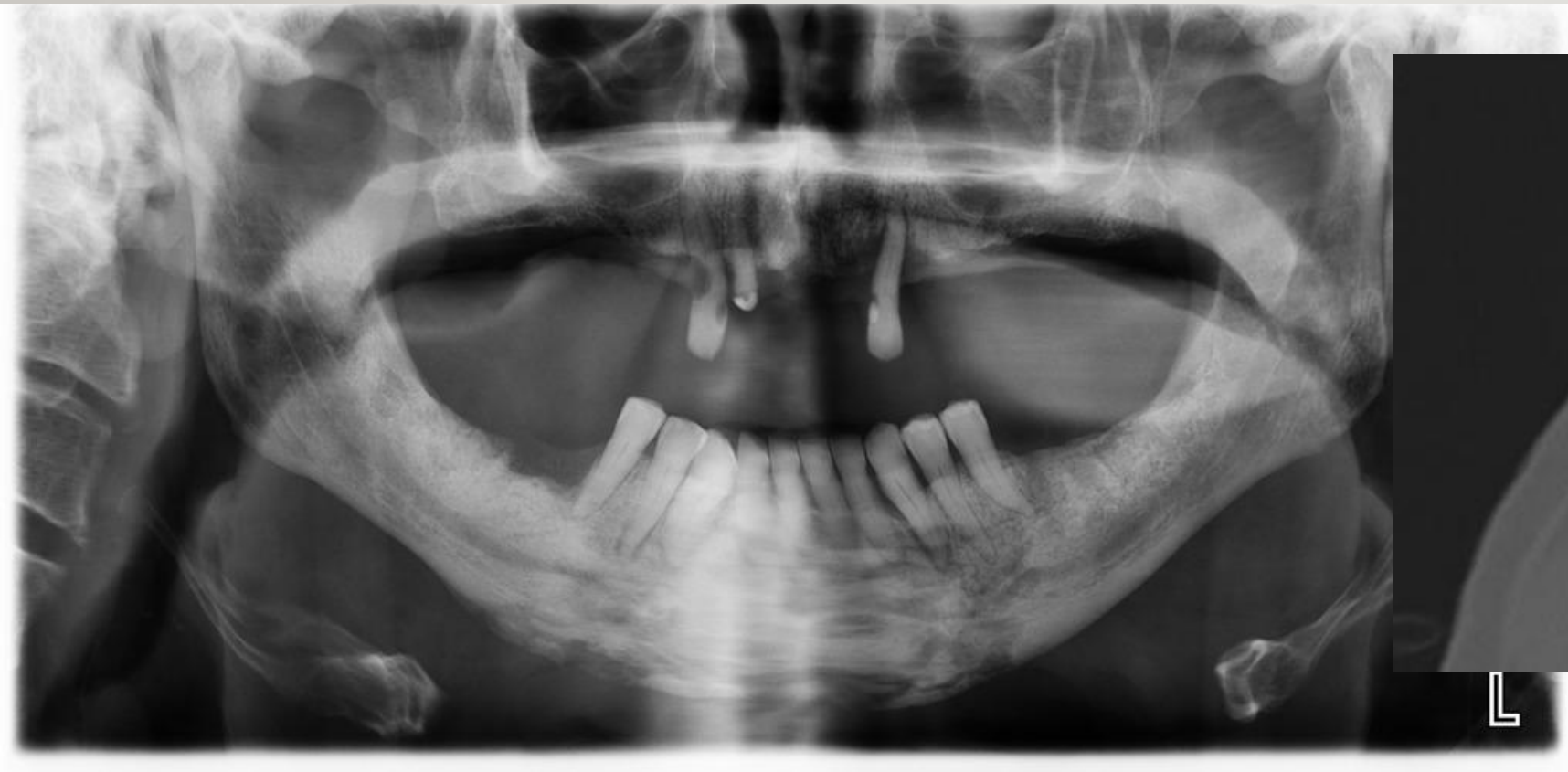

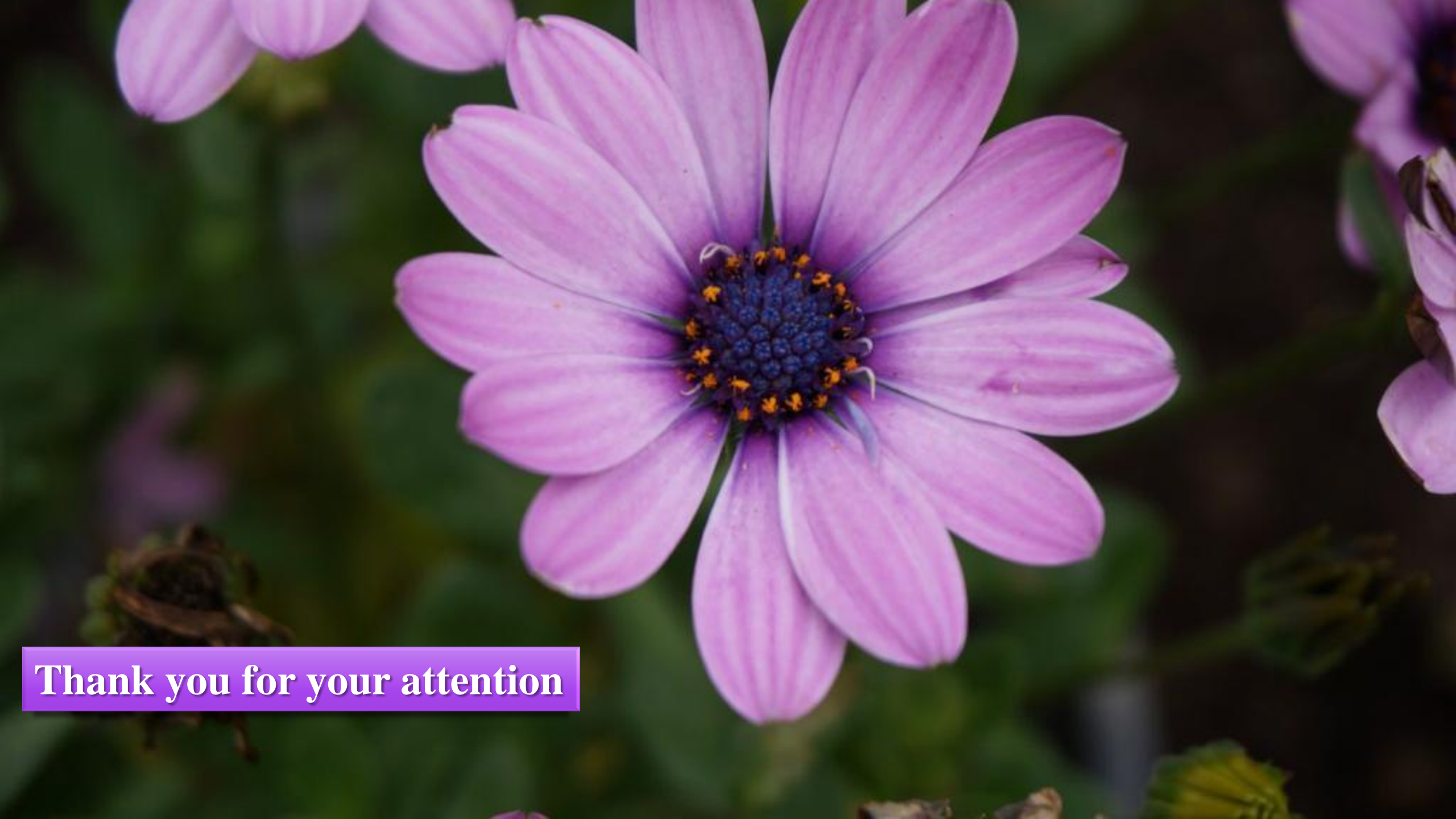A



B

Chronic Osteomyelitis





Thank you for your attention