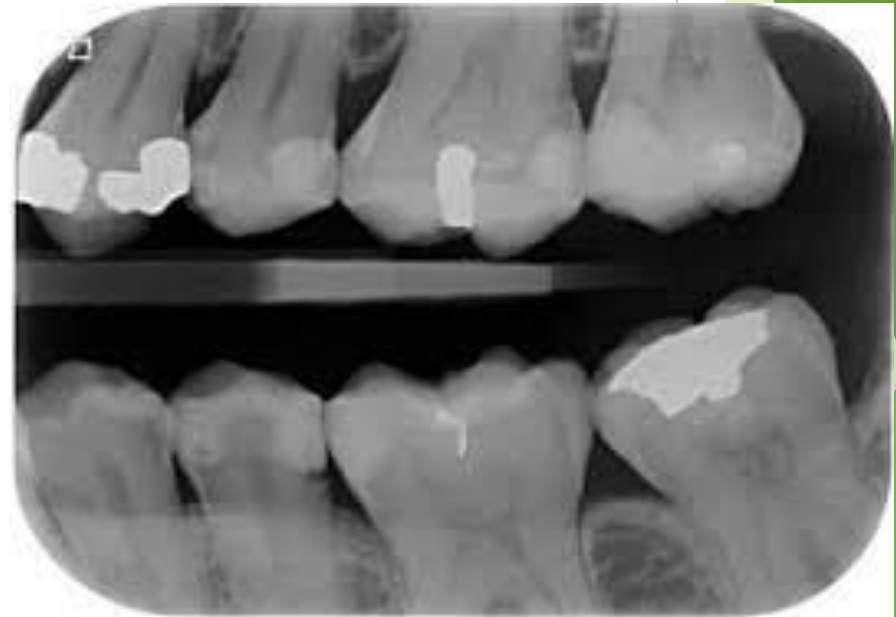
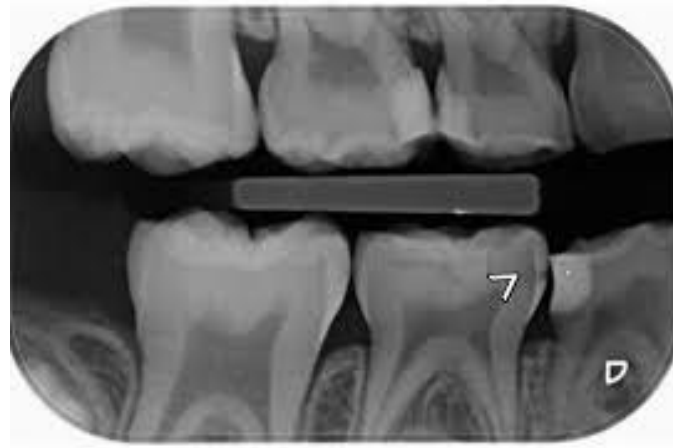
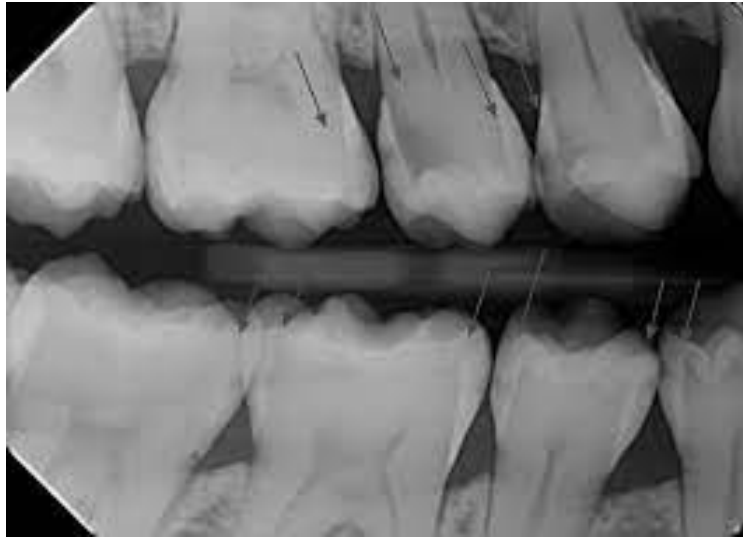
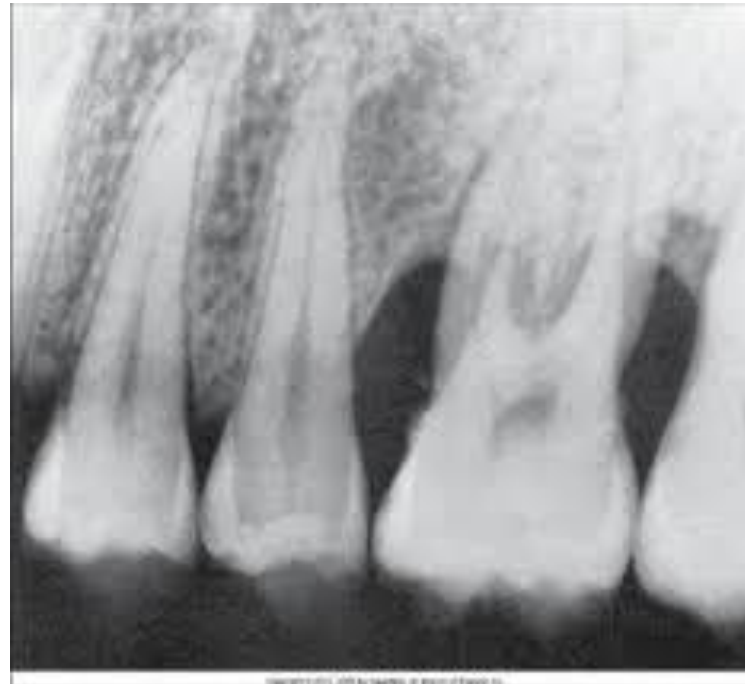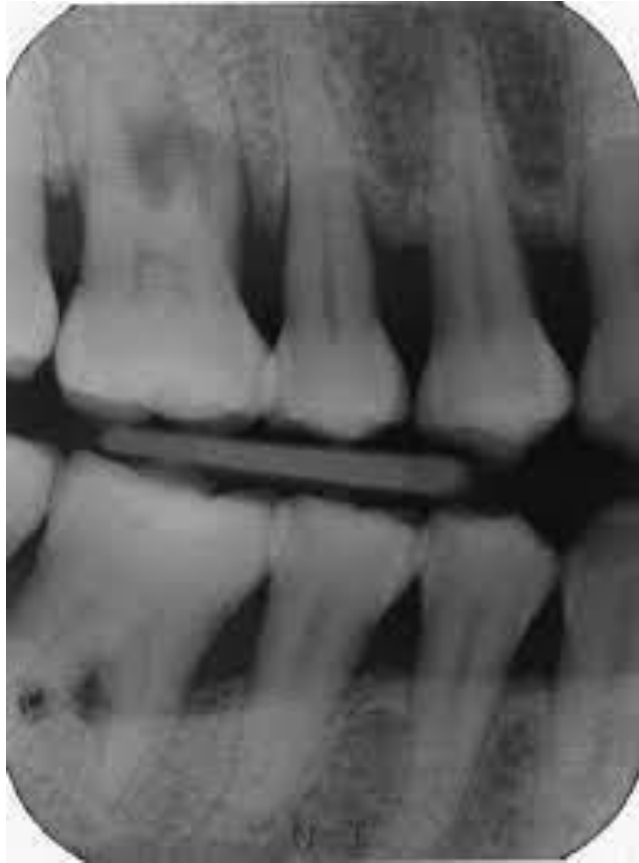Prescribing Diagnostic Imaging

دکتر فرزانه استوارراد

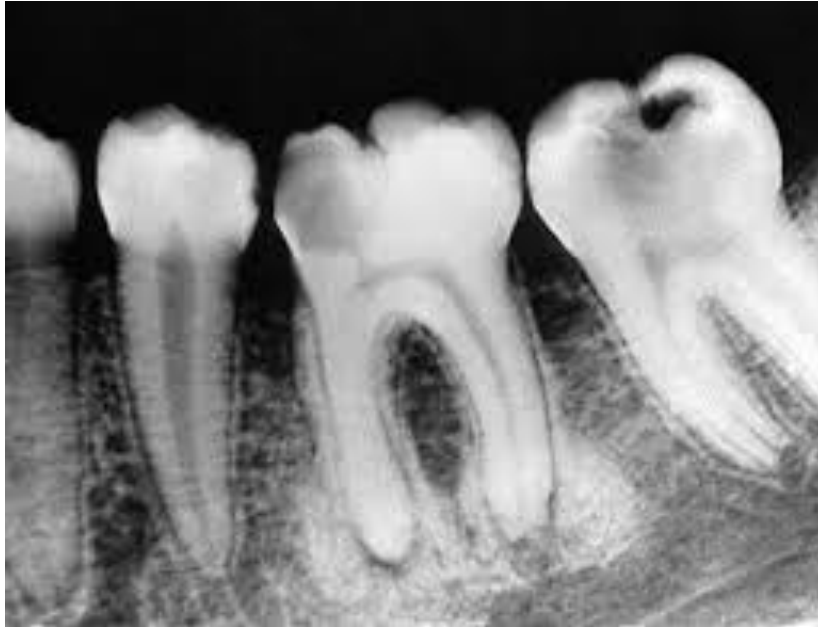caries

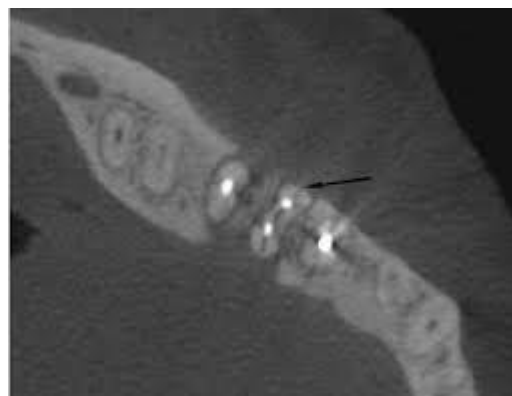
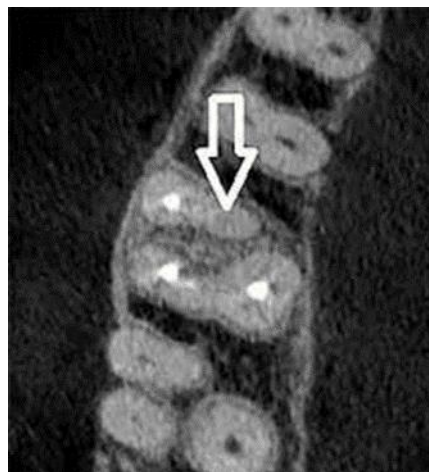
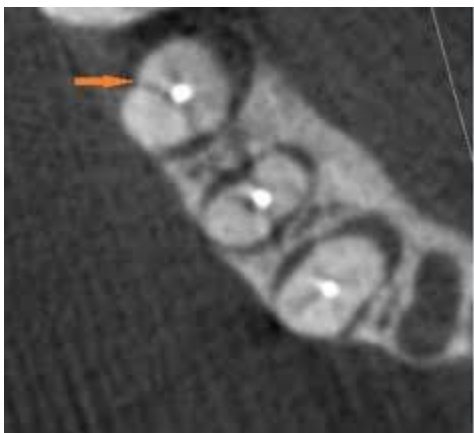Periodontal diseases

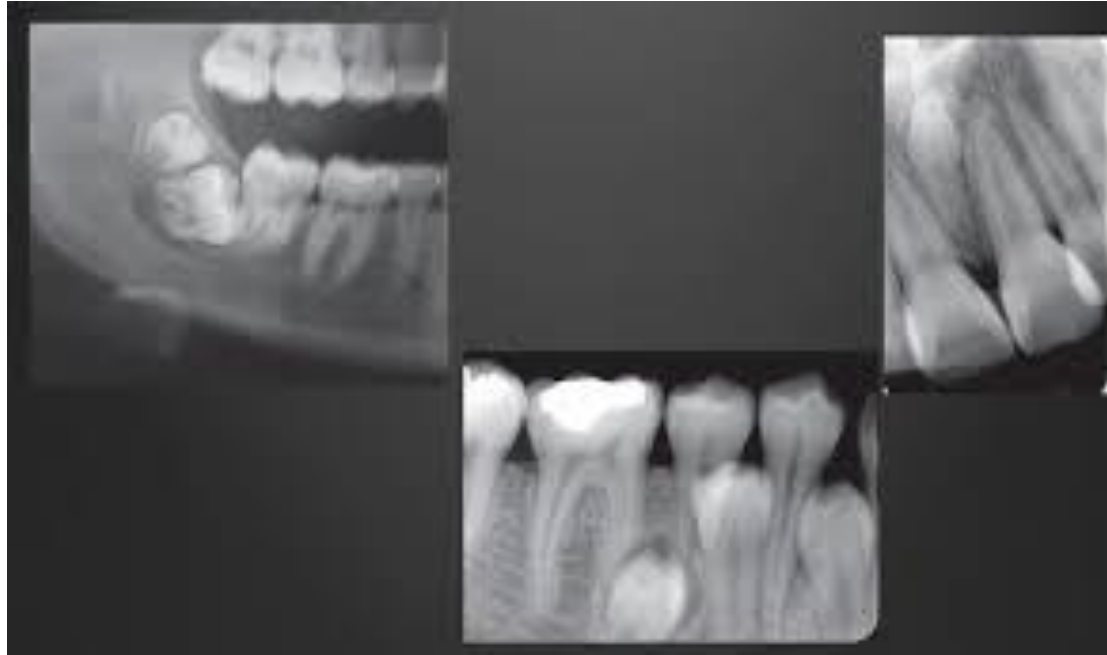

Periapical Inflammatory Disease

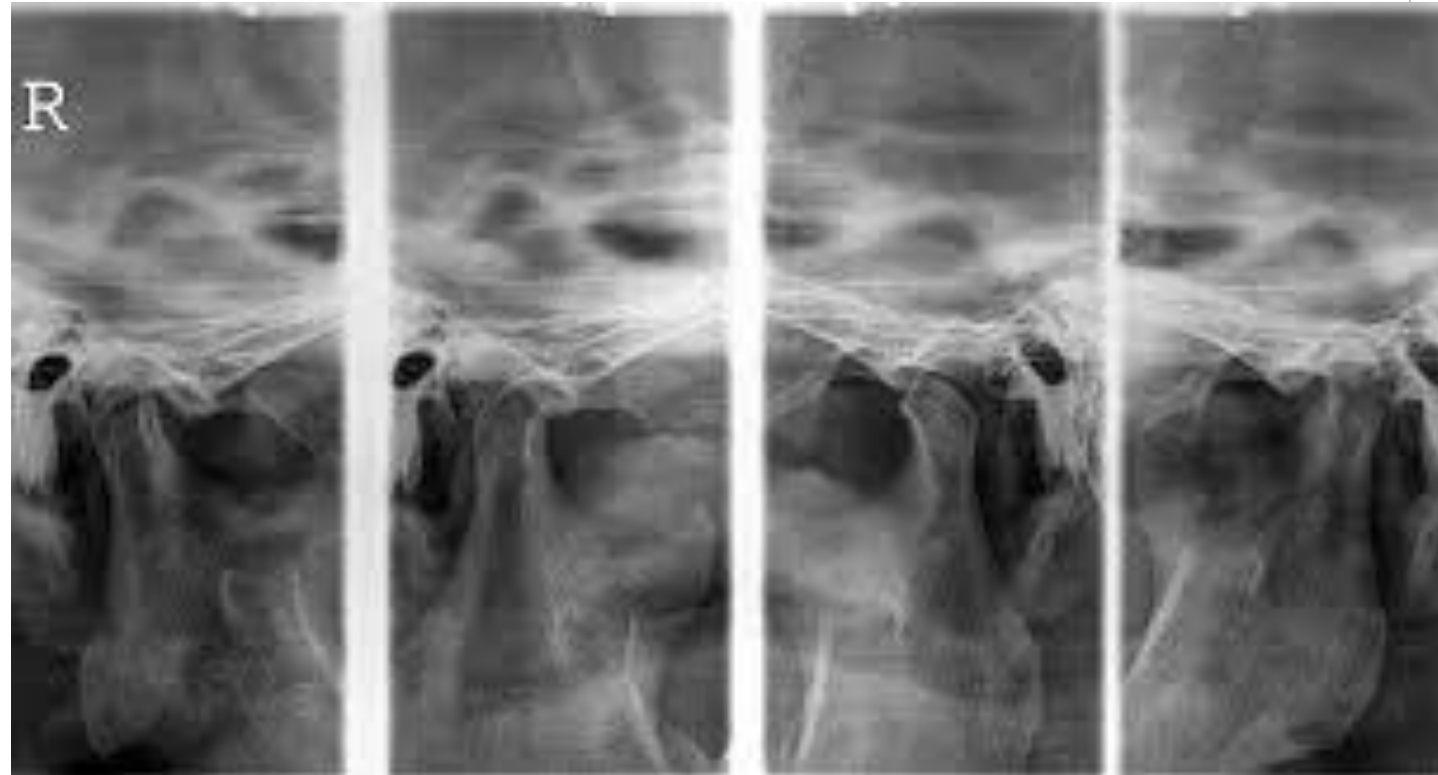



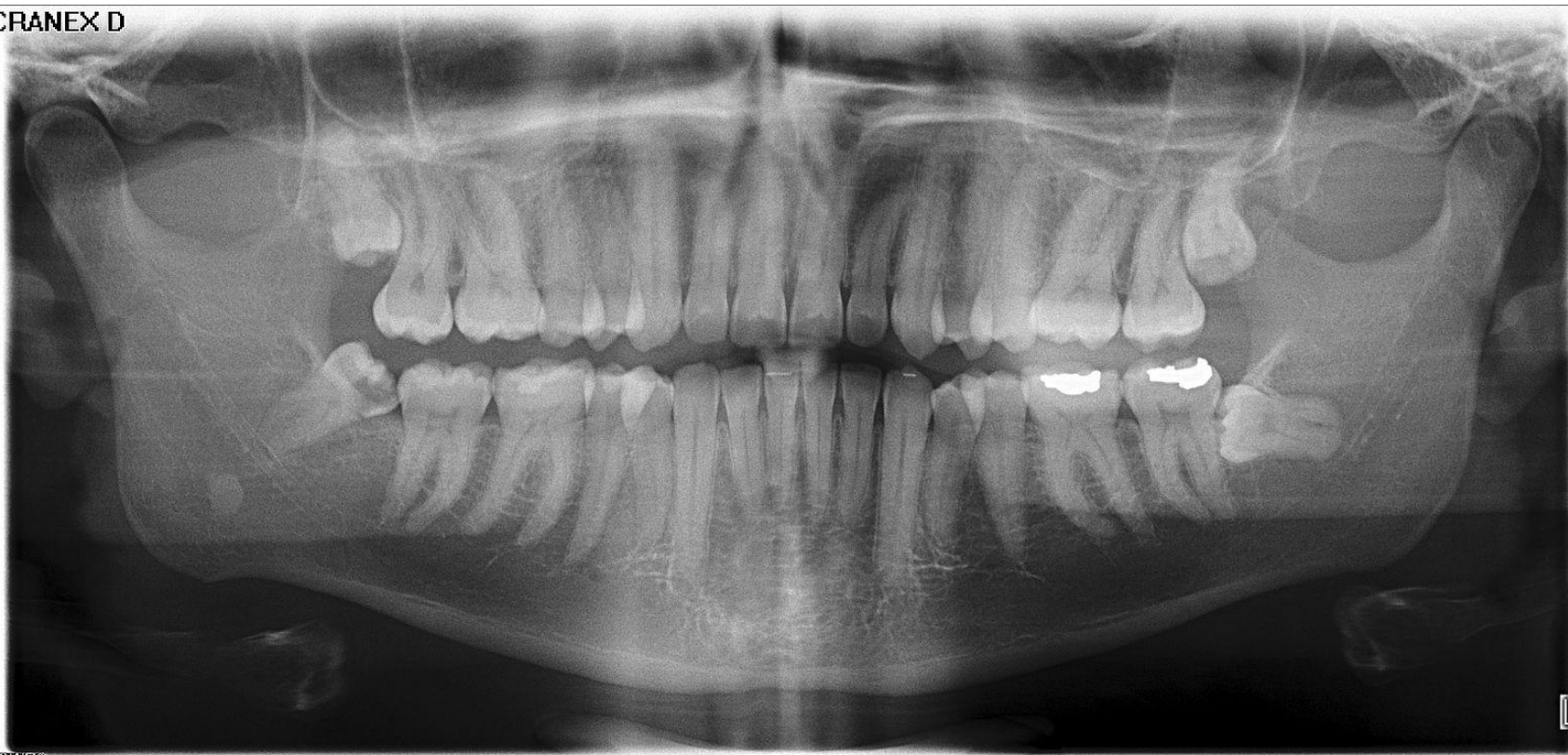Dental Anomalies



TMJ



CRANEX D



02/2024

Implant

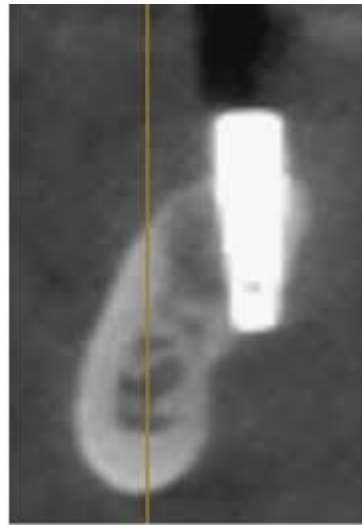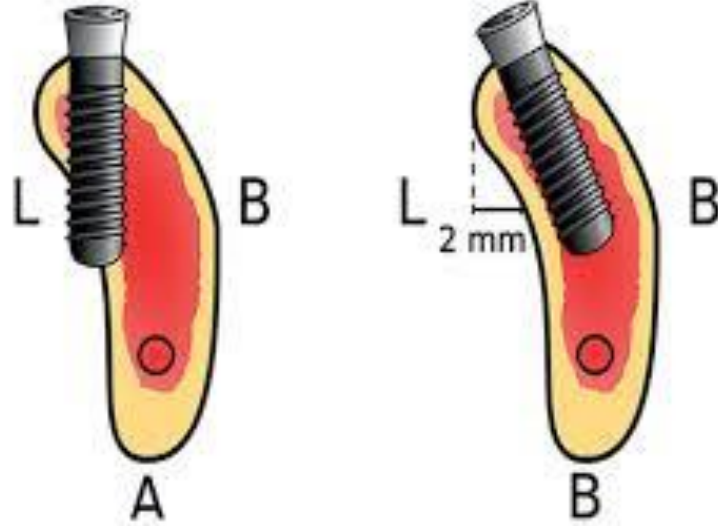
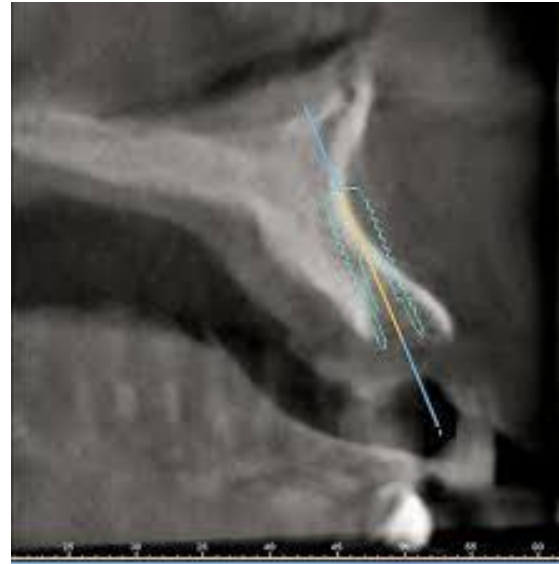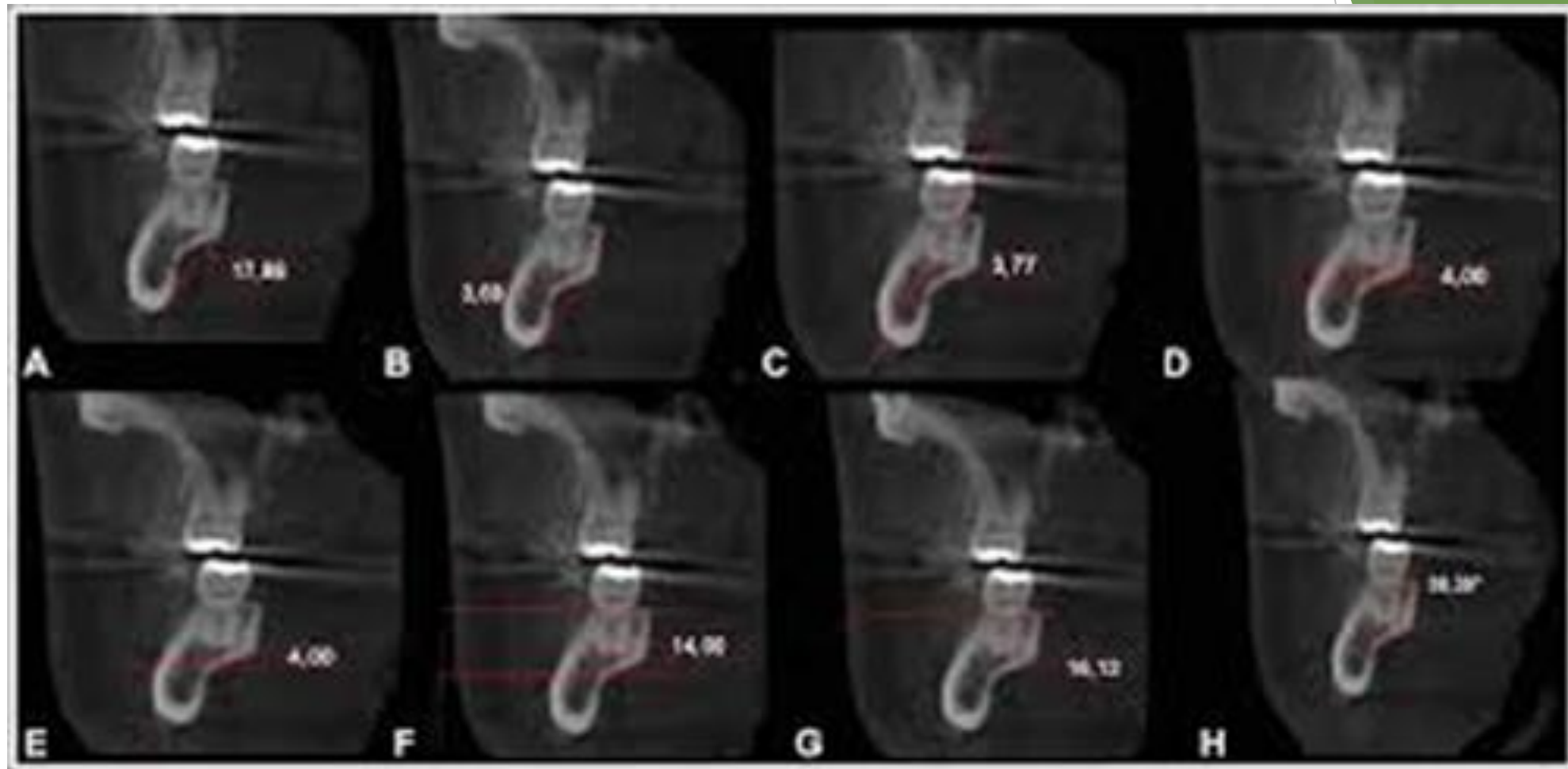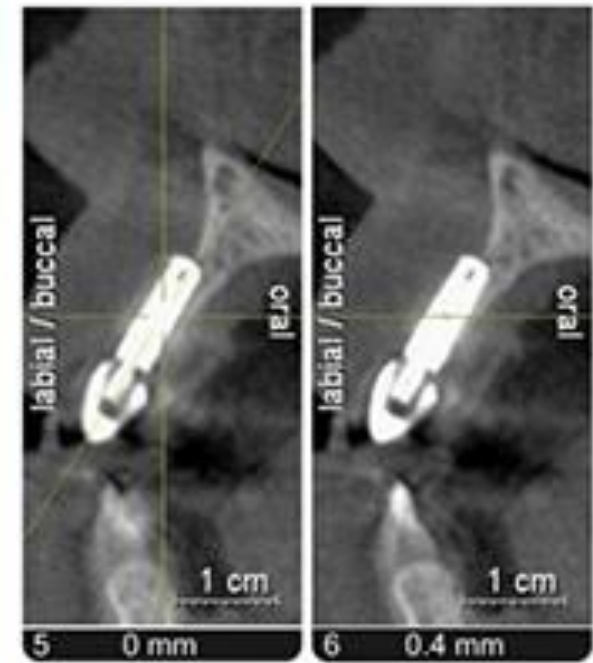


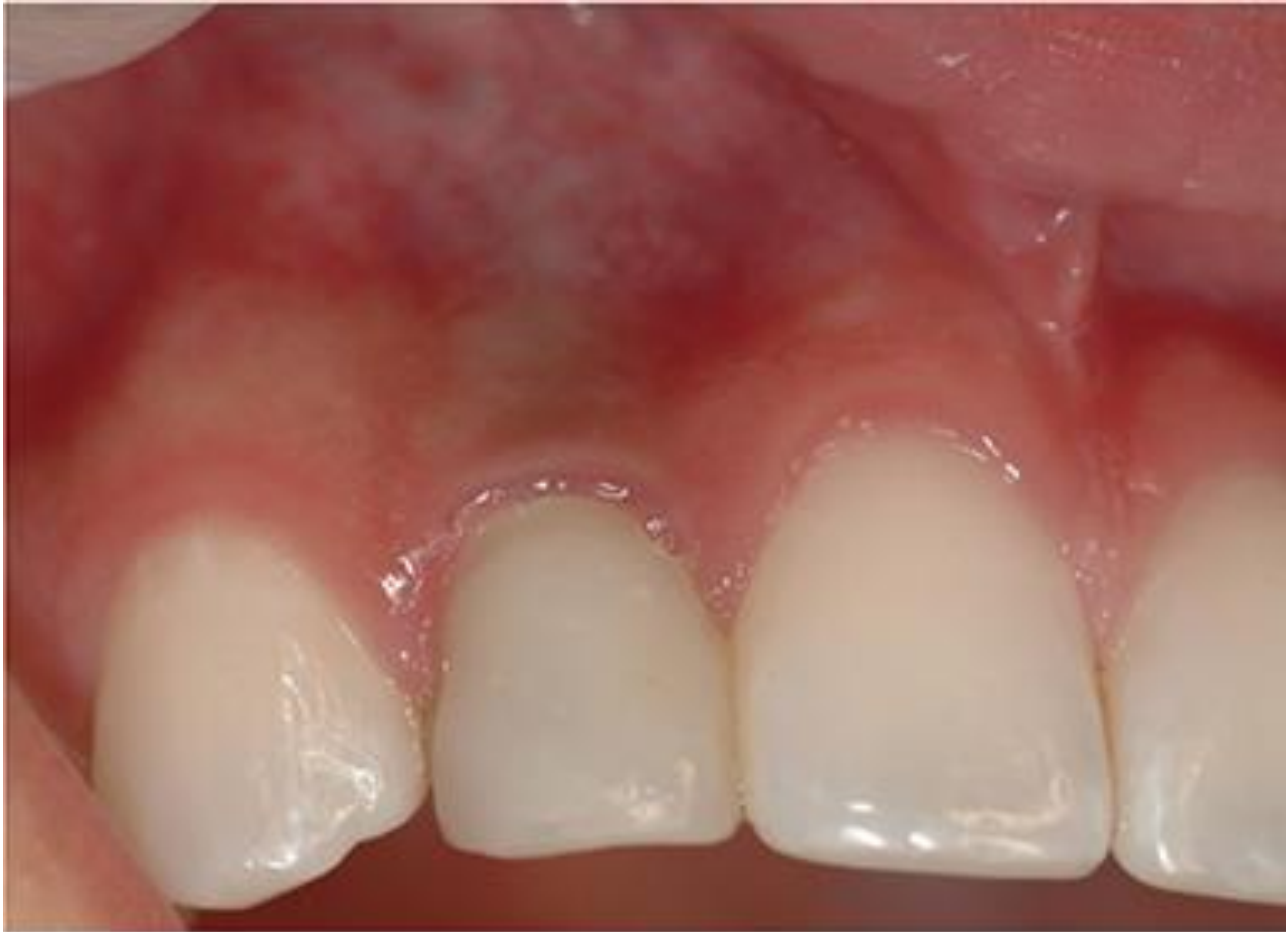Figure 1: Anteroposterior (AP) radiograph of the mandible showing the implant.







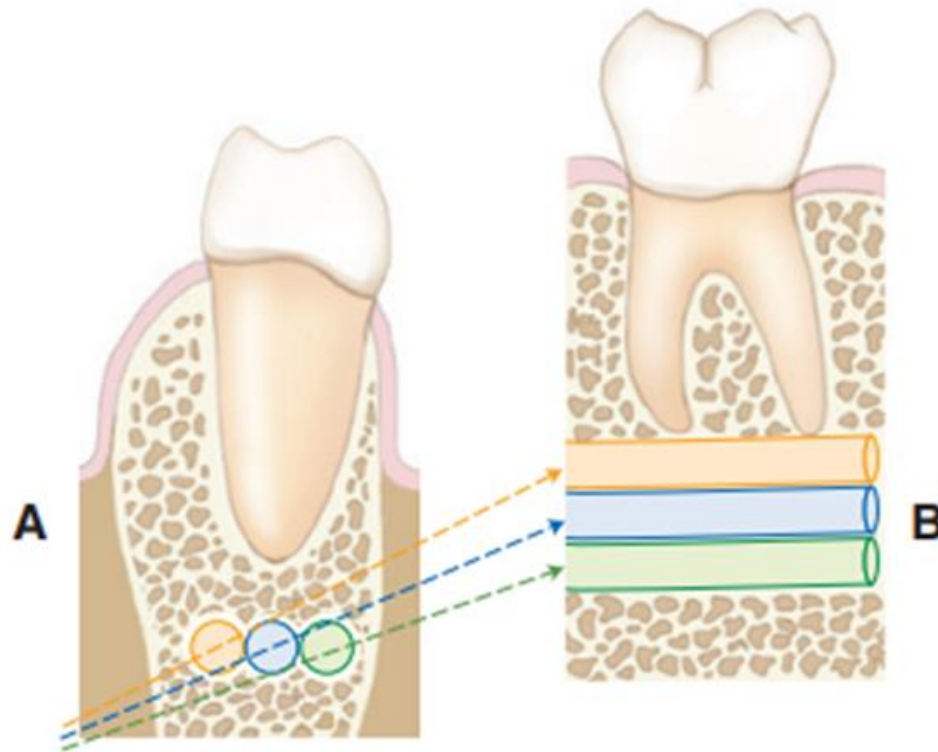
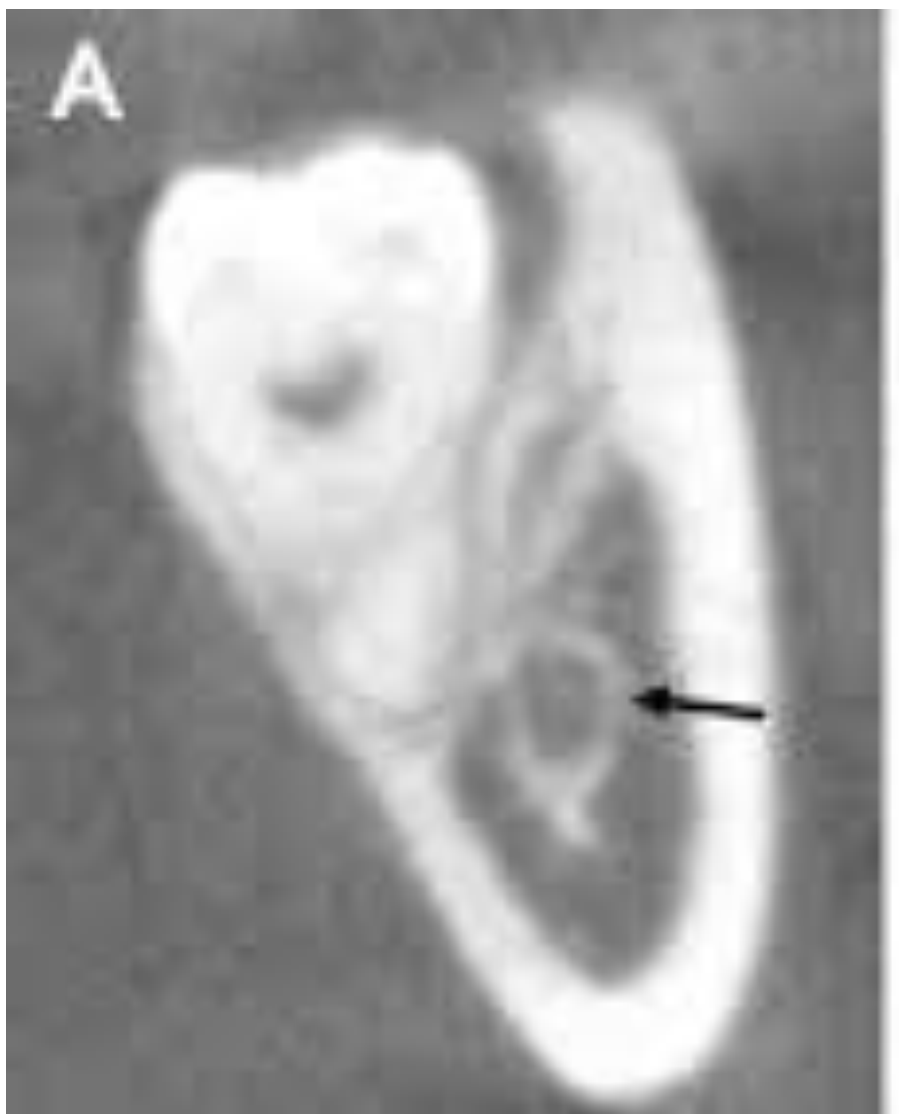


Fig. 9.12 Influence of projection geometry on spatial relationships in the vertical dimension. (A) Diagrammatic representation of a coronal cross section through the mandible. Three potential locations of the mandibular canal are shown. The locations lie in the same horizontal plane but differ in their buccolingual position. The x-ray beam (*dotted lines*) is angulated relative to the horizontal plane. (B) Apparent locations of the mandibular canals in the resultant image. When lingually positioned (*orange*), the canal is projected more superiorly than when the canal is located buccally (*green*).



sinus



