

**IN THE NAME  
OF GOD**

# **Airway and Breathing**

The most common precipitating event for cardiac instability in infants and children is respiratory insufficiency .Therefore, rapid assessment of respiratory failure and immediate restoration of adequate ventilation and oxygenation remain the first priority in the resuscitation of a child.

first assess whether the child's airway is patent and maintainable .

A healthy, patent airway is unobstructed, allowing normal respiration without noise or effort.

A maintainable airway is one that is either already patent or can be made patent with a simple maneuver.

## **Assess airway patency**

- look for breathing movements in the child's chest and abdomen
- listen for breath sounds
- feel the movement of air at the child's mouth and nose

- Abnormal breathing sounds (e.g., snoring or stridor), increased work of breathing, and apnea are all findings potentially consistent with airway obstruction

# Assessment of breathing includes

- respiratory rate
- respiratory effort
- abnormal sounds
- pulse oximetry

# Normal breathing appears

- comfortable
- quiet
- occurs at an age-appropriate rate



# Normal Vital Signs According to Age

AGE	HEART RATE (beats/min)	BLOOD PRESSURE (mm Hg)	RESPIRATORY RATE (breaths/min)
Premature	120-170*	55-75/35-45 †	40-70 ‡
0-3 mo	100-150*	65-85/45-55	35-55
3-6 mo	90-120	70-90/50-65	30-45
6-12 mo	80-120	80-100/55-65	25-40
1-3 yr	70-110	90-105/55-70	20-30
3-6 yr	65-110	95-110/60-75	20-25
6-12 yr	60-95	100-120/60-75	14-22
12+ yr	55-85	110-135/65-85	12-18

# Abnormal respiratory rates include

- apnea
- rates that are too slow (bradypnea)
- rates that are too fast (tachypnea)

Bradypnea and irregular respiratory patterns require urgent attention because they are often signs of impending respiratory failure and/or apnea

Signs of increased respiratory effort include nasal flaring, grunting, chest or neck muscle retractions, head bobbing, and seesaw respirations

# **Recognition and Treatment of Respiratory Distress and Failure**

The goals of initial management of respiratory distress or failure are to rapidly stabilize the child's airway and breathing and to identify the cause of the problem so that further therapeutic efforts can be appropriately directed

# **Airway Obstruction**

- Children <5 yr old are particularly susceptible to foreign body aspiration and choking
- Liquids are the most common cause of choking in infants
- small objects and food are the most common source of foreign bodies in the airways of toddlers and older children



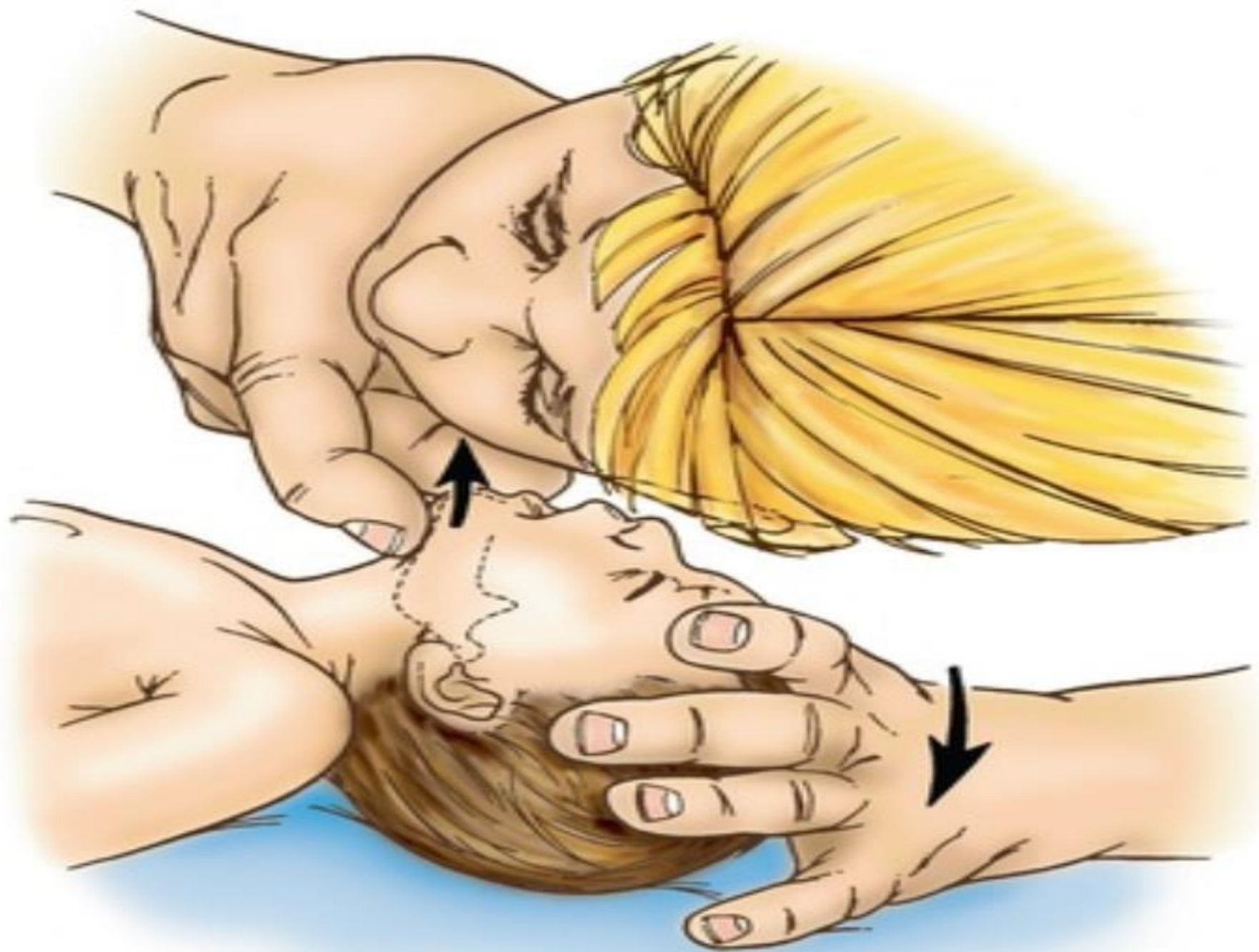
- A history consistent with foreign body aspiration is considered diagnostic
- Any child in the proper setting with the sudden onset of choking, stridor, or wheezing has foreign body aspiration until proven otherwise

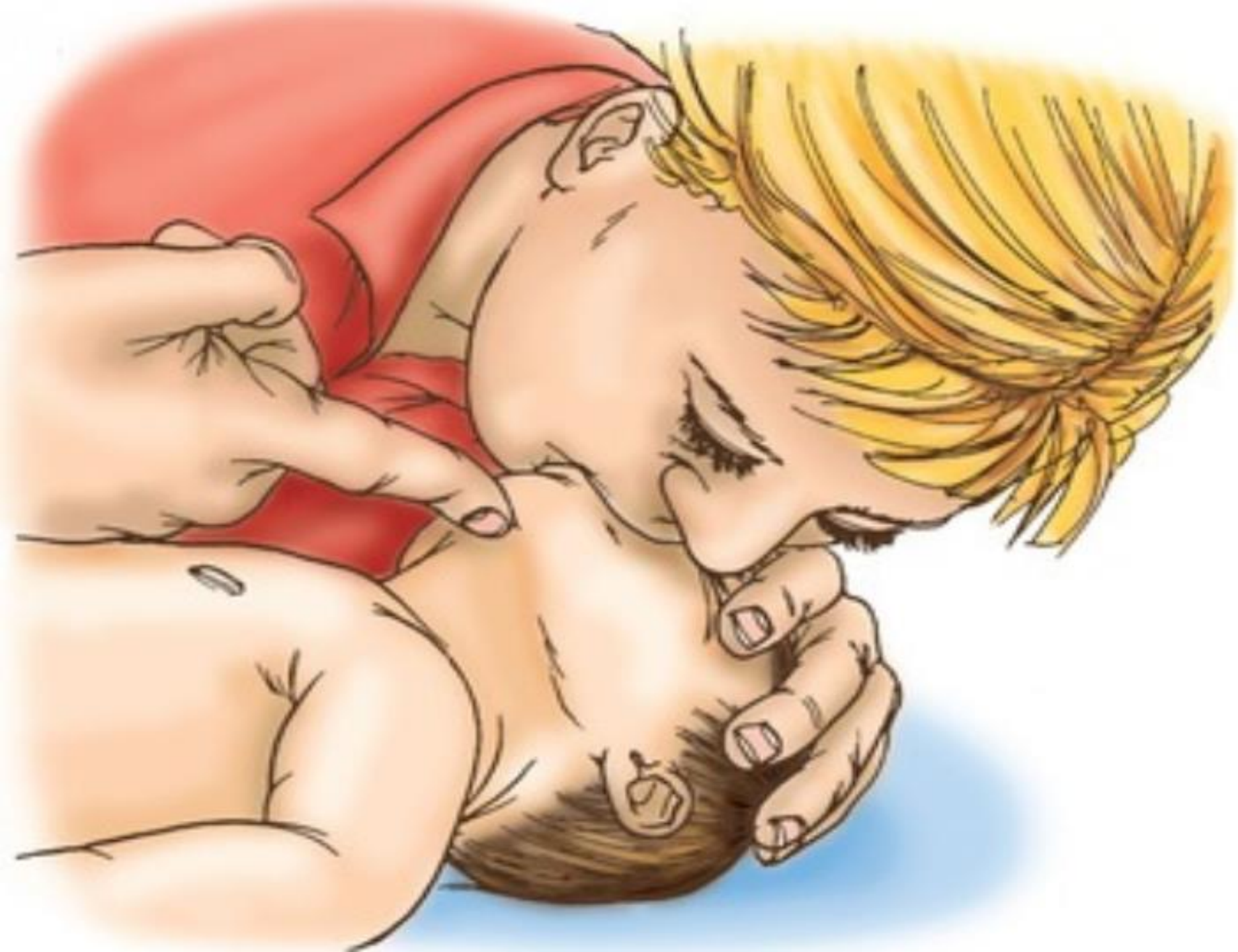Airway obstruction is  
treated with a  
sequential approach

- starting with the head-tilt/chin-lift maneuver to open and support the airway
- Inspection for a foreign body
- finger-sweep clearance or suctioning if one is visualized
- Blind suctioning or finger sweeps of the mouth are not recommended

- Nasopharyngeal airway or oropharyngeal airway can be inserted for airway support, if indicated
- A conscious child suspected of having a partial foreign body obstruction should be permitted to cough spontaneously until coughing is no longer effective, respiratory distress and stridor increase, or the child becomes unconscious

- If the child becomes unconscious, the child should be gently placed on the ground, supine
- Open the airway with the headtilt/chin-lift maneuver and attempt mouth-to-mouth ventilation
- If ventilation is unsuccessful, the airway is repositioned and ventilation attempted again



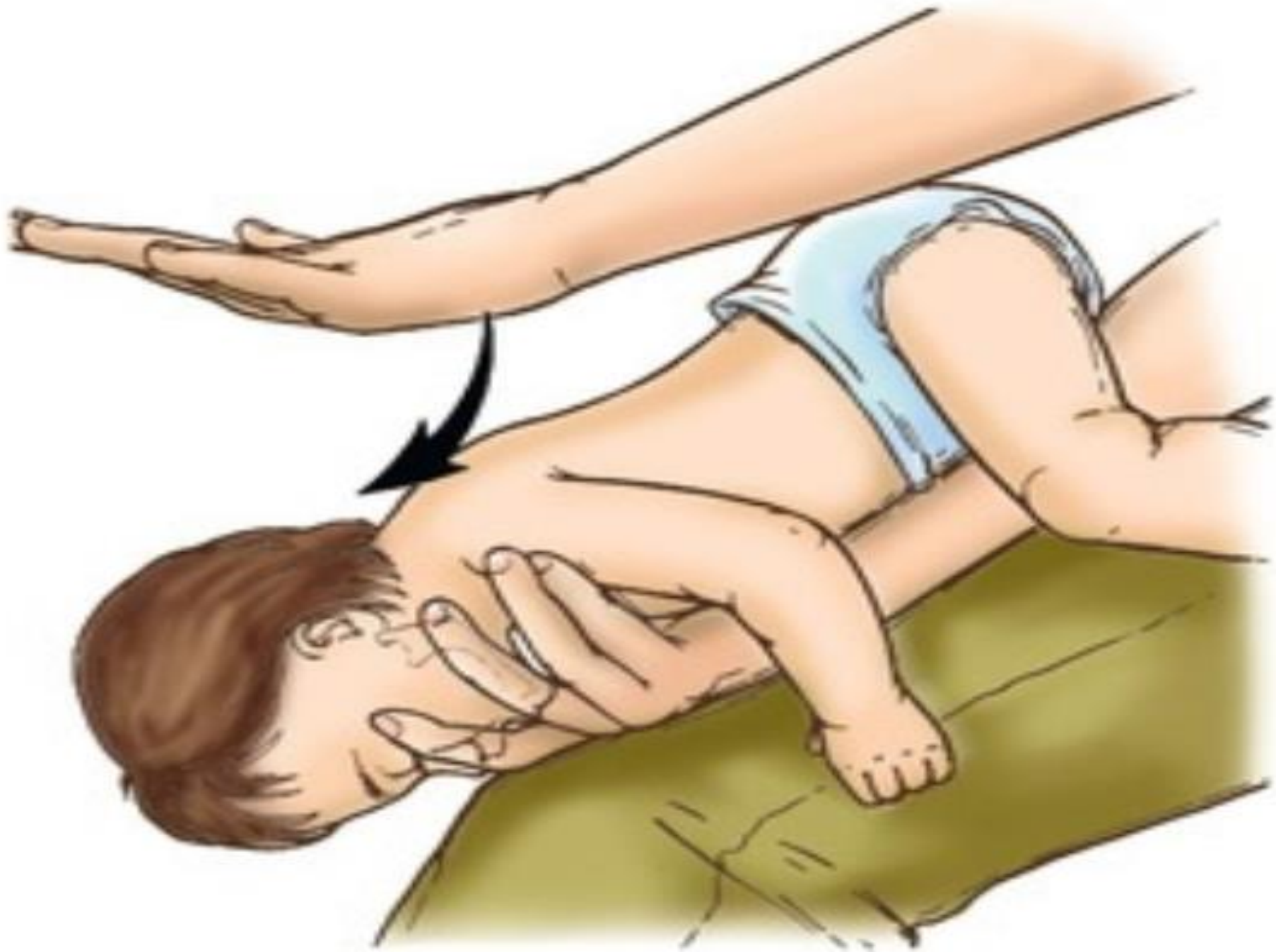


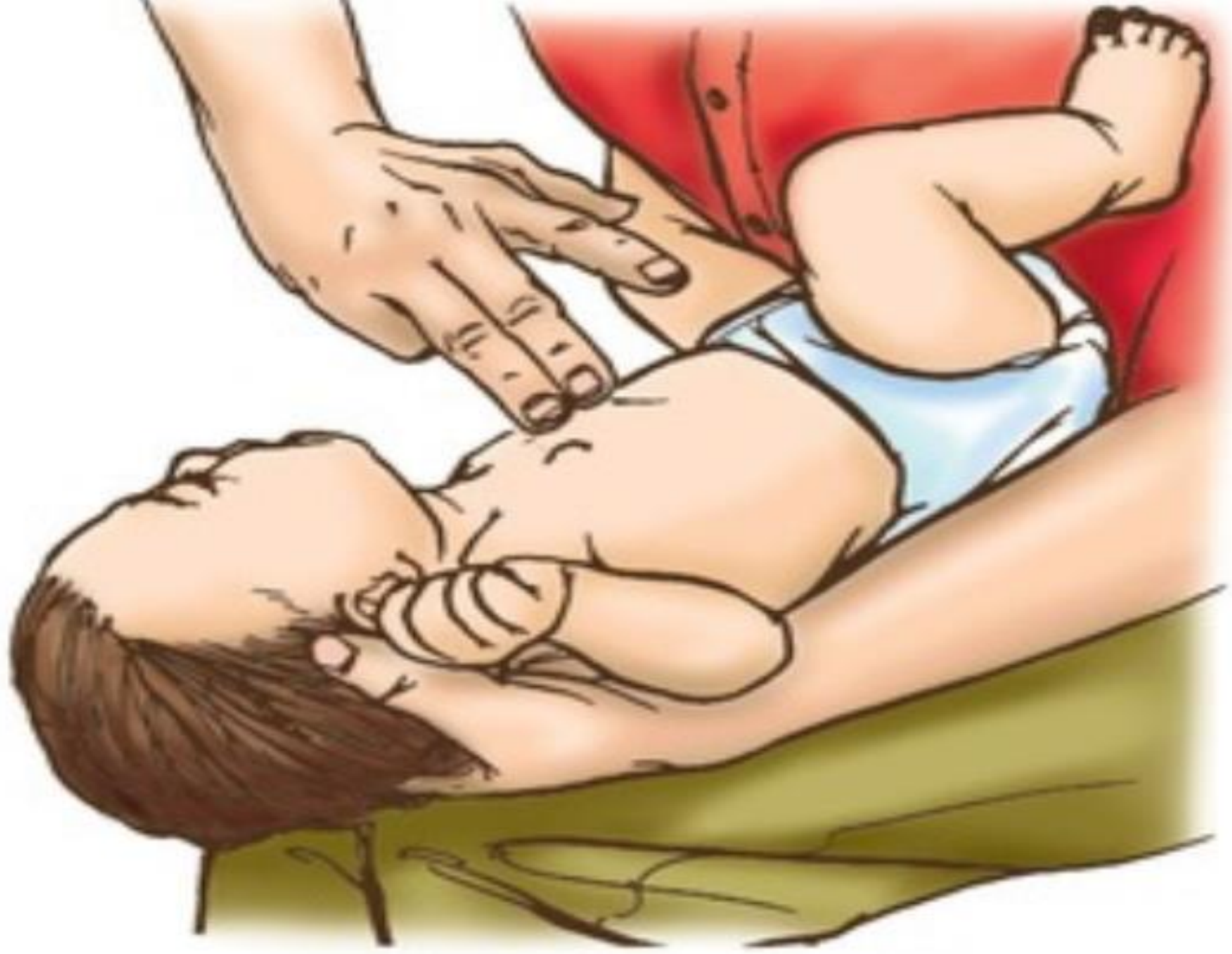





- If there is still no chest rise, attempts to remove a foreign body are indicated
- In an infant <1 yr old, a combination of 5 back blows and 5 chest thrusts is administered





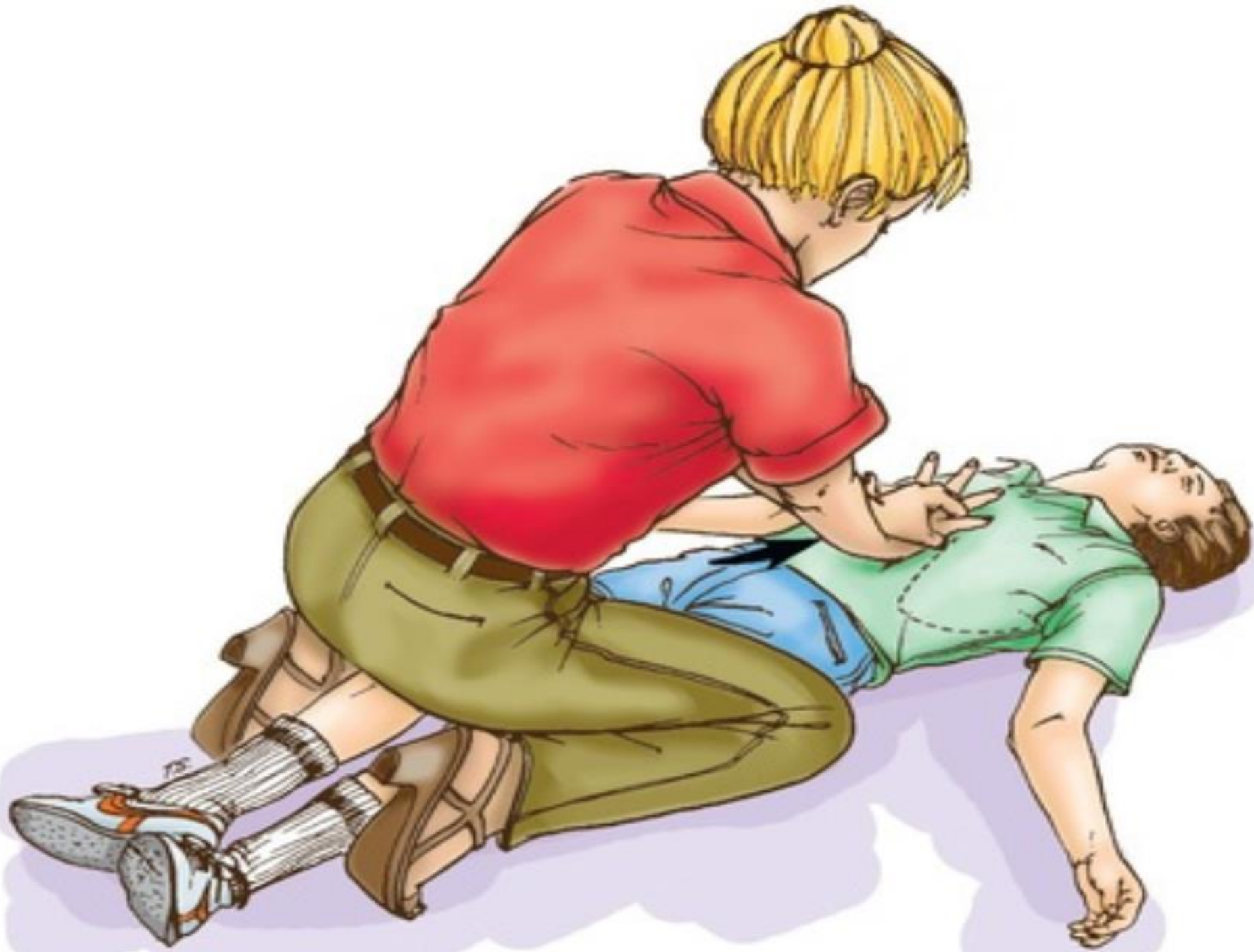- After each cycle of back blows and chest thrusts, the child's mouth should be visually inspected for the presence of the foreign body

- If identified within finger's reach, it should be removed with a gentle finger sweep
- If no foreign body is visual, ventilation is again attempted
- If this is unsuccessful, the head is repositioned and ventilation attempted again
- If there is still no chest rise, the series of back blows and chest thrusts is repeated

- For a conscious child >1 yr old, providers should give a series of 5 abdominal thrusts (**Heimlich maneuver**) with the child standing or sitting
- This should occur with the child lying down if unconscious









- After the abdominal thrusts, the airway is examined for a foreign body, which should be removed if visualized
- If no foreign body is seen, the head is repositioned and ventilation attempted
- If unsuccessful, the head is repositioned and ventilation attempted again
- If these efforts are unsuccessful, the Heimlich sequence is repeated

# **Advanced Airway Management Techniques**

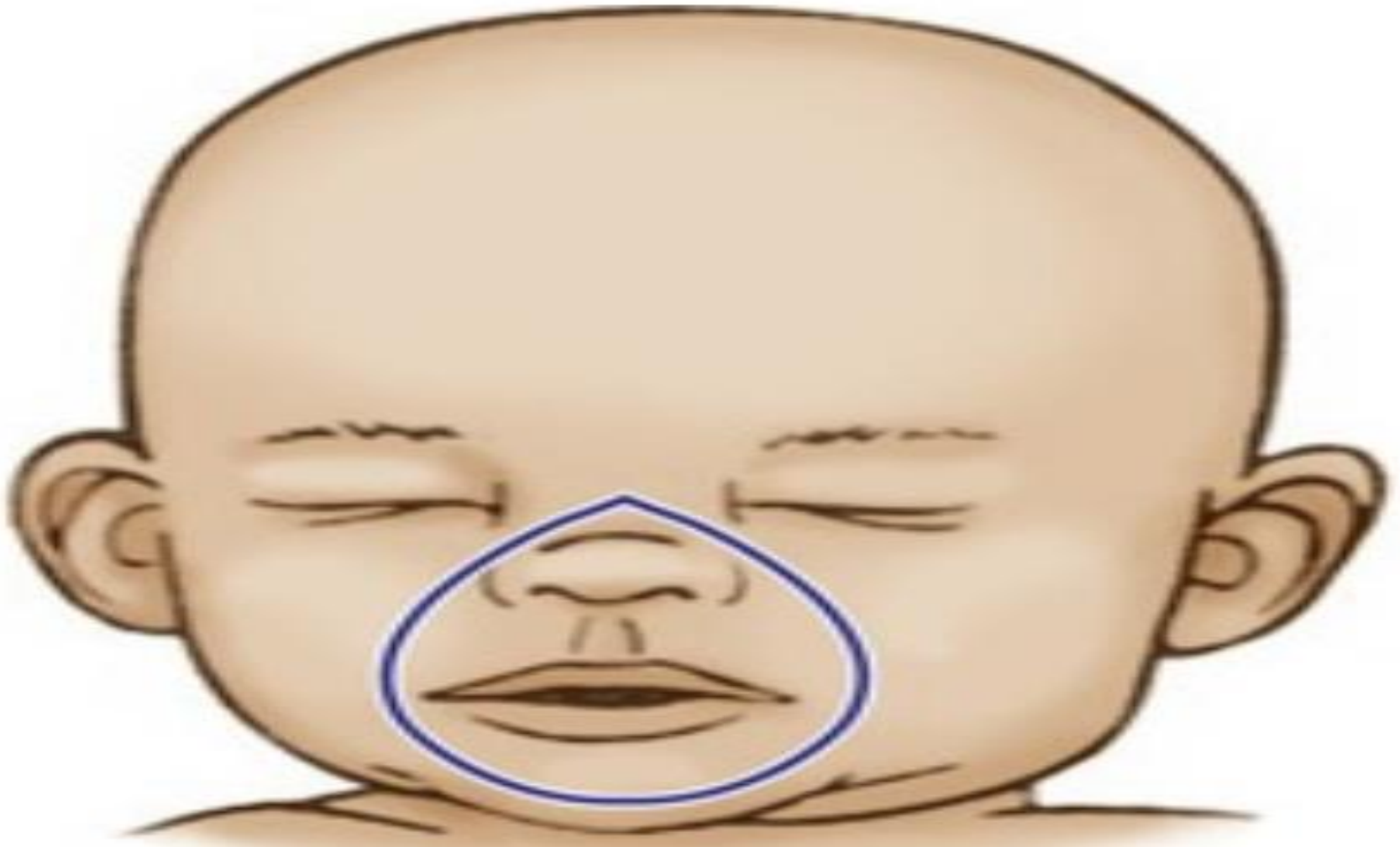# Bag-Valve-Mask Positive Pressure Ventilation

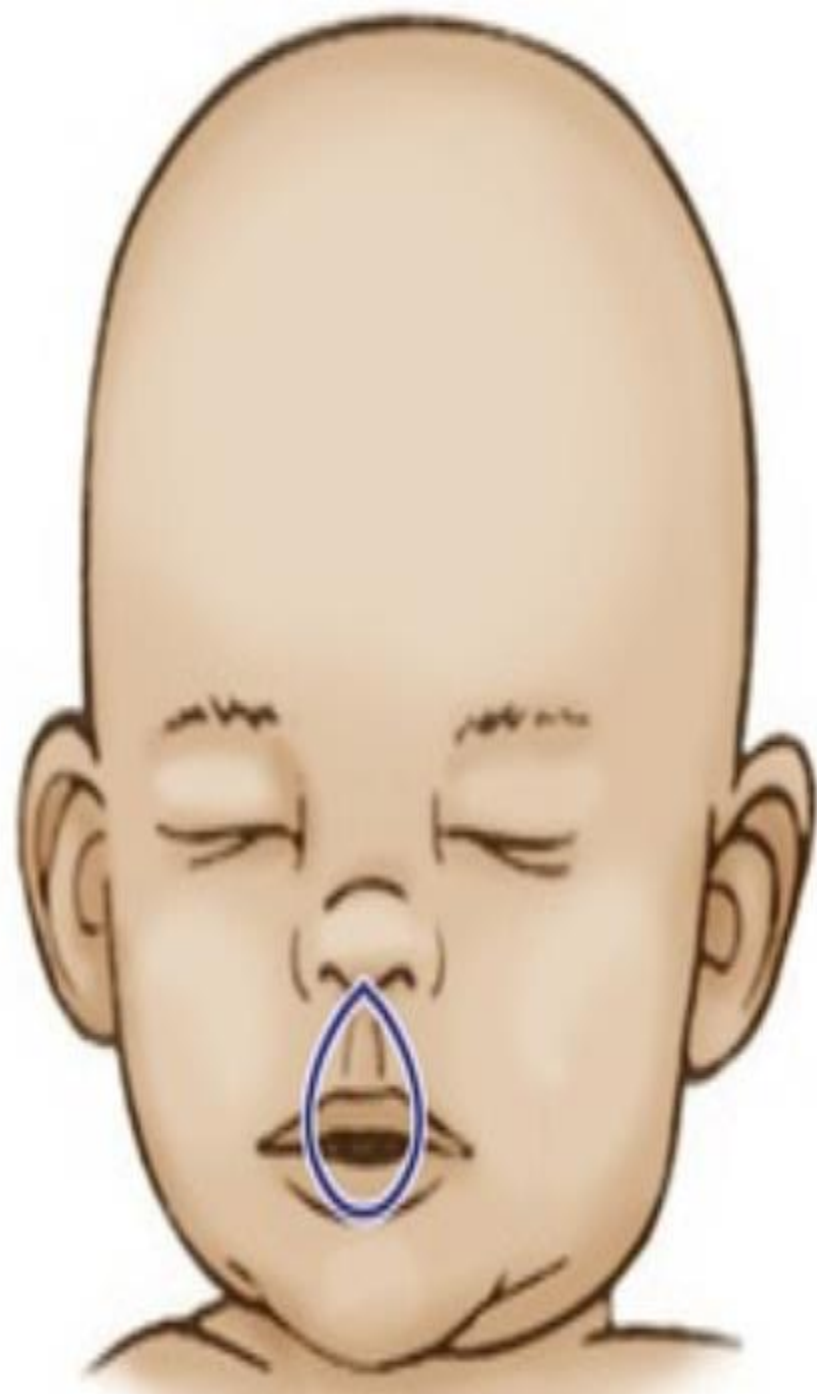
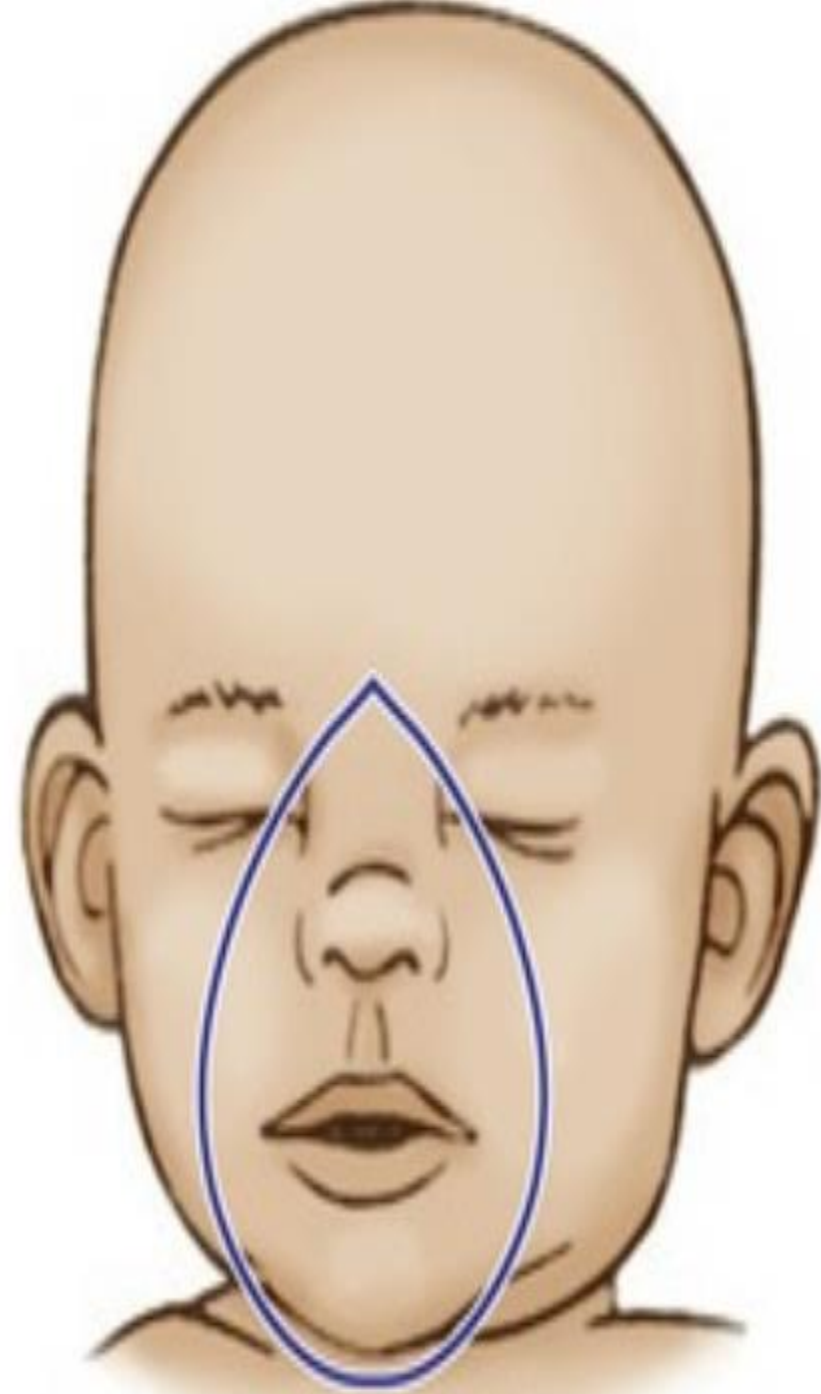
- Rescue breathing with a bag-valve-mask apparatus can be as effective as endotracheal intubation and safer when the provider is inexperienced with intubation

Bag-valve-mask ventilation itself requires training to ensure that

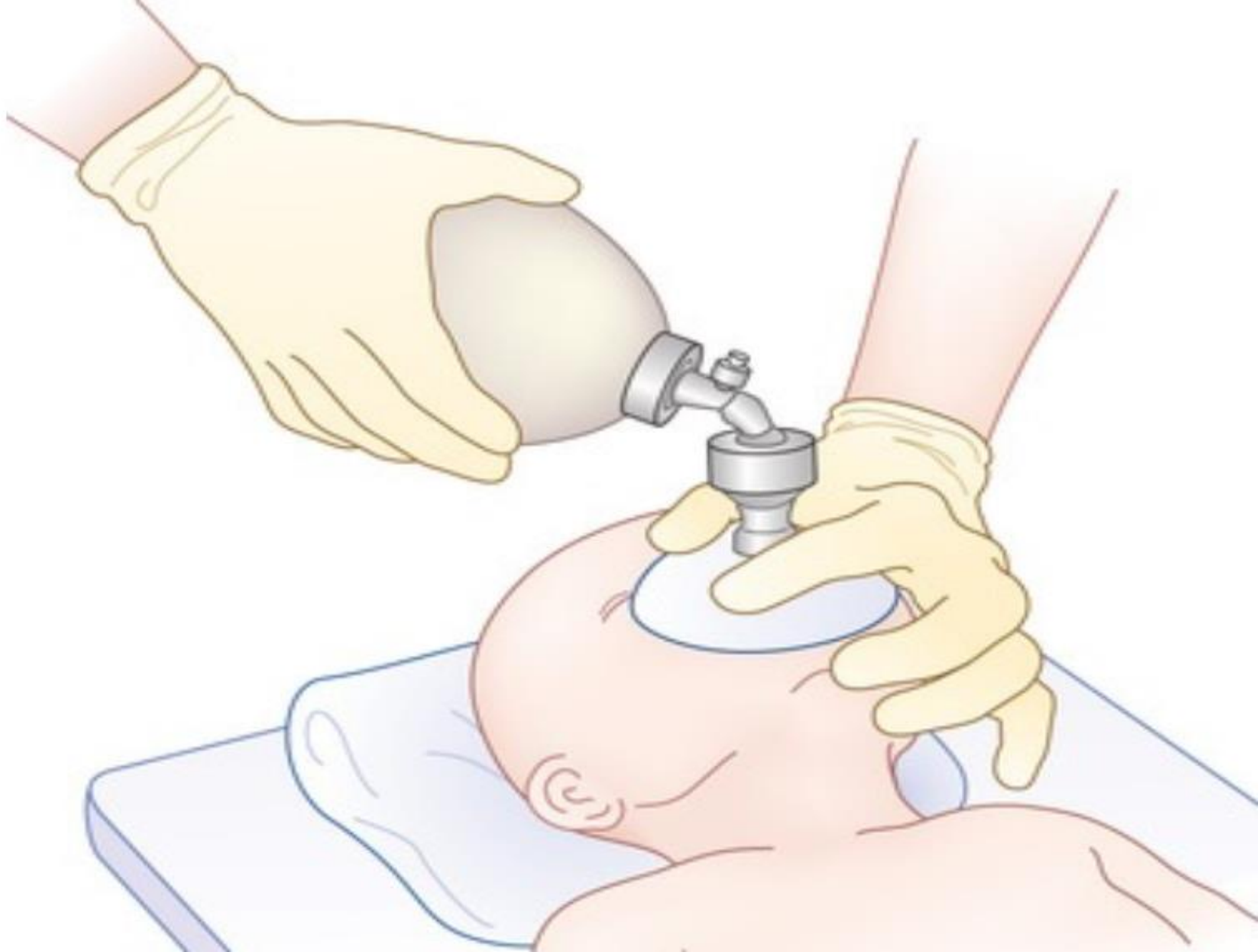- Select the correct mask size
- Open the child's airway
- Tight seal between the mask and the child's face
- Deliver effective ventilation
- Assess the effectiveness of the ventilation

An appropriately sized mask is one that fits over the child's mouth and nose but does not extend below the chin or over the eyes



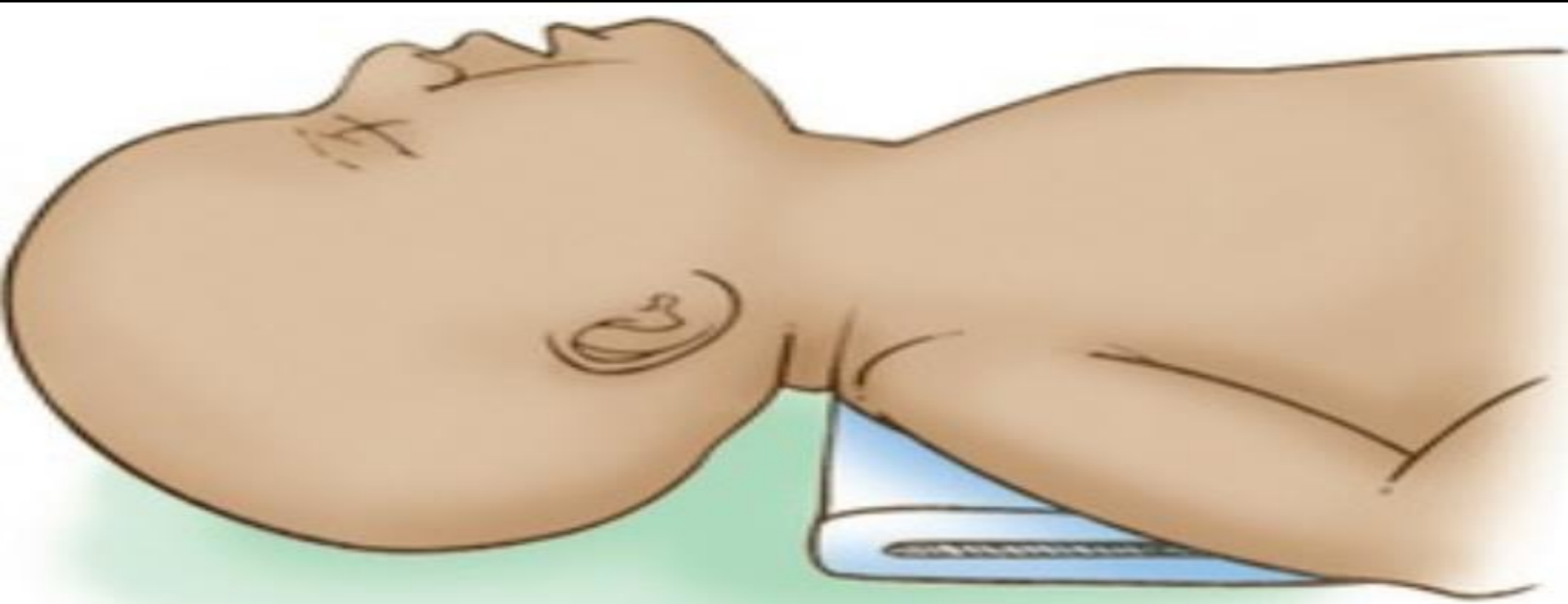

An adequate seal is best achieved through a combination “C-E” grip on the mask, in which the thumb and index finger form the letter “C” on top of the mask, pressing the mask downward onto the child's face, and the remaining 3 fingers form an “E” grip under the child's mandible, holding the jaw forward and extending the head up toward the mask





In infants and young children, optimal ventilation is often provided when the child's head is in the neutral sniffing position without hyperextension of the head



- Poor chest rise and persistently low  $\text{SO}_2$  values indicate inadequate ventilation
- In this setting should recheck the mask's seal on the child's face
- Reposition the child's head
- Consider suctioning the airway, if indicated
- If these maneuvers do not restore ventilation noninvasive or invasive respiratory support as clinically indicated

# Endotracheal Intubation

- A child generally requires intubation when at least one of these conditions exists
- (1) the child is unable to maintain airway patency or protect the airway against aspiration
- (2) the child is failing to maintain adequate oxygenation
- (3) the child is failing to control blood carbon dioxide levels and maintain safe acid-base balance

(4) Sedation and/or paralysis is required for a procedure

(5) care providers anticipate a deteriorating course that will eventually lead to any of the first 4 conditions

➤ The most important phase of the intubation procedure is the preprocedural preparation

➤ An easy mnemonic for this is SOAP MM

1. suction(Yankauer suction catheter attached to wall suction)
2. oxygen (both preoxygenation of the patient and devices needed to deliver oxygen, such as a bag-valve-mask)

3. airway (appropriately sized endotracheal tube and laryngoscope)
4. people (all those needed during and immediately after the procedure, including respiratory therapists and nurses)
5. monitor (SO<sub>2</sub>, heart rate, blood pressure, capnography)

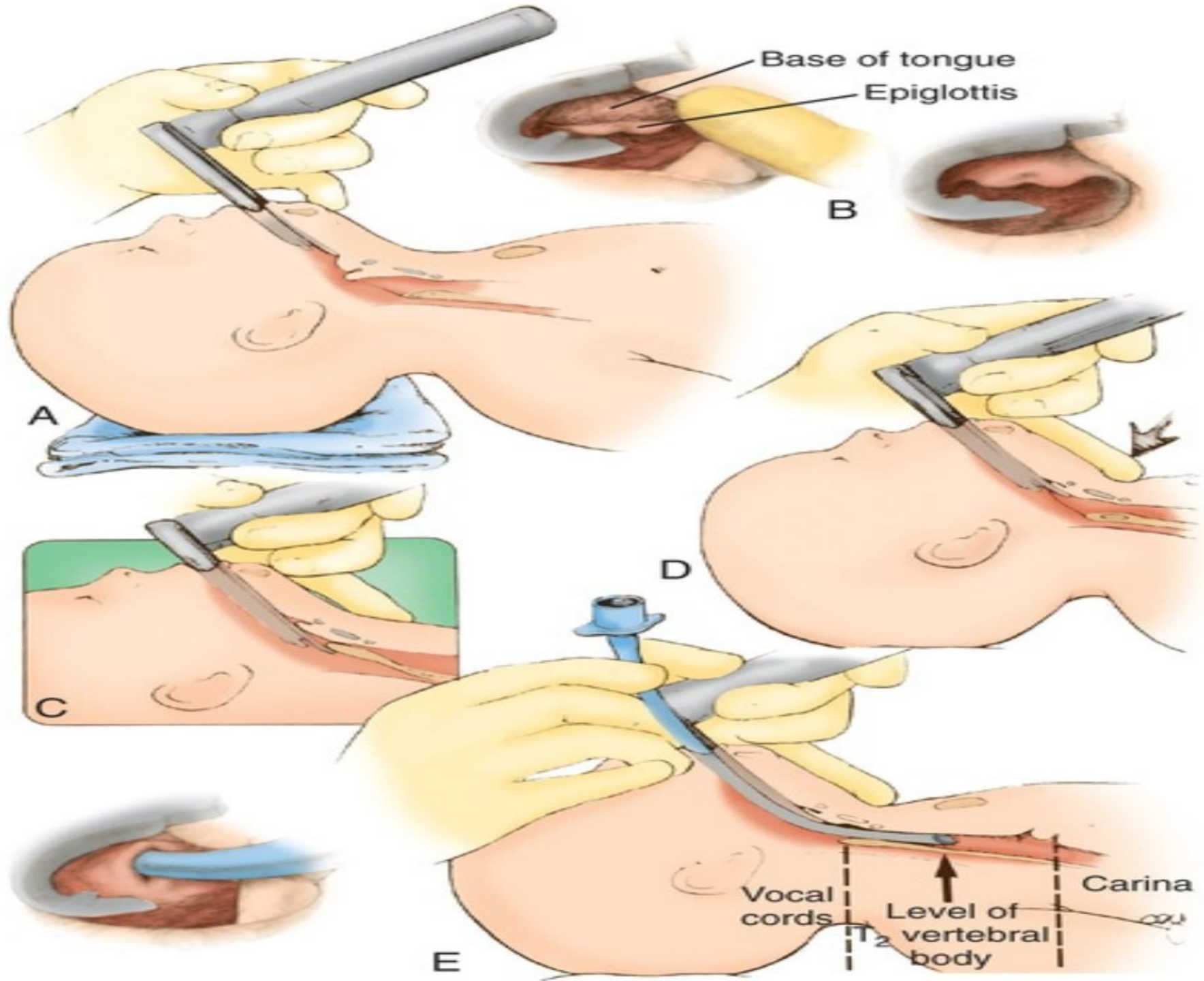
6. medications (sedation and often neuromuscular blockade to allow the provider(s) to control the airway)

A simple formula for selecting the appropriately sized endotracheal tube (ETT) is

$$\text{Uncuffed ETT size (in mm)} = \left( \frac{\text{age in years}}{4} \right) + 4$$

Cuffed ETTs should generally be 0.5 mm smaller





- Because many intubations in critically ill children are emergency procedures, caregivers should be prepared for **rapid sequence intubation (RSI)**
- The goals of RSI are to induce anesthesia and paralysis and to complete intubation quickly

➤ the stomach generally cannot be emptied before RSI, the Sellick maneuver (downward pressure on the cricoid cartilage to compress the esophagus against the vertebral column) should be used to prevent aspiration of gastric contents

# ETT placement should be assessed by

- Auscultation of breath sounds
- Evidence of symmetric chest rise
- Analysis of exhaled carbon dioxide (CO<sub>2</sub> )
- Chest radiography