IgG4-related disease:

Clinical presentation:

Pulmonary parenchymal manifestations:

Thickening of the perilymphatic interstitium, with or without subpleural and/or peribronchovascular consolidation, is very common.

- Lesions previously described as ‘inflammatory pseudotumors in the lung (plasma cell type)’, characterized by histopathologically active fibrosis and massive lymphoplasmacytic infiltration by IgG4+ plasma cells, are now regarded as being lesions of IgG4-RRD.
- Nonspecific interstitial pneumonia may be a manifestation of IgG4-RRD.
- Organizing pneumonia also has been reported to occur in IgG4-RD

IgG4-related disease:

Clinical presentation:

Pleural manifestations:

Pleural thickening and/or masses have been observed, with or without parenchymal lesions, and as well as pleural effusion, they are regarded as manifestations of IgG4-RRD.

Pulmonary vascular involvement:

Obliterative vasculitis with dense lymphoplasmacytic infiltrates may result in pulmonary hypertension.

- up to 75% of patients are asymptomatic and identified only by imaging.

IgG4-related disease:

Diagnosis: There are two major systems for diagnosis of IgG4-RD, the Japanese and the Boston criteria.

In 2017 the diagnostic criteria for IgG4 related respiratory disease was published.

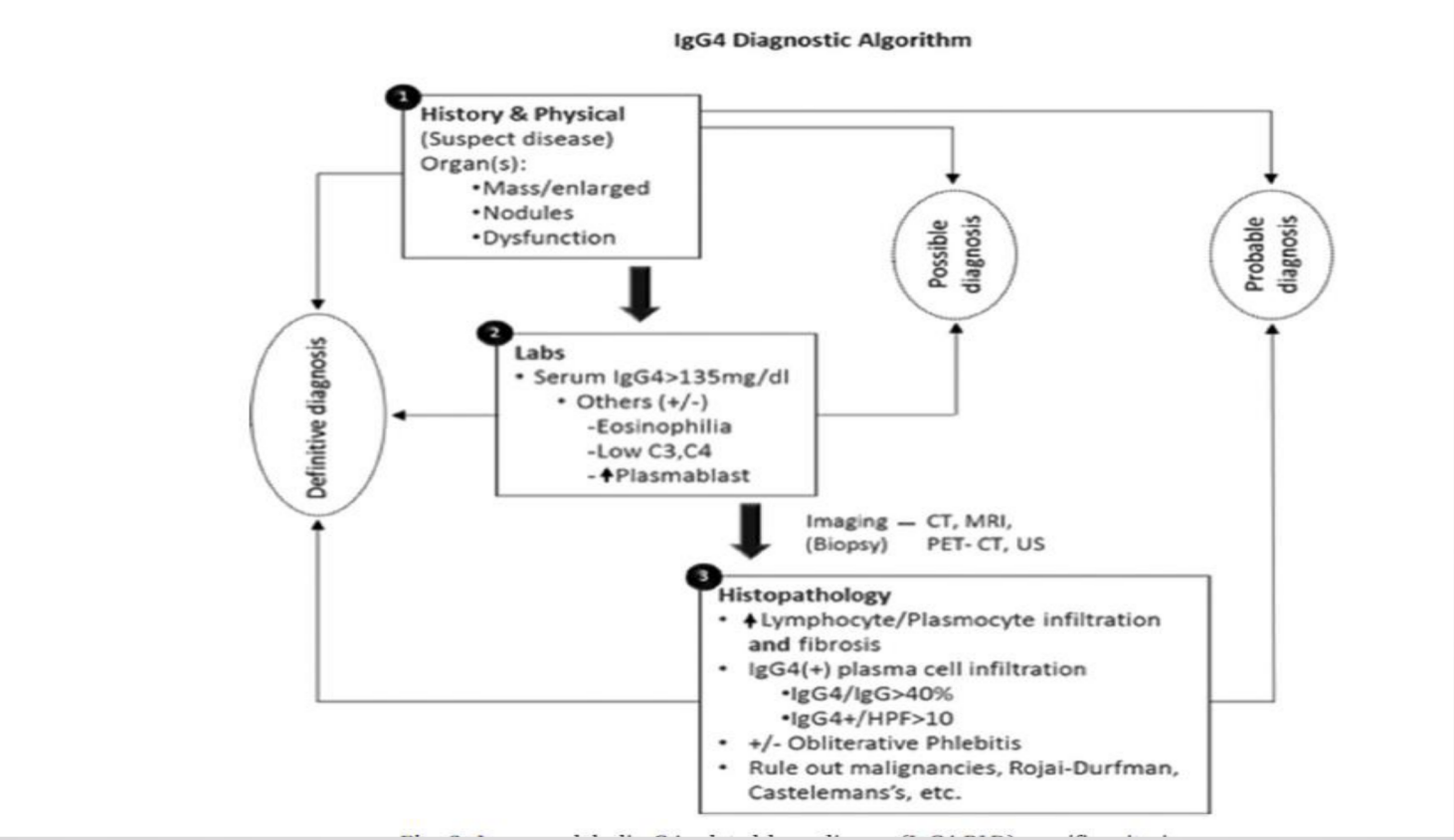

IgG4-related disease:

- The bronchoalveolar lavage fluid (BALF) levels of IgG4 might be a promising tool to diagnose IgG4-RLD.
- Assays of bronchoalveolar lavage fluid showed lymphocyte predominance, but the CD4/CD8 lymphocyte ratios were non-specific for IgG4-RRD.
- Transbronchial lung biopsy (TBLB) samples are insufficient to detect these findings, whereas surgical lung biopsy specimens are needed for a definitive diagnosis
- The role of pulmonary function tests (PFT) in the diagnosis of pulmonary IgG4-RLD remains unknown.
- **Diagnosis of IgG4-RLD is a diagnosis of exclusion.**

IgG4-related disease:

- **Differential diagnosis:**
- 1) Multicentric castleman's disease (MCD)
- 2) Rosai-Dorfman
- 3) Granulomatosis with polyangiitis
- 4) Microscopic polyangiitis (MPA)
- 5) Eosinophilic granulomatosis with polyangiitis(EGPA)
- 6) Malignancy
- 7)Nonspecific interstitial pneumonia (idiopathic, collagen vascular disease-related)
- 8) Sarcoidosis

IgG4-related disease:

- **Treatment and prognosis:**
- The mainstay treatment for IgG4-RD is corticosteroids.

- Lung involvement tends to respond favorably to prednisone treatment (20-50 mg daily) and improvement is noticed in both symptoms as well as imaging.

- Continued low dose steroids can be used to prevent long term relapse.

- some patients require both glucocorticoids and steroid-sparing immunosuppressive drugs from the start of the treatment because the steroids might fail or have strong side effects.

IgG4-related disease:

- **Treatment and prognosis:**
- Bortezomib (protease inhibitor) and cyclosporine has been used in addition to steroid in recurrent diseases.

- Patients who do not respond to corticosteroids were treated with cyclophosphamide, azathioprine, and mycophenolate mofetil and showed histopathologic evidence of remission.

- **Rituximab has been used as an alternative to steroids and showed a rapid decline in serum IgG4 levels. This agent works by depleting the pool of B cells.**

IgG4-related disease:

Case Report

Iranian Journal of Immunology
https://iji.sums.ac.ir

High Level of IgG4 in a Patient with Extensive Pulmonary Involvement

Mohammad Hassan Bemanian[1], Sima Bahrami[1]*, Saba Arshi[1], Afshin Rezaeifar[1], Mohammad Nabavi[1], Morteza Fallahpour[1], Sima Shokri[1]

[1]Department of Allergy and Clinical Immunology, Rasoul Akram Hospital, Iran University of Medical Sciences, Tehran, Iran

ABSTRACT

Immunoglobulin G4-Related Disease (IgG4-RD) is a systemic fibro-inflammatory disease that has been proposed as a separate entity since the beginning of this century. The disease is often manifested by increased serum IgG4 levels and certain histopathological manifestations. The patient mentioned in this article is a 29-year-old man from Tajikistan, who has had a chronic cough since the beginning of 2018 without a previous history of the disease. At first, he was diagnosed with pneumonia for a long time and then underwent a lung biopsy due to exacerbation of symptoms and the spread of lung lesions in radiology but no abnormalities were found in these evaluations. The patient traveled to Iran to continue his treatment. He was re-evaluated and then the previous samples taken from the patient's lung tissue were re-examined. Here are the key findings in favor of diagnosing IgG4 RD. Evaluations did not confirm the involvement of other organs. He was first treated with steroids and due to recurrence of symptoms, he was treated with rituximab once which was significantly effective in improving the patient's clinical symptoms. In general, it can be concluded that the diagnosis of IgG4-RD is very challenging and if it has not been diagnosed and treated in time, it can lead to irreversible fibrosis and permanent loss of function of the involved organ.

Keywords: Fibro-inflammatory disease, Immunoglobulin G4-related disease, Rituximab

*Corresponding author:
Sima Bahrami,
Department of Allergy, Rasool e Akram Hospital, Iran University of Medical Sciences, Tehran, Iran
Email: bahrami.s@iums.ac.ir

Cite this article as:
Bemanian MH, Bahrami S, Arshi S, Rezaeifar A, Nabavi M, Fallahpour M, Shokri S. High Level of IgG4 in a Patient with Extensive Pulmonary Involvement. *Iran J Immunol.*
doi:

Received: 2020-11-03
Revised: 2021-02-15
Accepted: 2021-03-28

IgG4-related disease: