


Approach to Acute Stroke in the Emergency Department

Dr. JUNE Kopyev

Dr Khazaei.M MD
Hamadan Medical University
Fellowship of neurovascular intervention

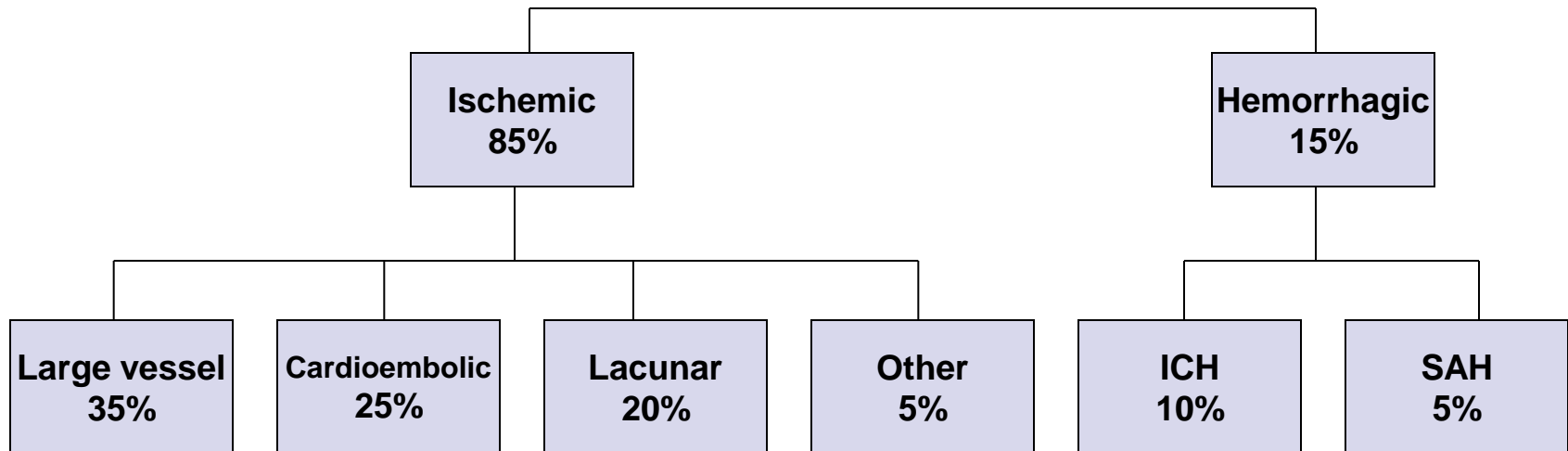




Objectives

- Types of stroke
- Differentiating hemorrhagic and ischemic strokes:
 - Clinically and radiologically
- Stroke syndromes
 - Anterior circulation:
 - Middle cerebral artery
 - Anterior cerebral artery
 - Posterior circulation:
 - Posterior cerebral artery
 - Basilar artery
- Case examples

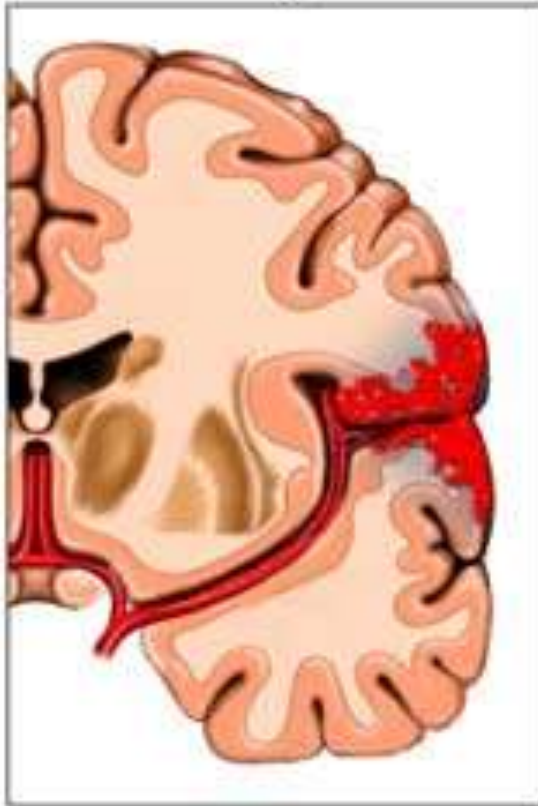
Types of Stroke



Differentiation Between Ischemic versus Hemorrhagic Strokes

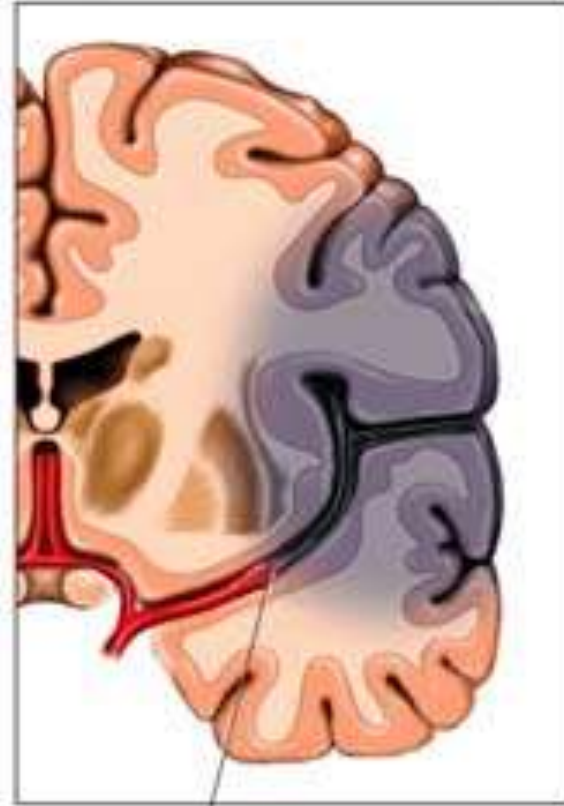


Hemorrhagic Stroke



Hemorrhage/blood leaks
into brain tissue

Ischemic Stroke



Clot stops blood supply
to an area of the brain

Clinical Clues for Detecting Hemorrhagic Stroke



Historical

- Headache
- Sudden onset but gradually worsening
- Nausea and vomiting

Examination Findings

- Decreased level of consciousness
- Hypertension
- Bradycardia
- Seizures
- Meningism
- Fever

Patients with hemorrhagic stroke present with similar focal neurologic deficits but tend to be more ill than patients with ischemic stroke



Other Clinical Clues

Causes:

- Uncontrolled hypertension
- Anticoagulants
- Coagulopathies
 - Known bleeding diathesis
 - Advanced liver disease
- Elderly with poor cognition (cerebral amyloid angiopathy)
- Known vascular malformations or aneurysms
- Brain tumours



Radiological Hallmarks

Urgent Non-contrast CT scan of the Brain

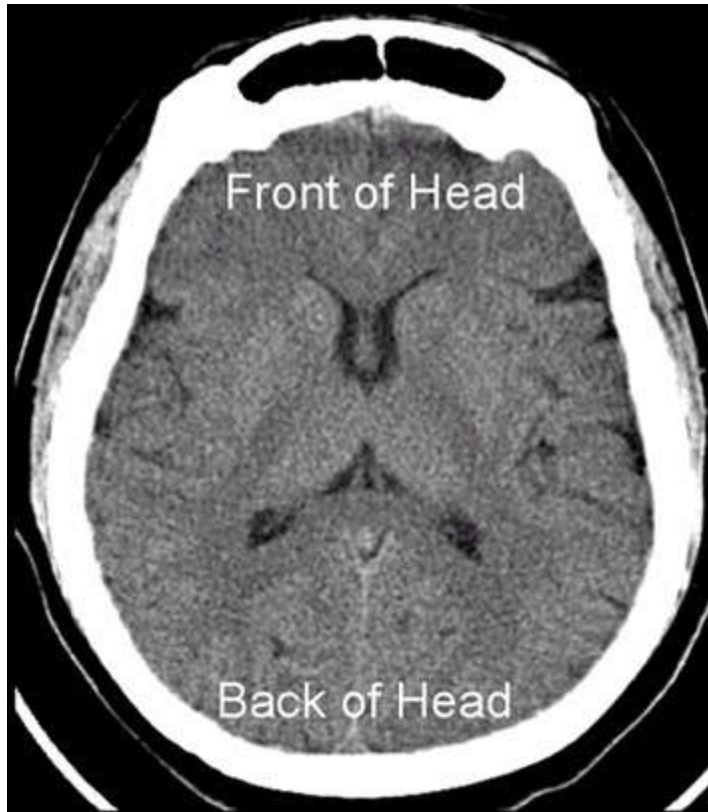
- Blood looks bright white
 - Don't confuse this with cerebral calcification
- Parenchymal versus subarachnoid
- Location
 - Deep versus lobar
- Volume
- Ventricular extension
- Hydrocephalus



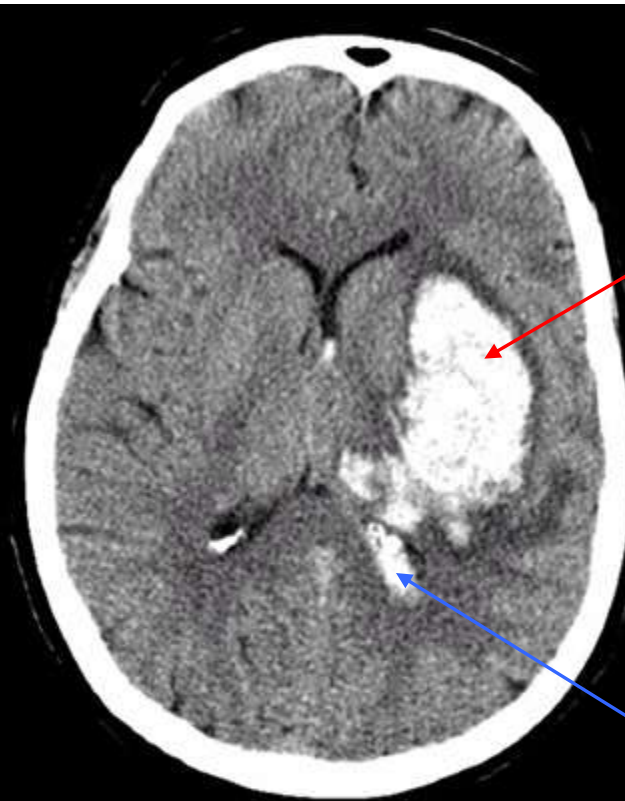Location of Bleeds

- Deep 50%
- Lobar 35%
- Cerebellum 10%
- Brainstem 5%

66yo M with uncontrolled HT



Normal CT Scan
Slice of Brain

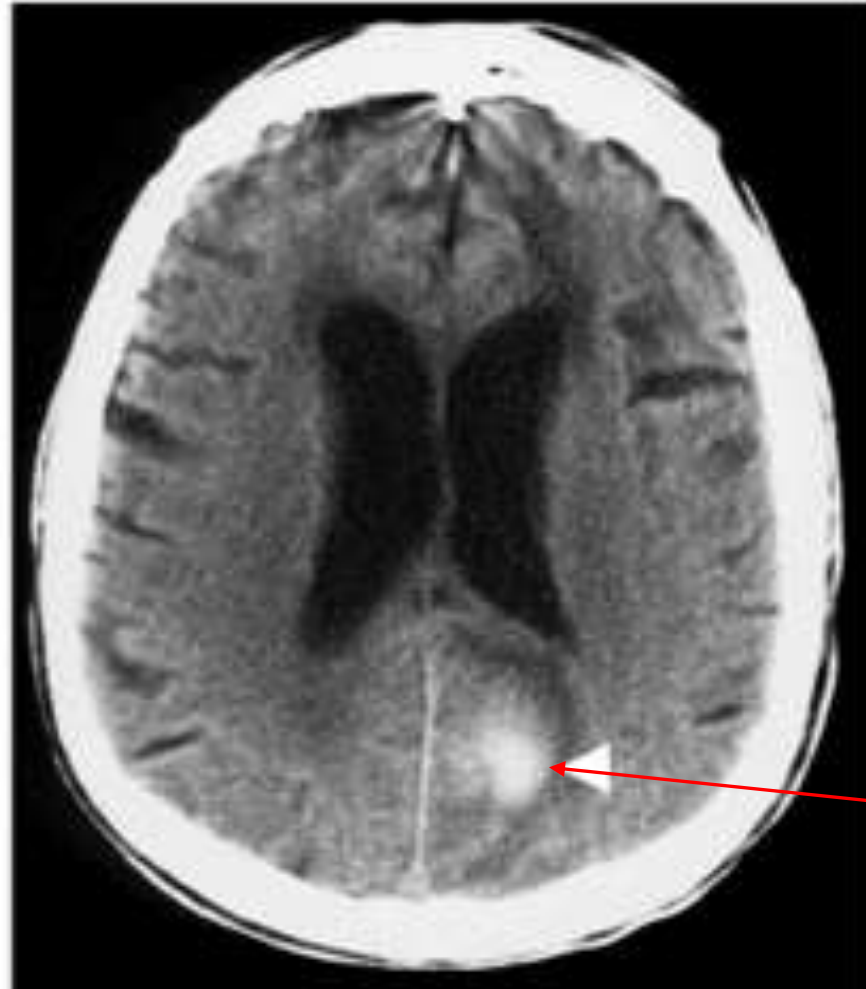

Intracerebral Hemorrhage
(bright white area)
CT Scan Slice of Brain

Large
deep ICH
affecting
left basal
ganglia

Blood in the
left lateral
ventricle

87 yo F with dementia

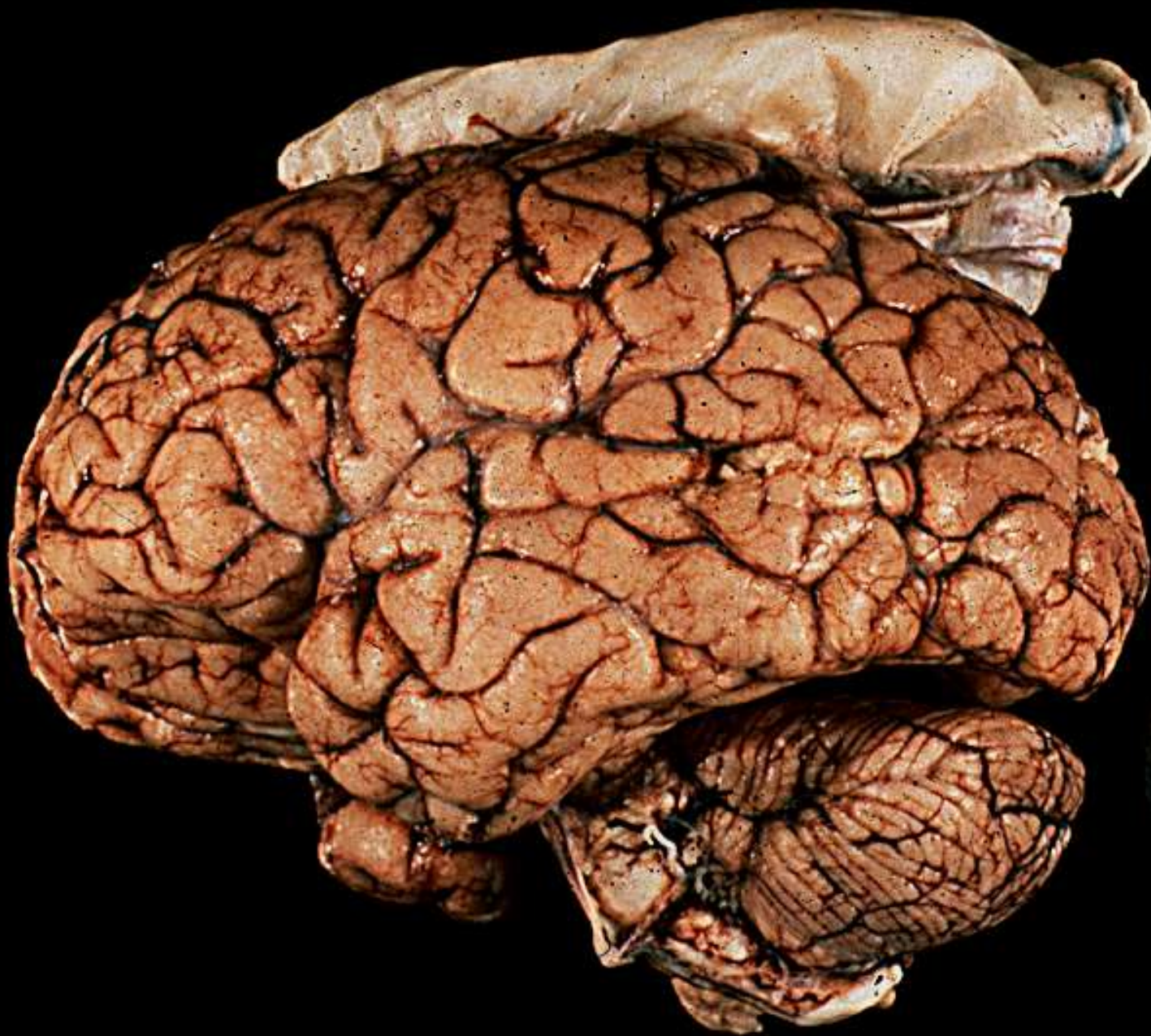

Lobar L
occipital ICH



Prognostic Factors in ICH

- Up to 50% mortality rates at 1 year
- Volume of hemorrhage predicts 30 day mortality
 - Poor functional outcomes >30ml ICH
 - >70ml ICH is usually fatal
 - Pontine hemorrhage, >5ml is usually fatal
 - Cerebellar hemorrhage, >30ml is usually fatal



28 mL

43 mL



Prognostic Factors in ICH

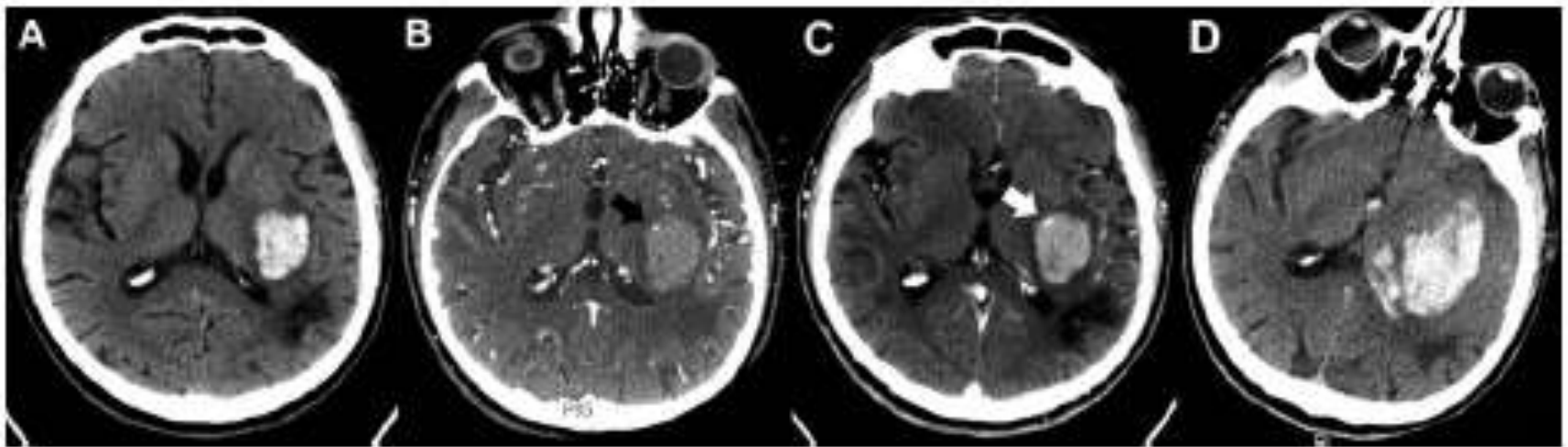
Hematoma Expansion

- 40% of hematomas expand by $>1/3^{\text{rd}}$ of their volume
- More than $2/3^{\text{rd}}$ of hematomas grow in the first hour
- Hematoma expansion correlates with poor functional outcome

CT Angiography



- Vascular anomalies
- “Spot sign”

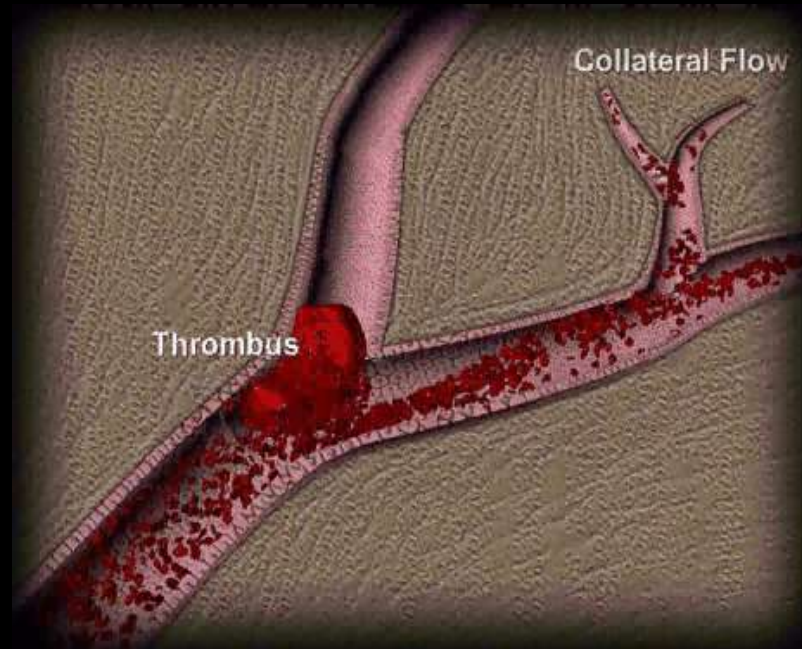


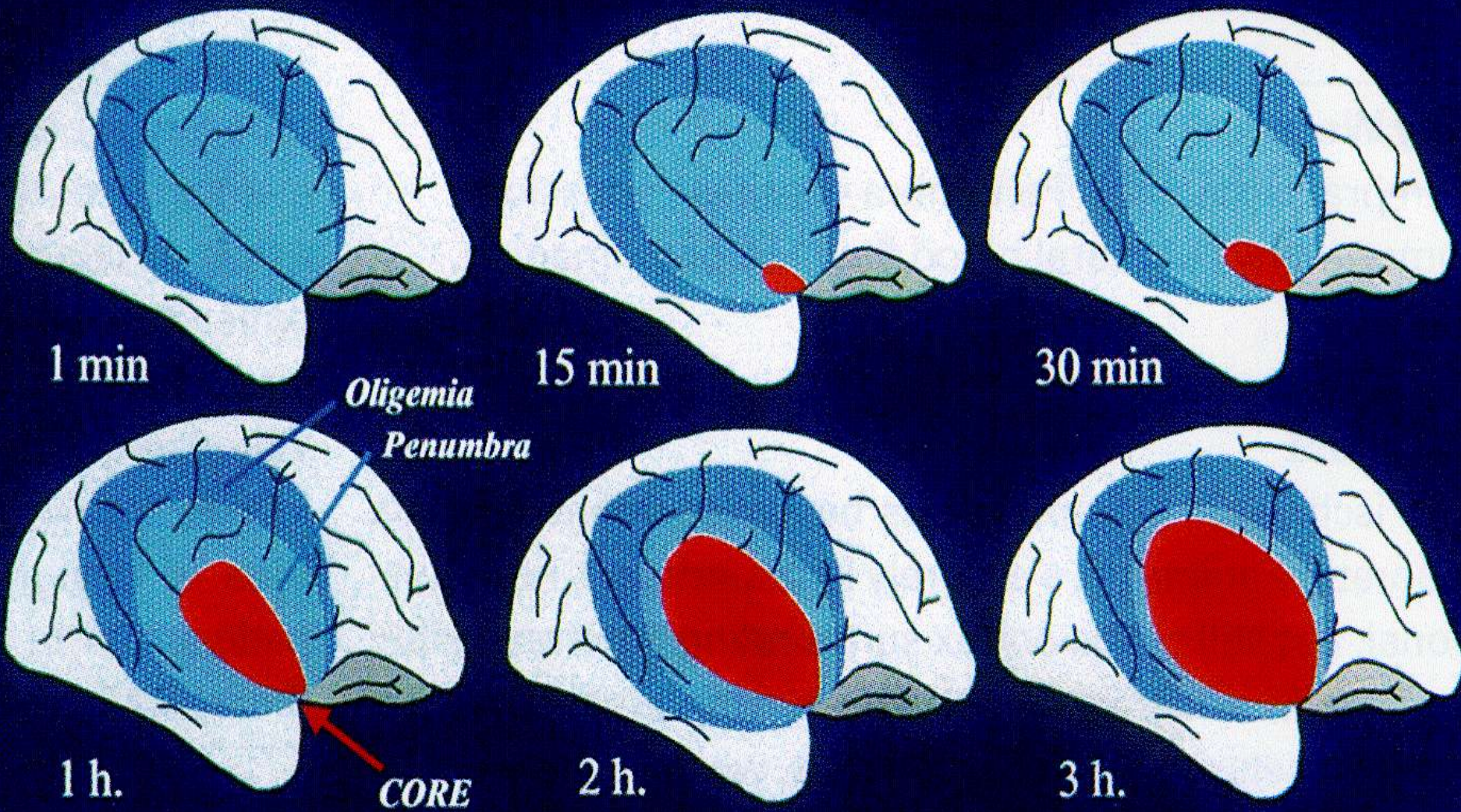


Ischemic Stroke

- Common
 - Every 45 secs, someone has a stroke
- Devastating
 - For every 10 stroke patients:
 - 2 will die
 - 2 will recover
 - 6 will be left with disability
- Potentially treatable (thrombolysis)

The Ischemic Penumbra





The Ischemic Penumbra : A Dynamic [time + space] concept



Clinical Clues of Ischemic Stroke

Historical Clues

- Cardiovascular risk factors:
 - Smoker
 - HT
 - Hypercholesterolemia
 - Diabetes
 - Family history
- Prothrombotic disorder
- AF
- Cardiomyopathy
- Valvular heart disease

Physical Examination

- Stroke syndrome pertaining to one vascular territory

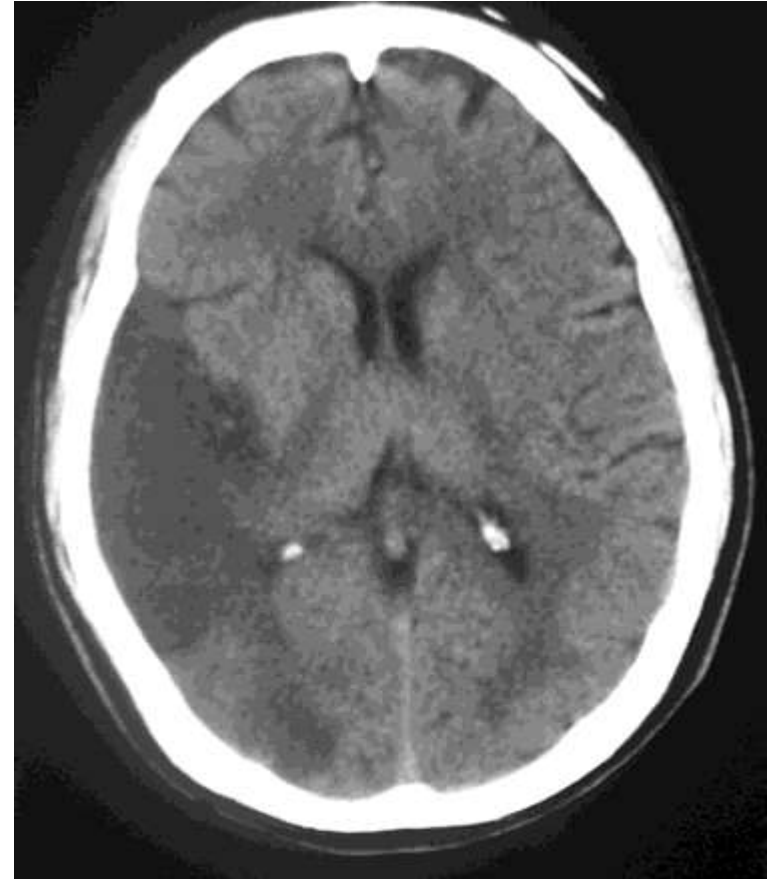Bottom line:

- You can't differentiate between ischemic and hemorrhagic stroke purely on history and physical examination
- Imaging is required!



Radiological Features of Ischemic Stroke

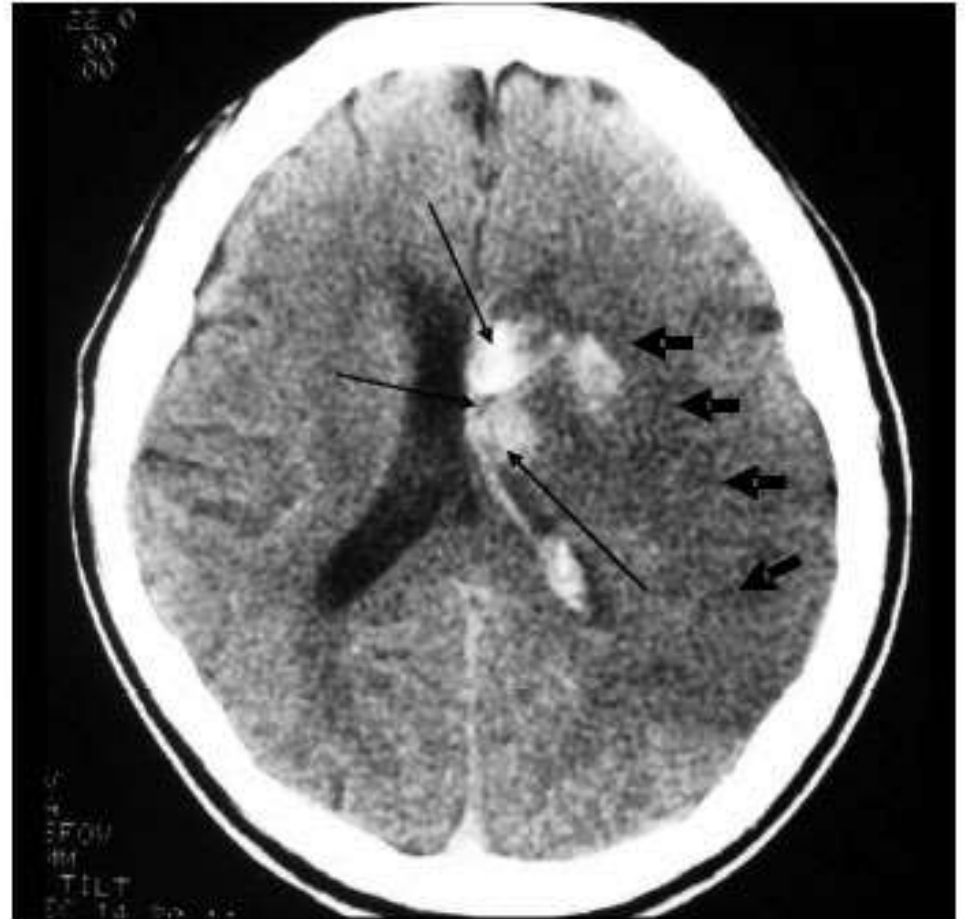- Infarcts look hypodense (dark) on CT



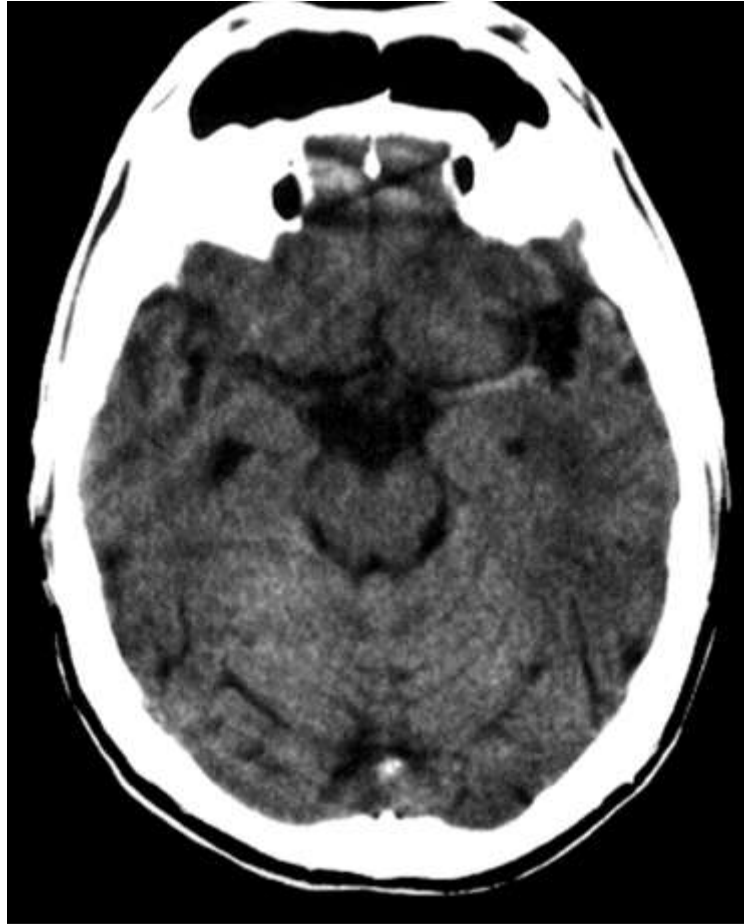


Radiological Features of Ischemic Stroke

- Hemorrhagic transformation



Hyperdense Vessel Sign



Ischemic Stroke Syndromes: Middle Cerebral Artery Occlusion

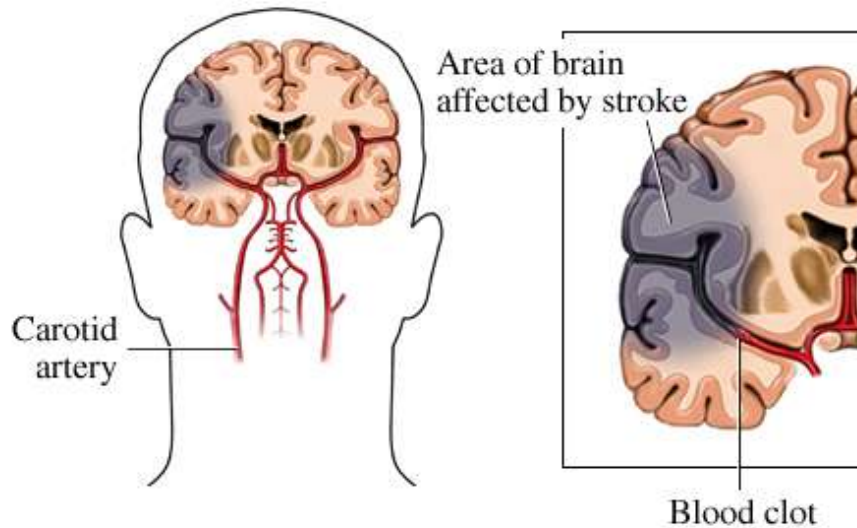
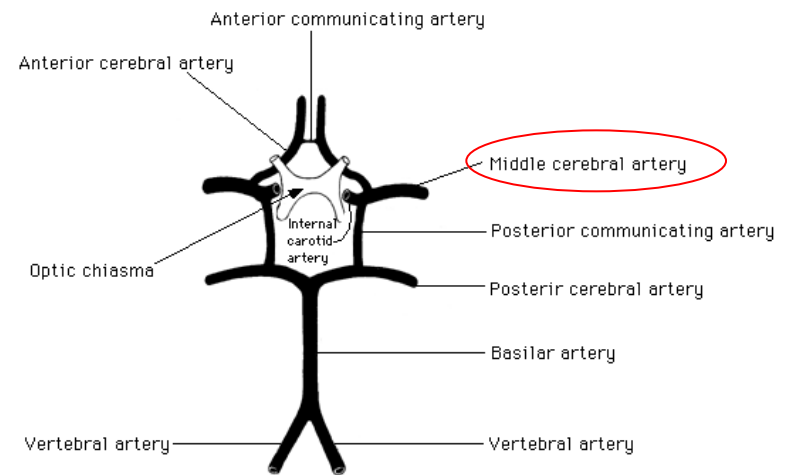
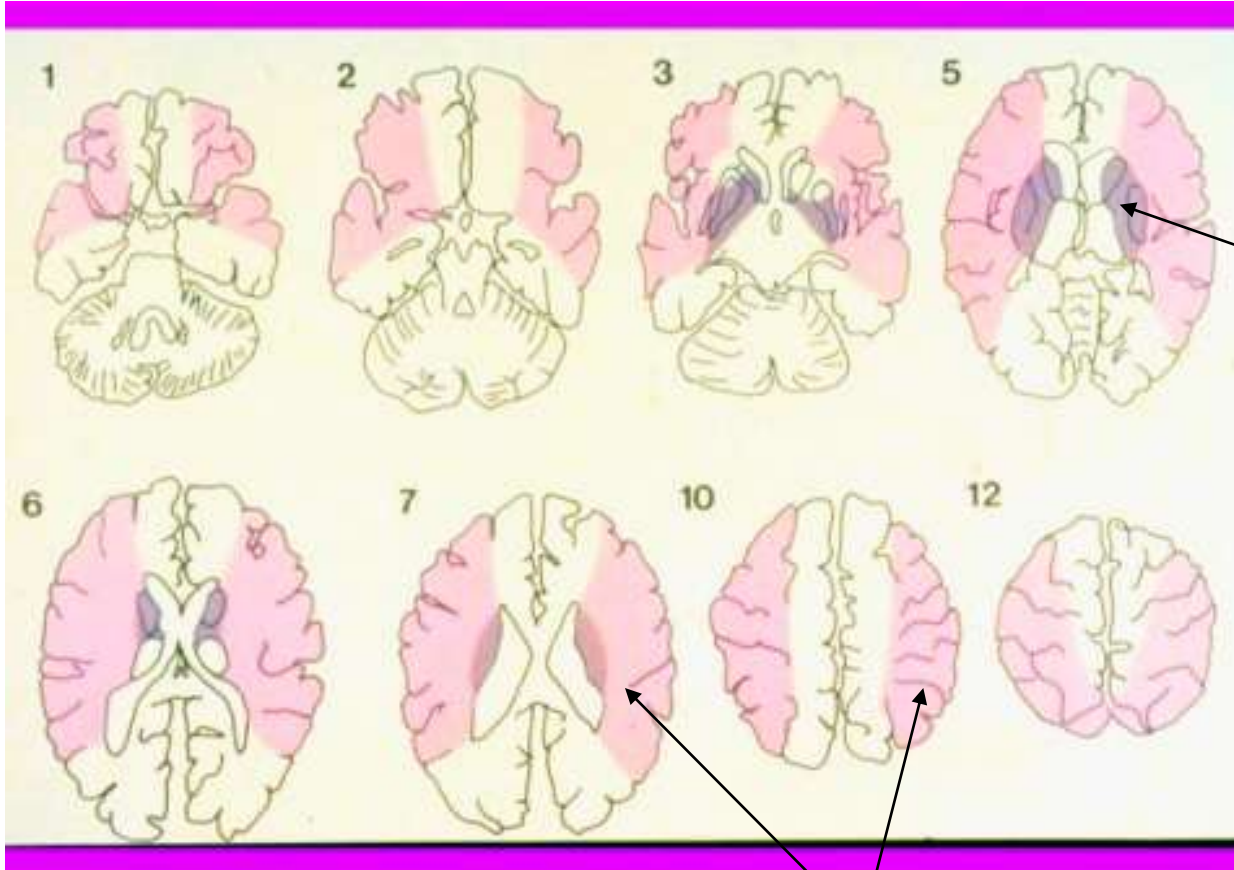


Figure 3A. Schematic diagram of the arteries to the brain, and the circle of Willis.



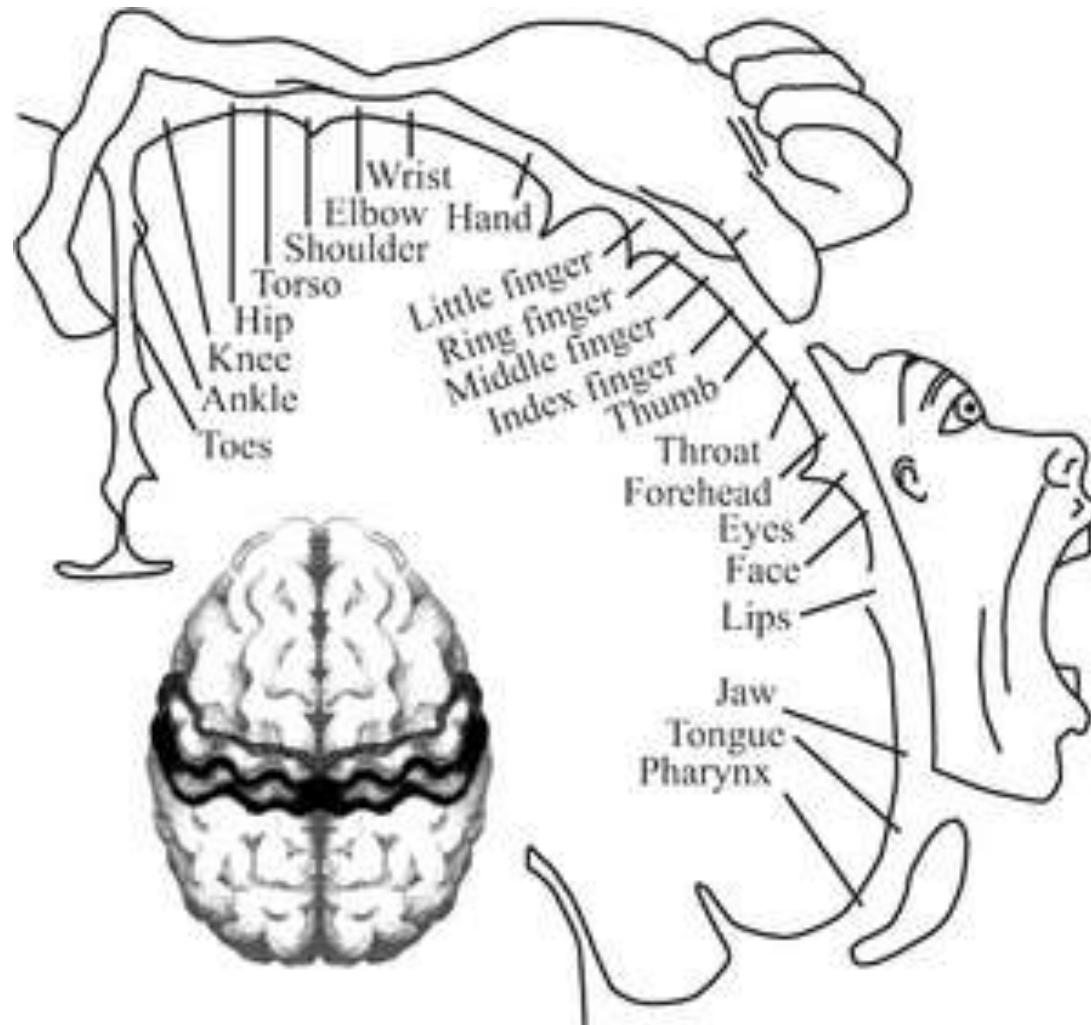
MCA



Basal ganglia
and internal
capsule

Frontal and parietal and temporal
lobes (spares paramedian area)

Homunculus

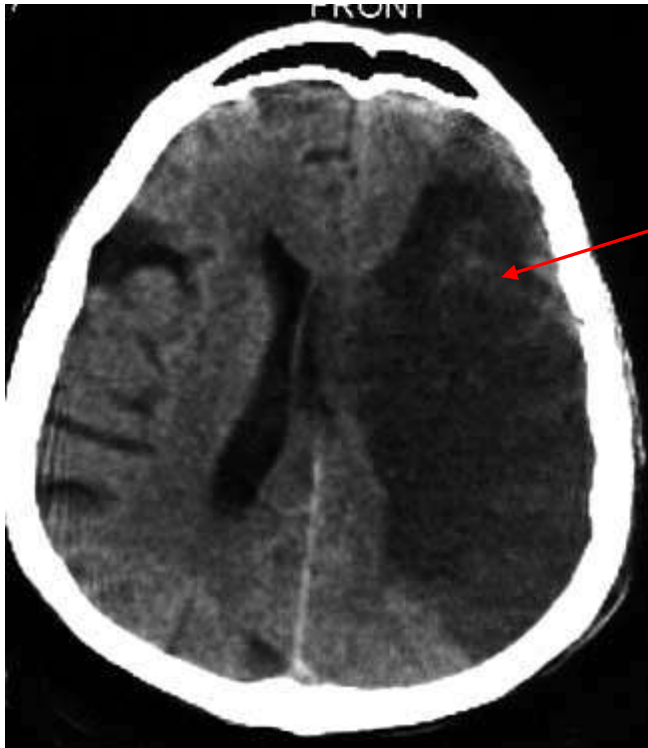



Middle Cerebral Artery

- Contralateral hemiparesis (face, arm>leg)
- Contralateral hemisensory impairment
- Contralateral homonymous hemianopia
- Specific hemispheric signs:
 - Left (dominant hemisphere)
 - Aphasia (expressive, receptive, global)
 - Right
 - Dysarthria
 - Neglect

MCA Infarct on Non-Contrast CT Brain



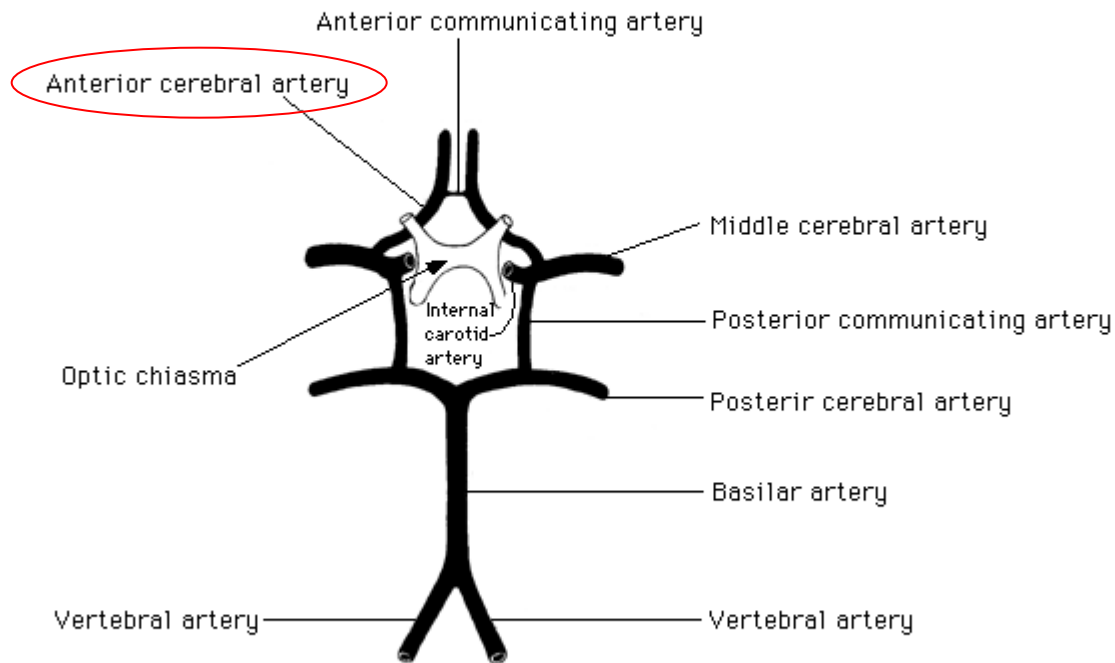
Large MCA
territory infarct
with
hemorrhagic
transformation

The MCA supplies the frontal,
temporal and parietal lobes

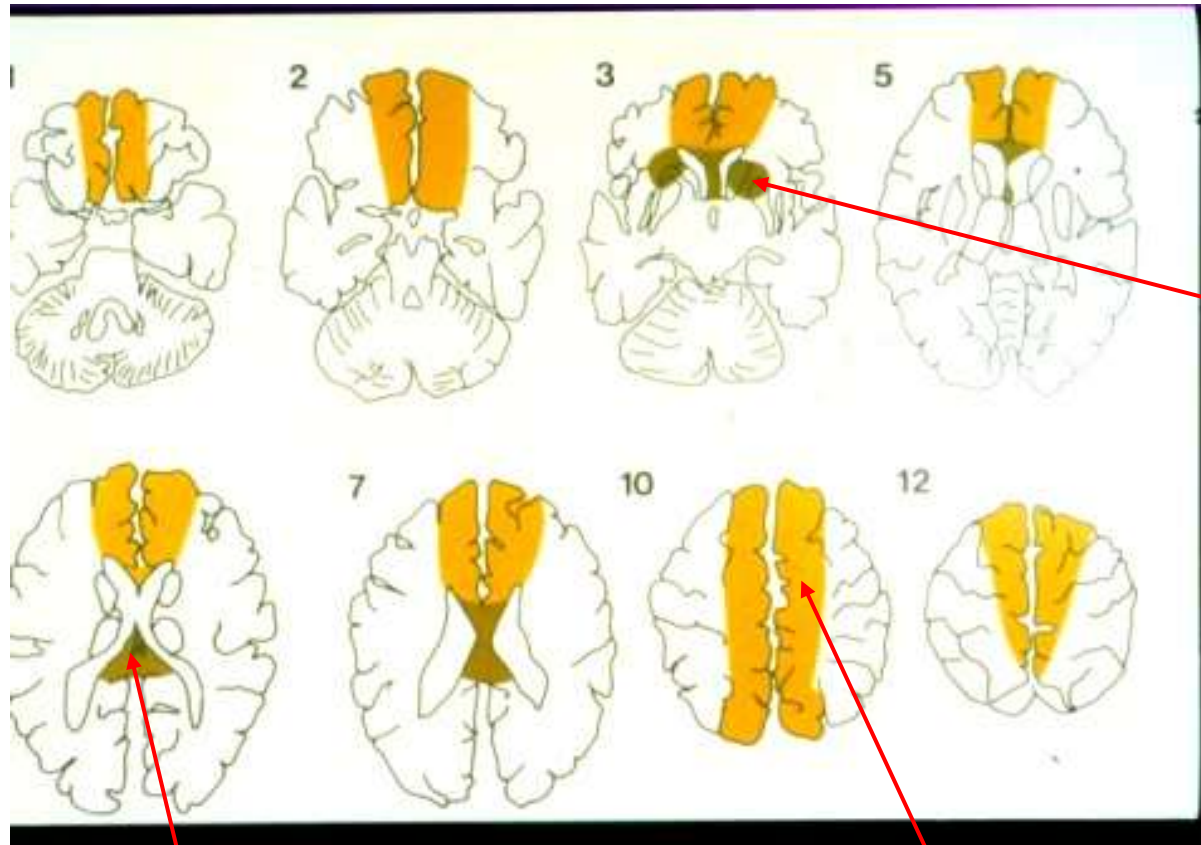

Ischemic Stroke Syndromes: Anterior Cerebral Artery Occlusion



Figure 3A. Schematic diagram of the arteries to the brain, and the circle of Willis.



ACA



Caudate and anterior limb of internal capsule

Corpus callosum

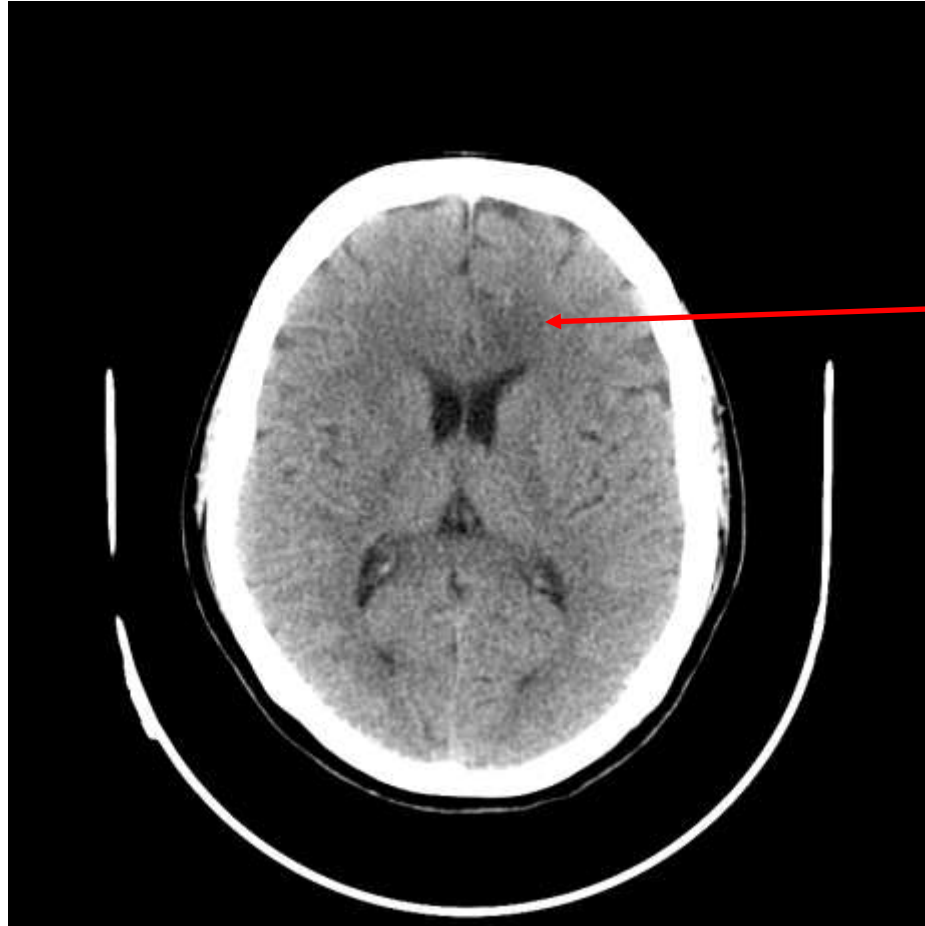Paramedian frontal and parietal lobes



Anterior Cerebral Artery

- Contralateral weakness of leg >> arm
- Contralateral hemisensory impairment in the same distribution
- Mood and cognition disturbance:
 - Depression
 - Agitated confusion
 - Emotional lability

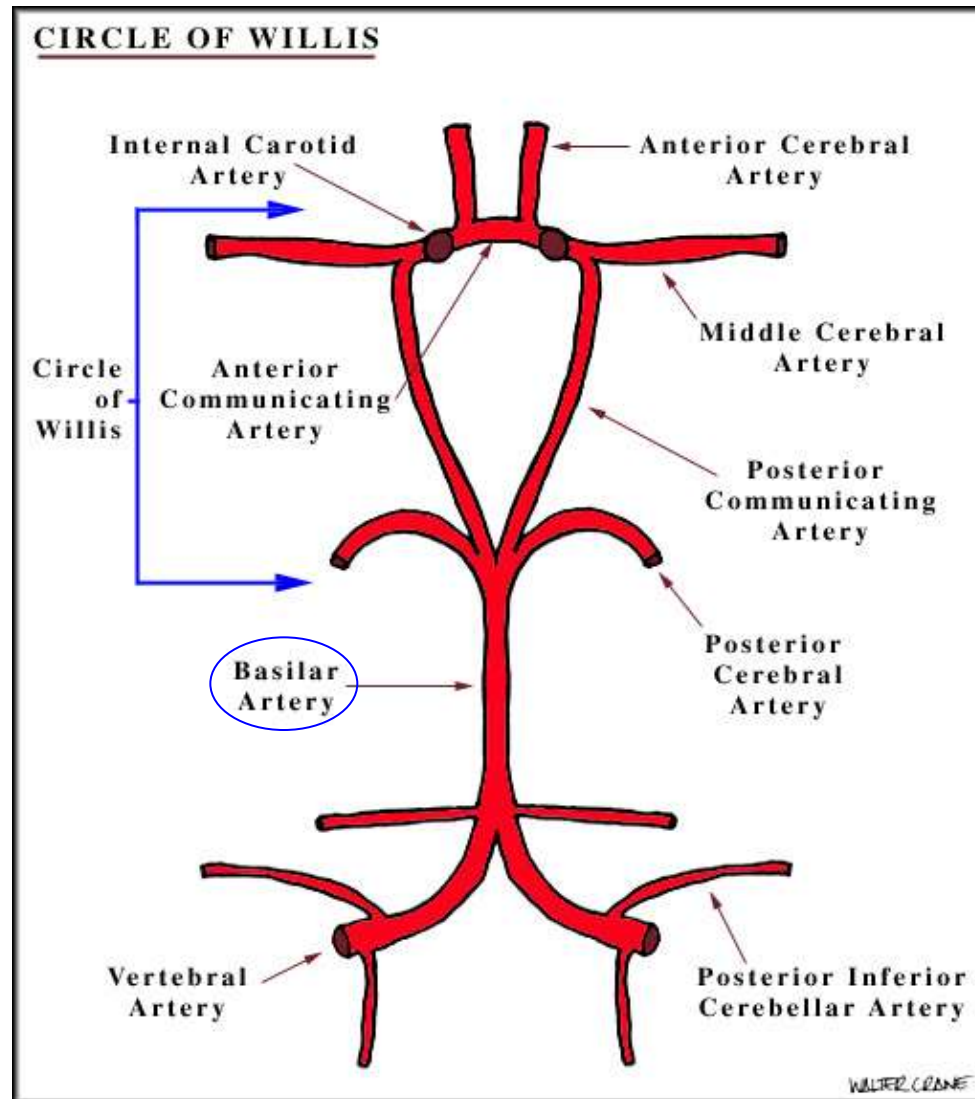
CT showing ACA Territory Infarct




Hypodense area L
paramedian frontal
lobe

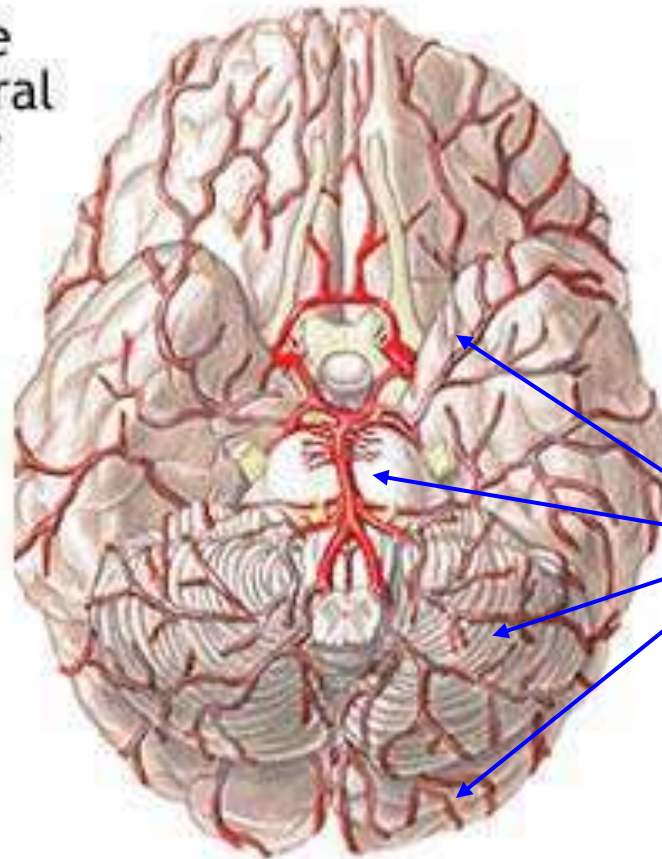
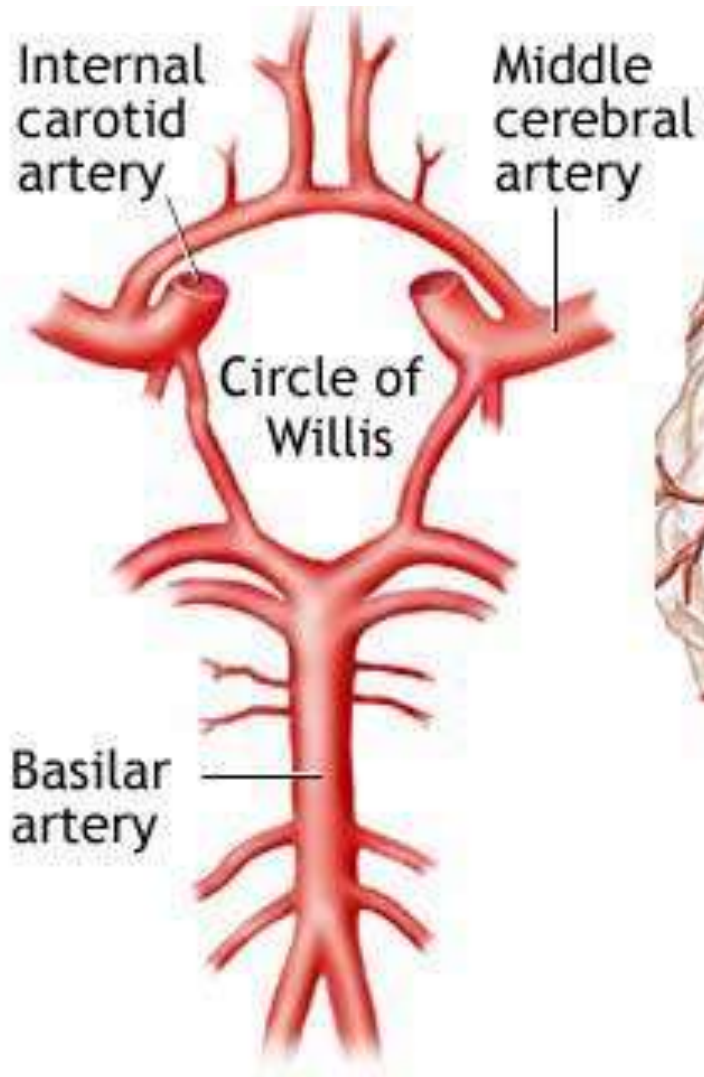
Ischemic Stroke Syndromes

Basilar Artery Occlusion





Basilar Artery Anatomy



Bottom view of brain

© ADAM, Inc.

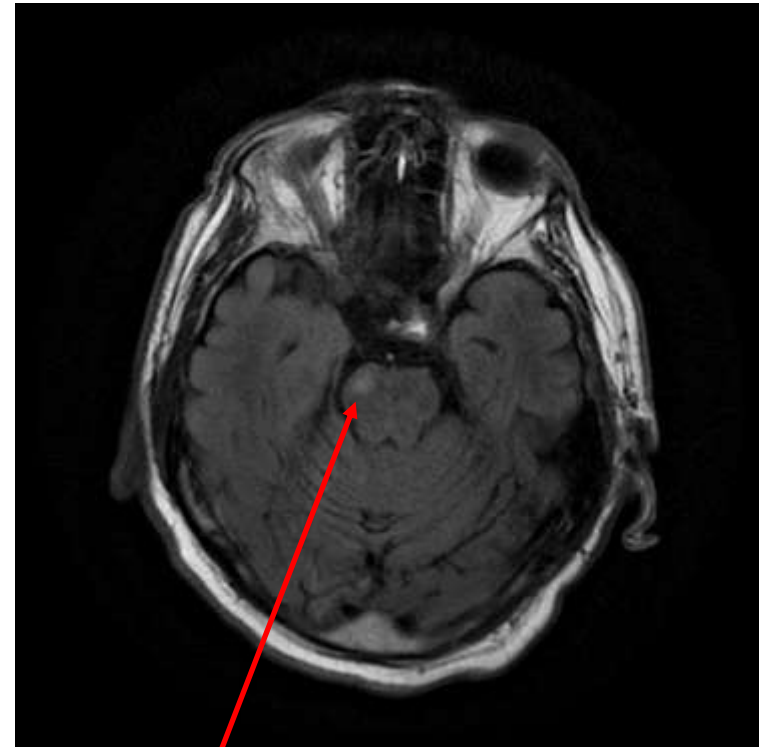
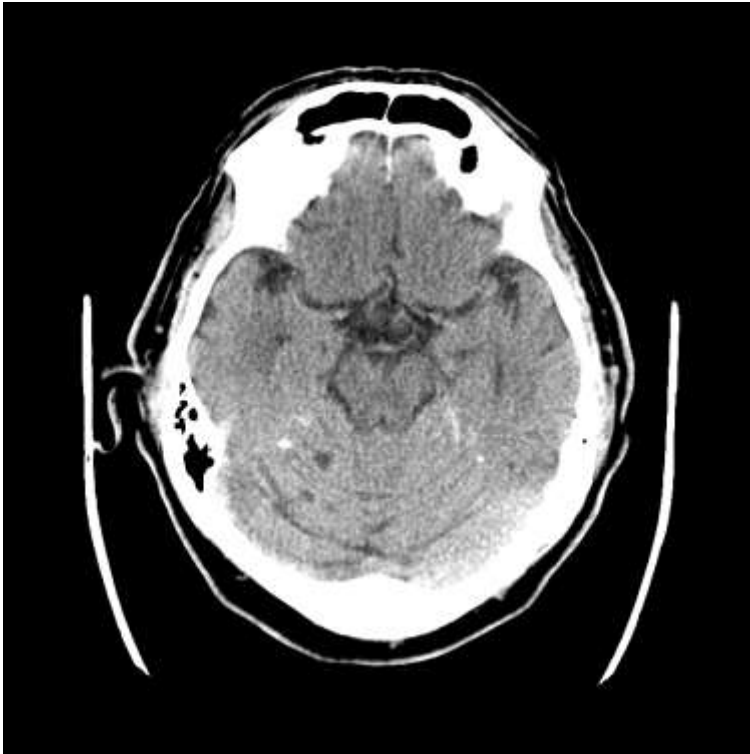

Basilar artery supplies the cerebellum, brainstem, the occipital lobes, medial temporal lobes, and thalami

Symptoms associated with Posterior Circulation Strokes



- Slurred speech
- Trouble swallowing
- Double vision
- Vertigo
- Contralateral weakness
- Crossed sensory signs
- Cranial nerve palsies
- Ipsilateral incoordination
- Unsteady gait
- Fluctuating level of consciousness
- Hearing loss

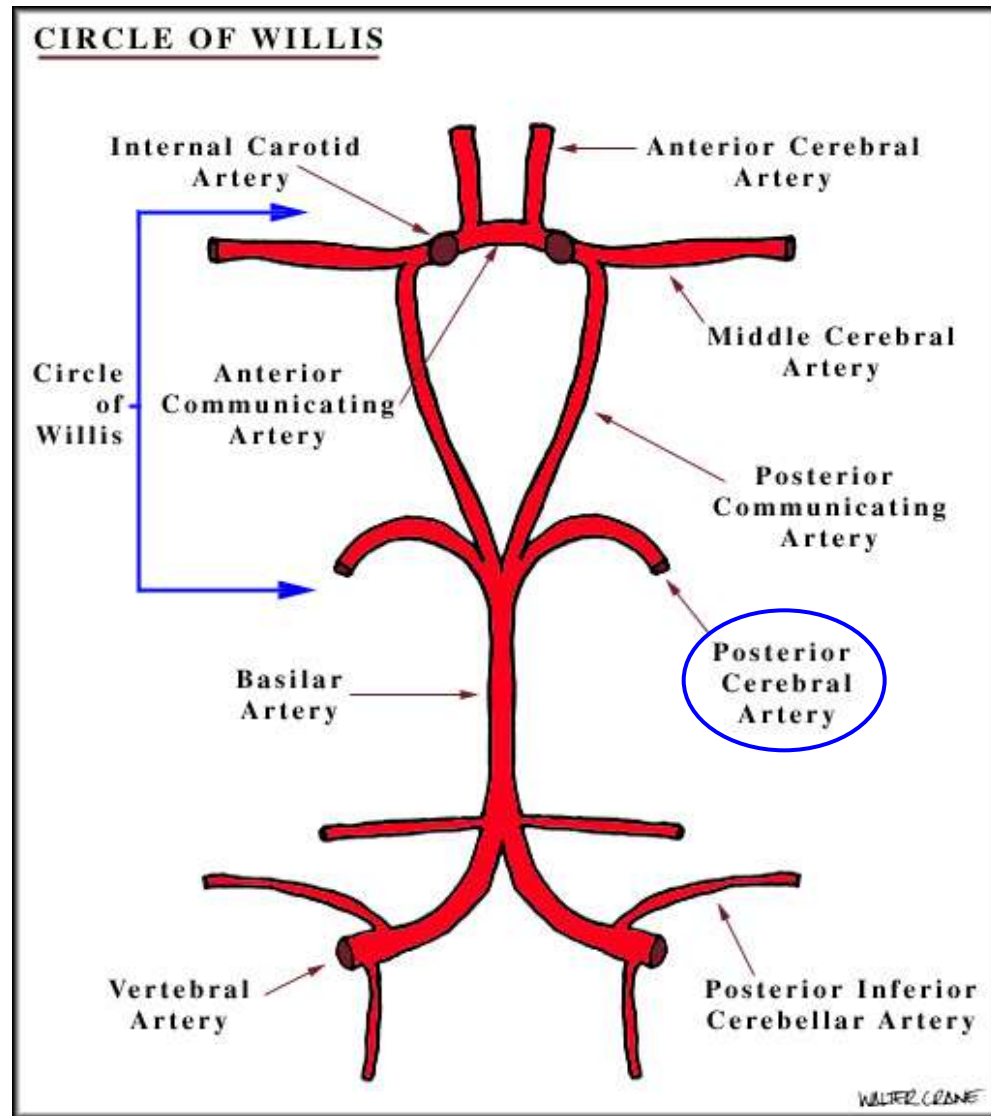
Initial Non-contrast CT Brain often looks Normal



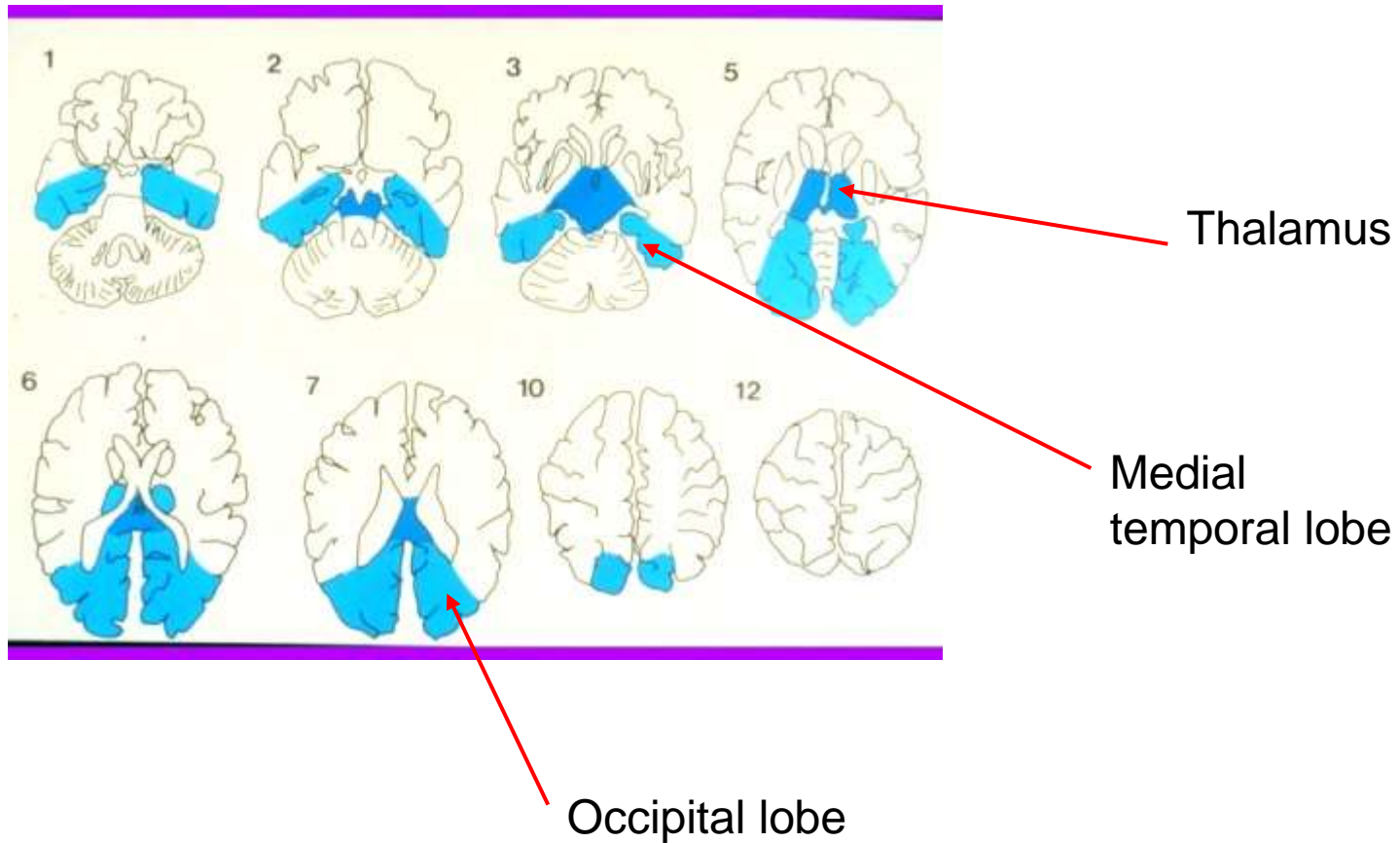
Right pontine stroke on
MRI

Ischemic Stroke Syndromes

Posterior Cerebral Artery



PCA



A decorative graphic consisting of a grid of colored dots in the bottom right corner. The dots are arranged in a roughly rectangular shape, with colors including dark purple, teal, yellow, and light purple. The dots are of varying sizes and are scattered across the bottom right area of the slide.

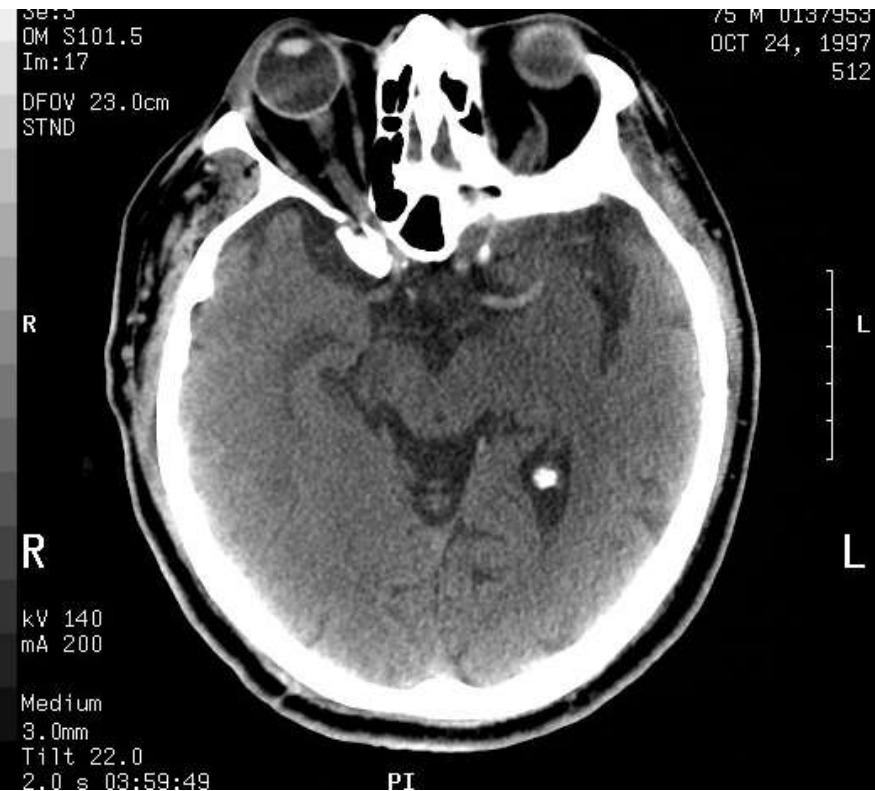
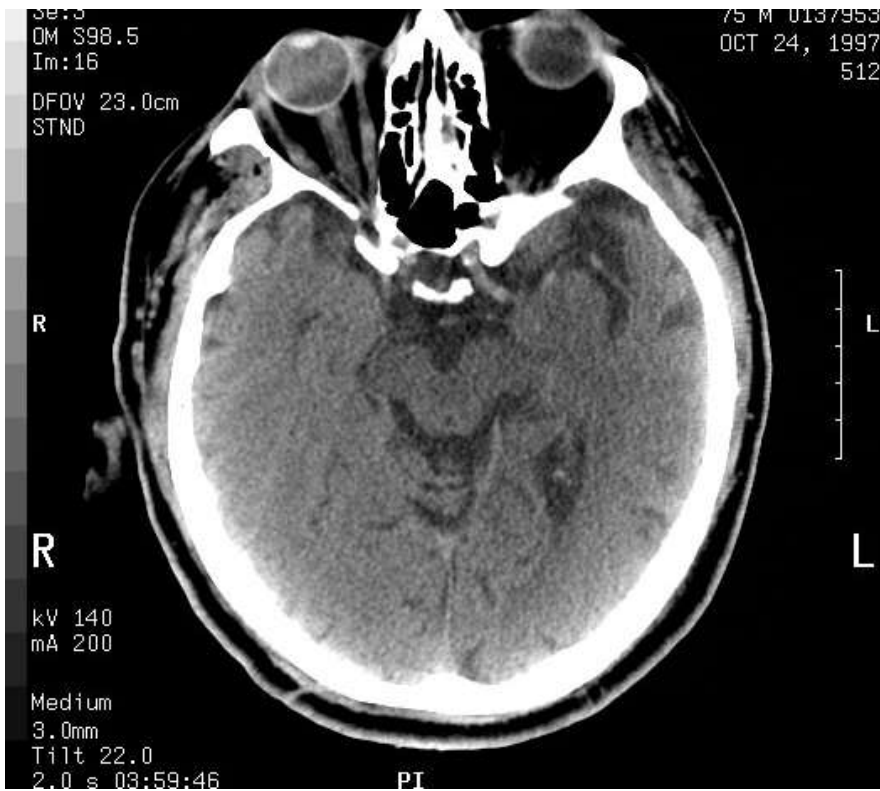
-



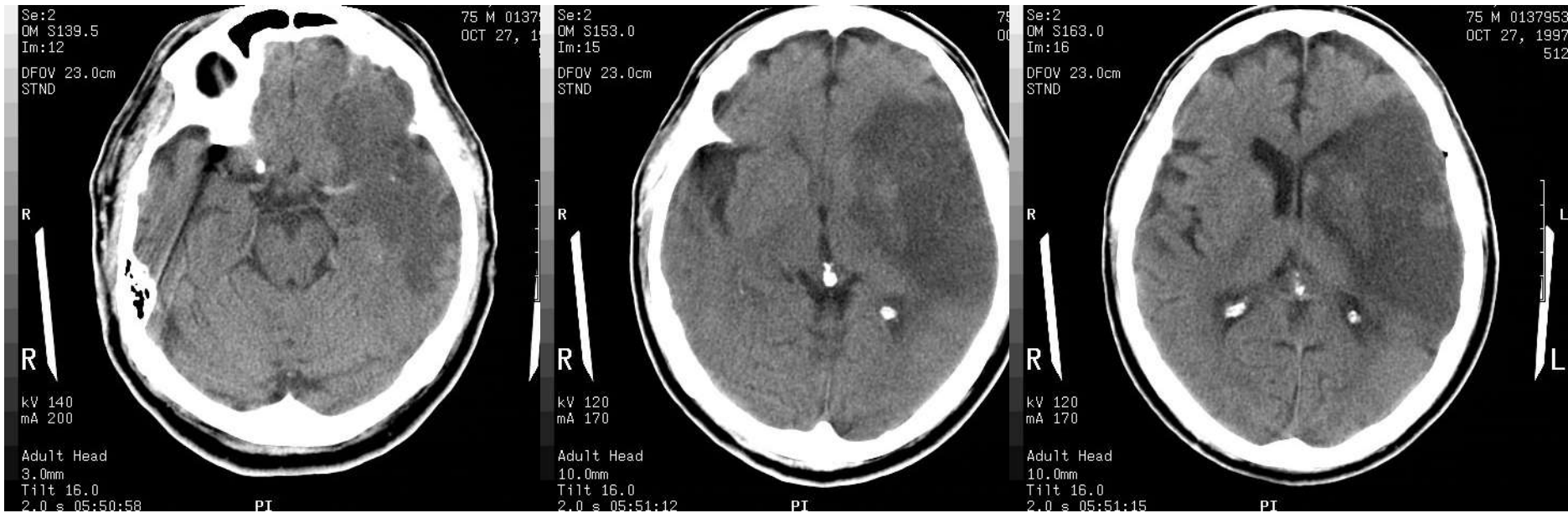
Case Example 1

- 76 yo R handed M
- Sudden onset of
 - Difficulty speaking (non-fluent, unable to read or name)
 - Right weakness (arm>leg)
 - Right sensory impairment
- 90 mins duration
- No headache
- History of CAD / HT / chol
- On aspirin
- Does this presentation conform to a particular stroke syndrome?
- Which hemisphere is affected?

Diagnosis?



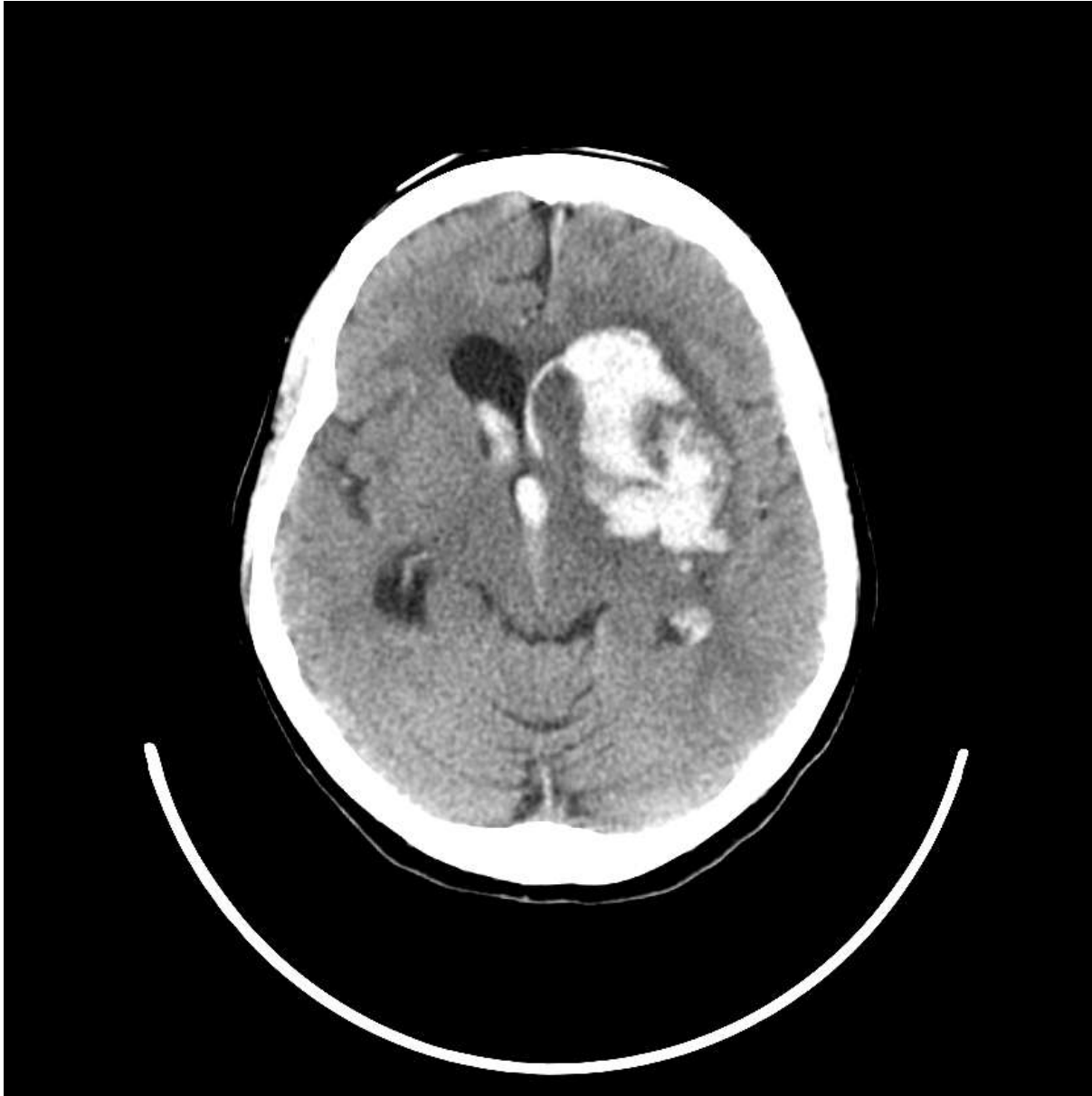Follow-up CT's





Case Example 2

- 79 yo R handed F
- Background:
Uncontrolled HT (non-compliant)
- Sudden onset of
headache, nausea and
vomiting
- Now drowsy with right
hemiplegia
- BP 230/105mmHg
- What do you think the
CT will show?
- Where will the lesion be
based on clues from
the history?

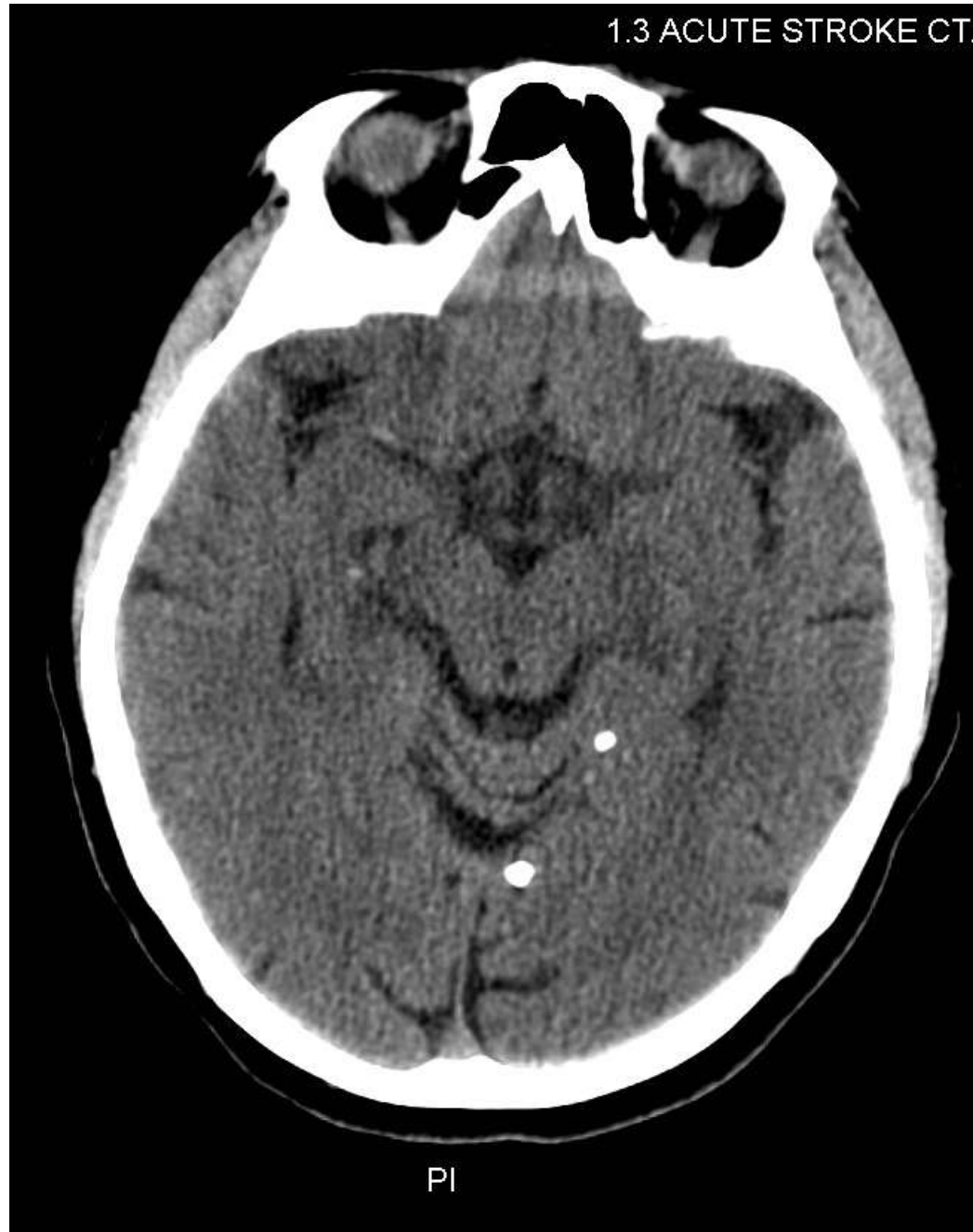




Case Example 3

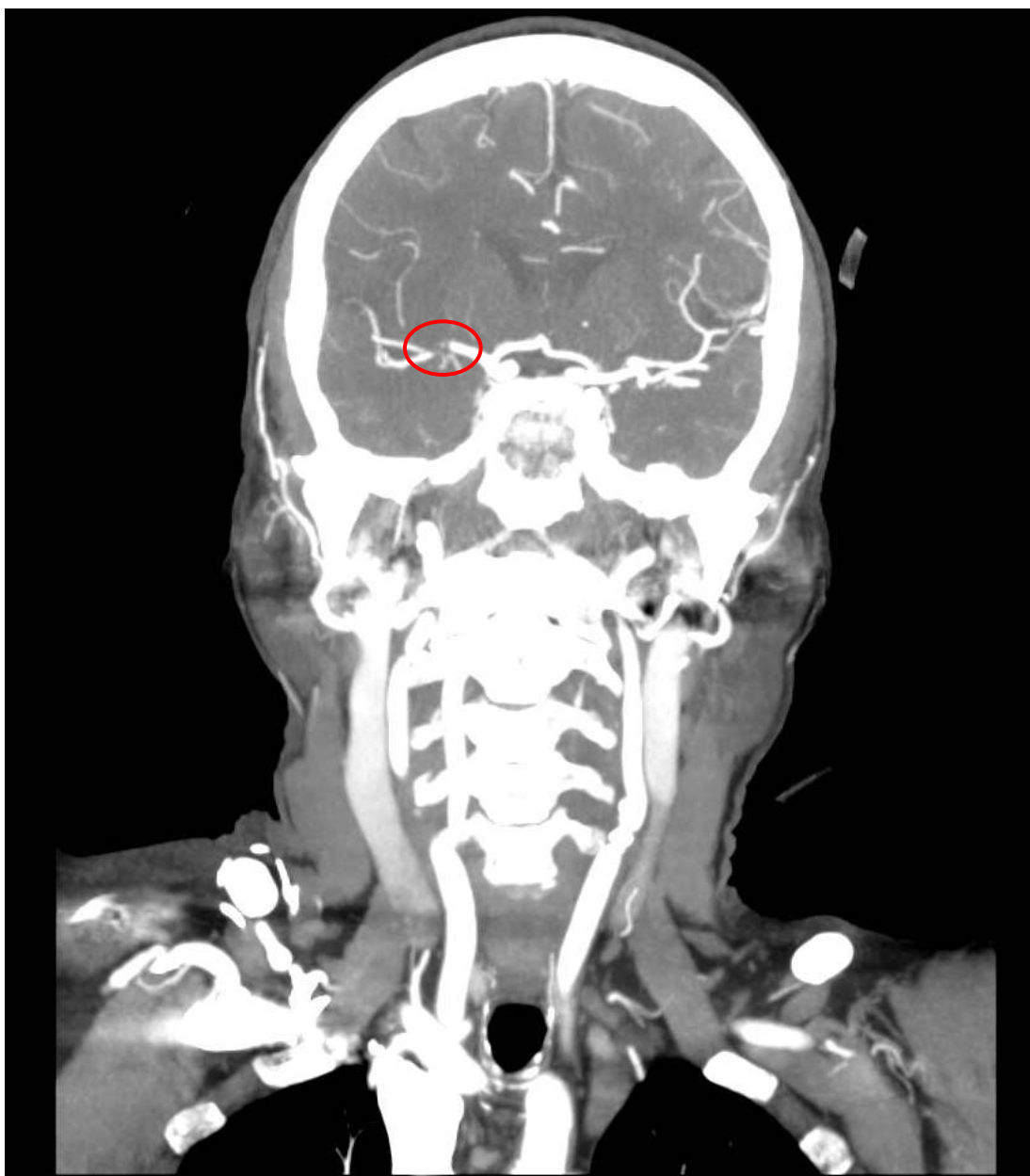
- 80 year old woman
- 1 hour history
 - Acute hemiplegia
 - Gaze deviation
 - Hemispatial neglect
- A fib

1.3 ACUTE STROKE CTA



PI





111.0
DFOV 25.0 cm
Mean Transit Time
DoB: July 11 1925

A 125

Dec 13 2005

Ex: 4290
Se: 5
Im: 152+C

15,000

R

1
2
5

0

L

1
2
5

W 255 : L 127

P 124

W 15,000 L 7,5000

6

16.0
DFOV 25.0 cm
Blood Flow
DoB: July 11 1925

A 125

Dec 13 2005

Ex: 4290
Se: 5
Im: 151+C

R 71.8mm
A 52.7mm
I 6.0mm
no value

1157

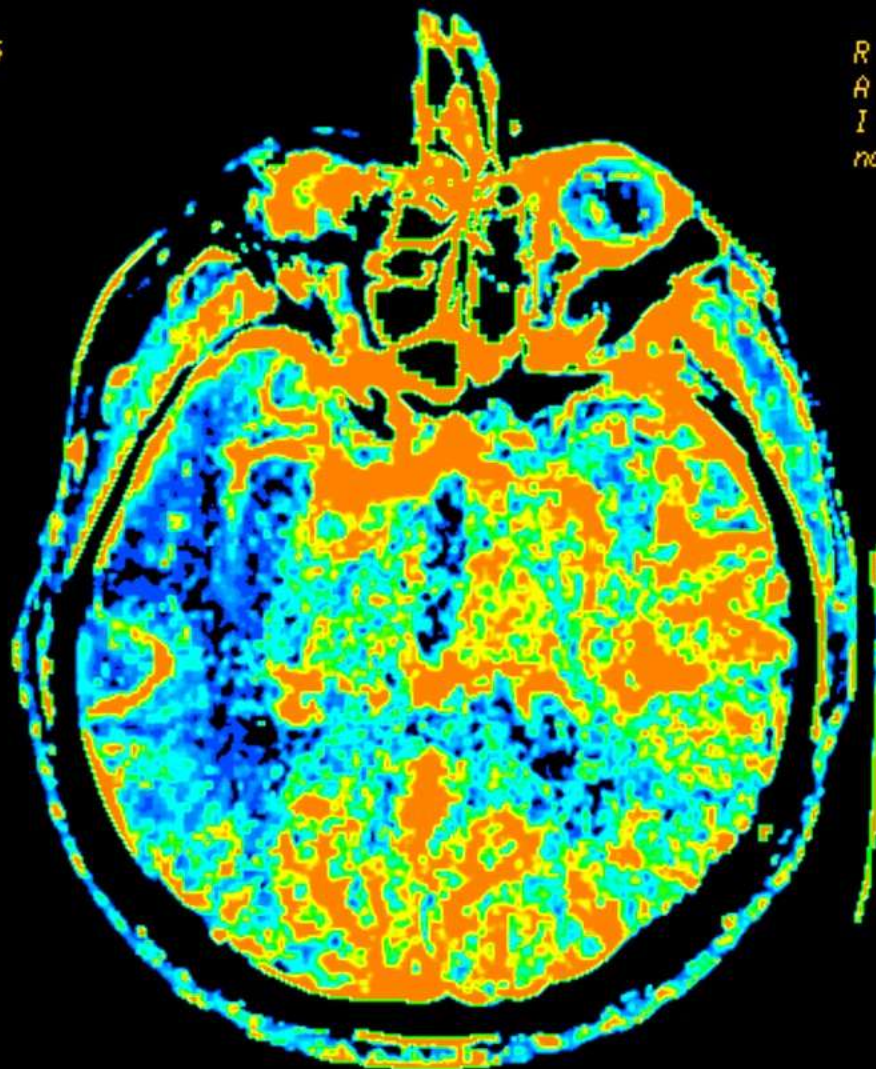
R

1

2

5

31.500



W 207 : L 104

P 124

W 1125.5 L 594.25

3

111.0
DFOV 25.0 cm
Blood Volume
DoB: July 11 1925

A 125

Dec 13 2005

Ex: 4290
Se: 5
Im: 152+C

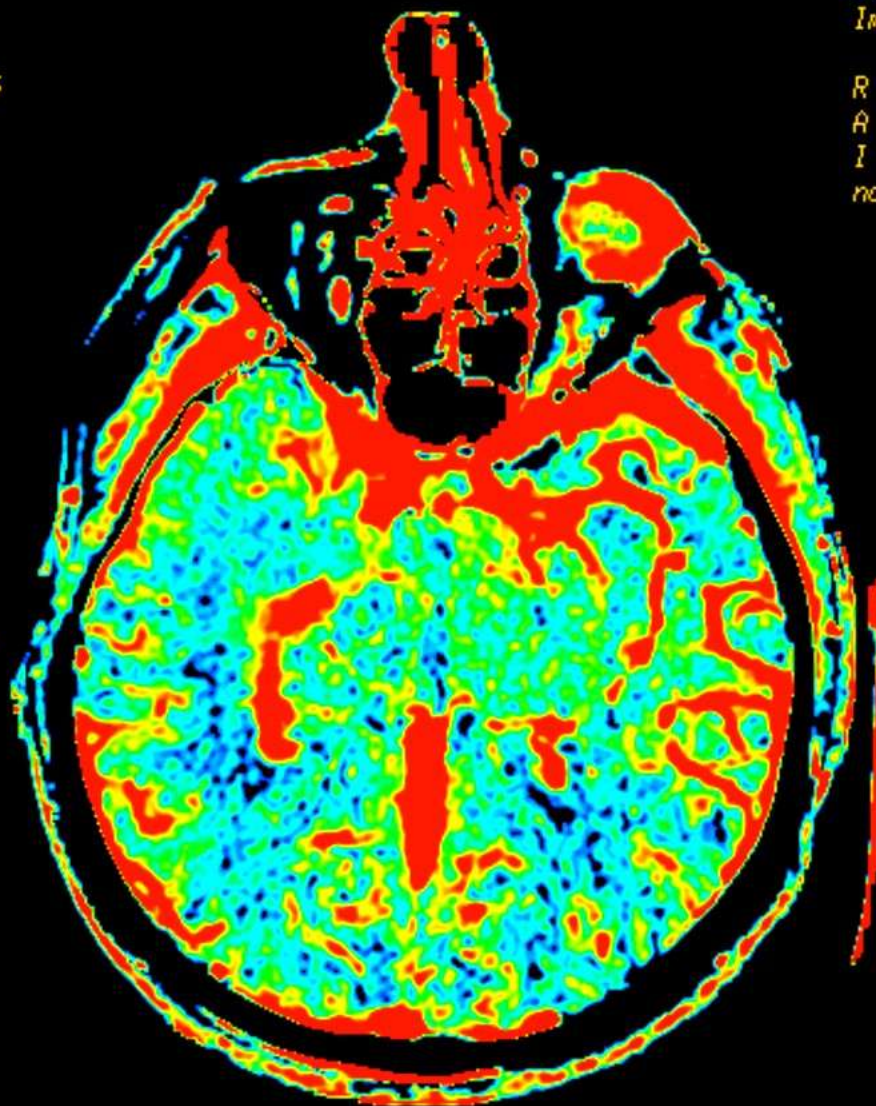
R 96.7mm
A 80.6mm
I 11.0mm
no value

99.300

R

1
2
5

3.9000



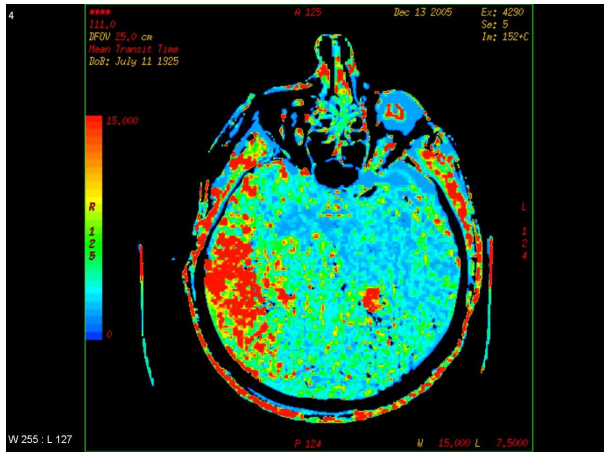
L

1
2
4

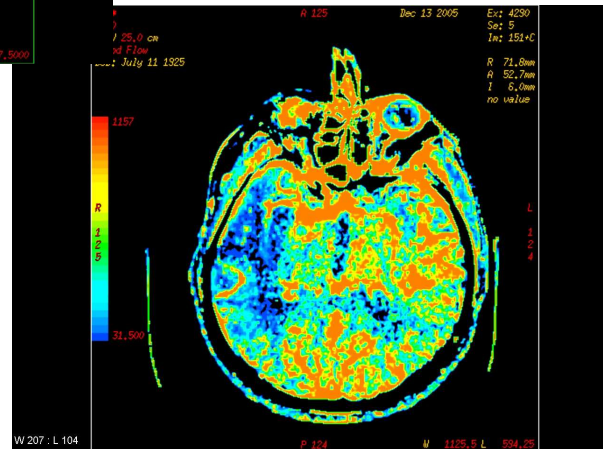
W 207 : L 104

P 124

W 95,500 L 51,600

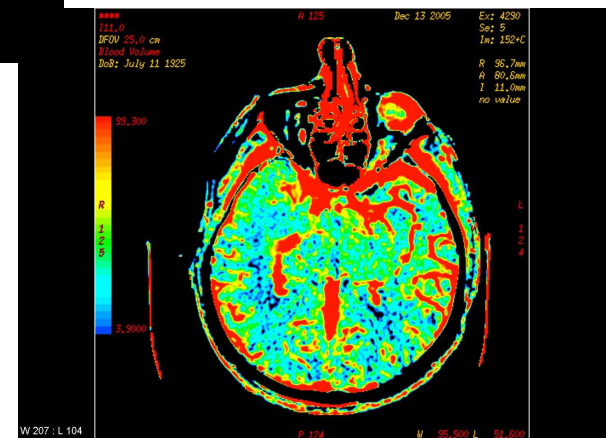


Mean transit
time prolonged
(red)



Cerebral blood flow
reduced (blue)

Mismatched defect in the
right MCA territory

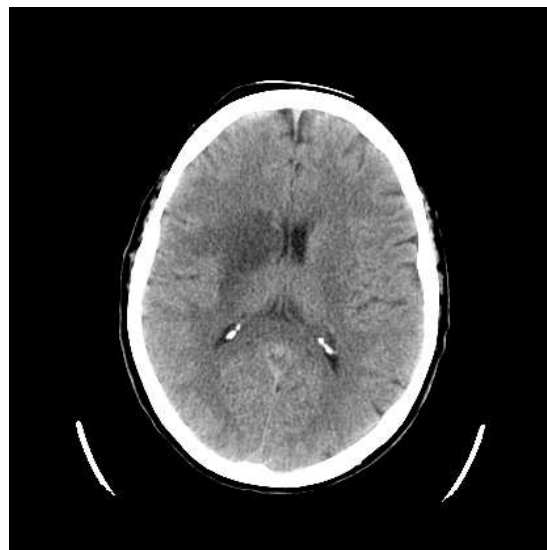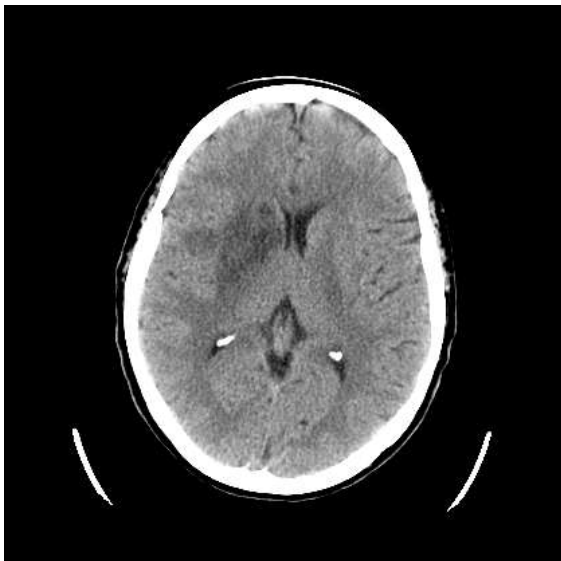
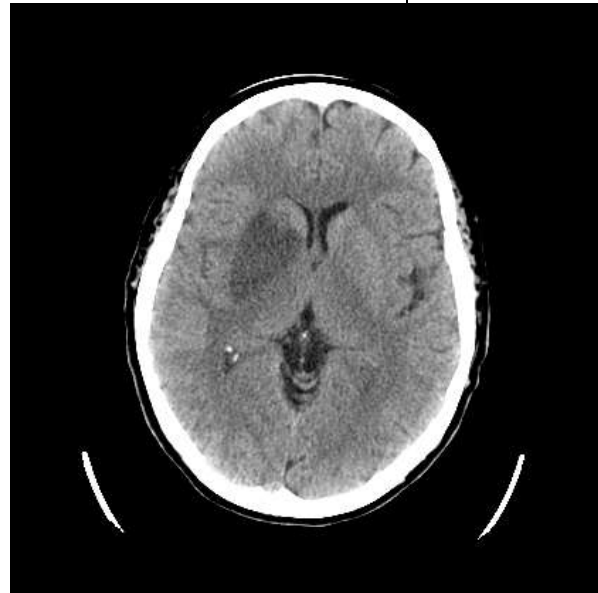
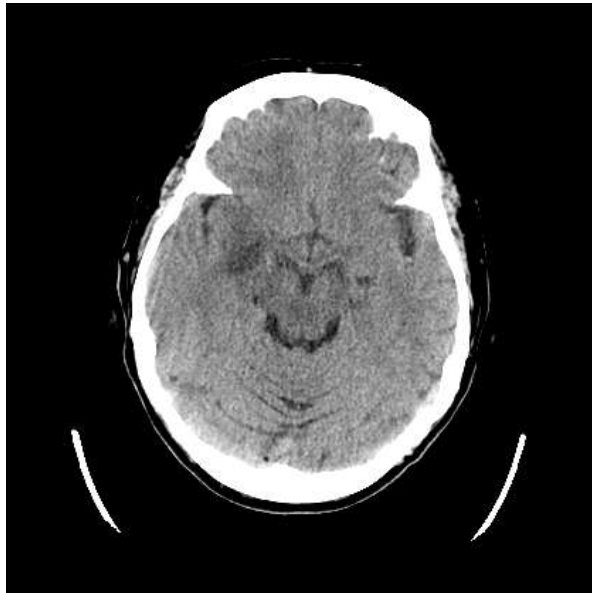
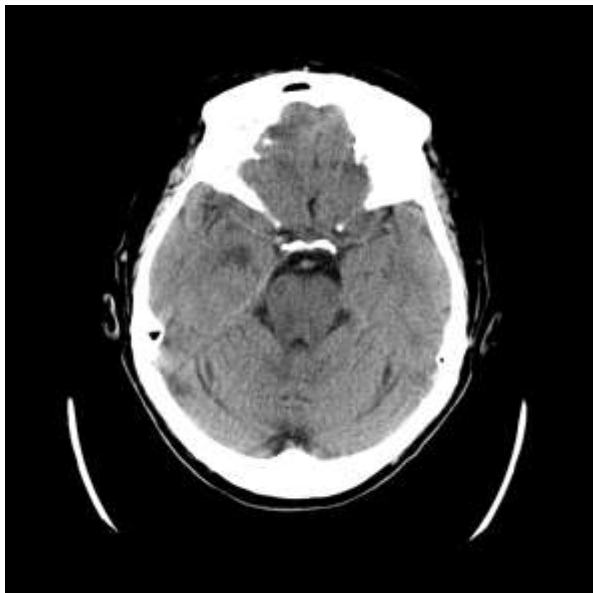


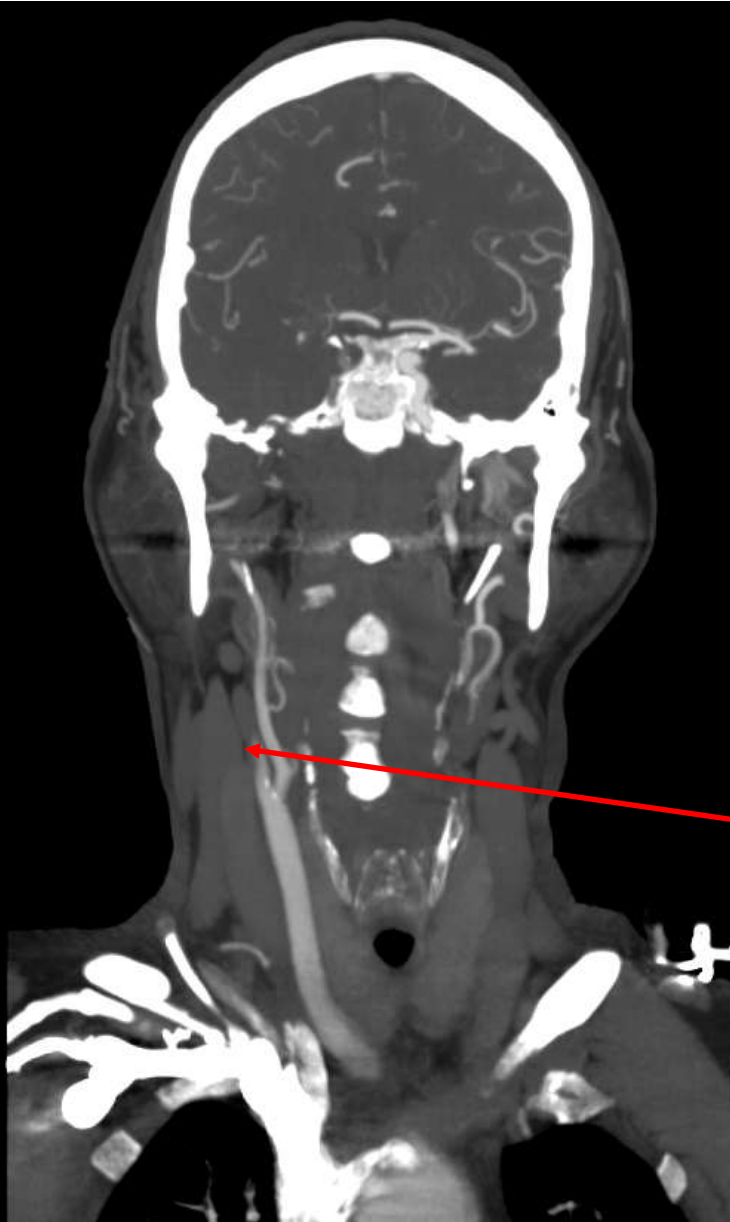

Cerebral blood volume
normal



Case Example 4

- 67 yo R handed female
- Sudden onset 3 hours ago
 - L hemiparesis
 - L hemisensory impairment
 - Dysarthria
- Alert + BP 190/85
- Background of HT / chol



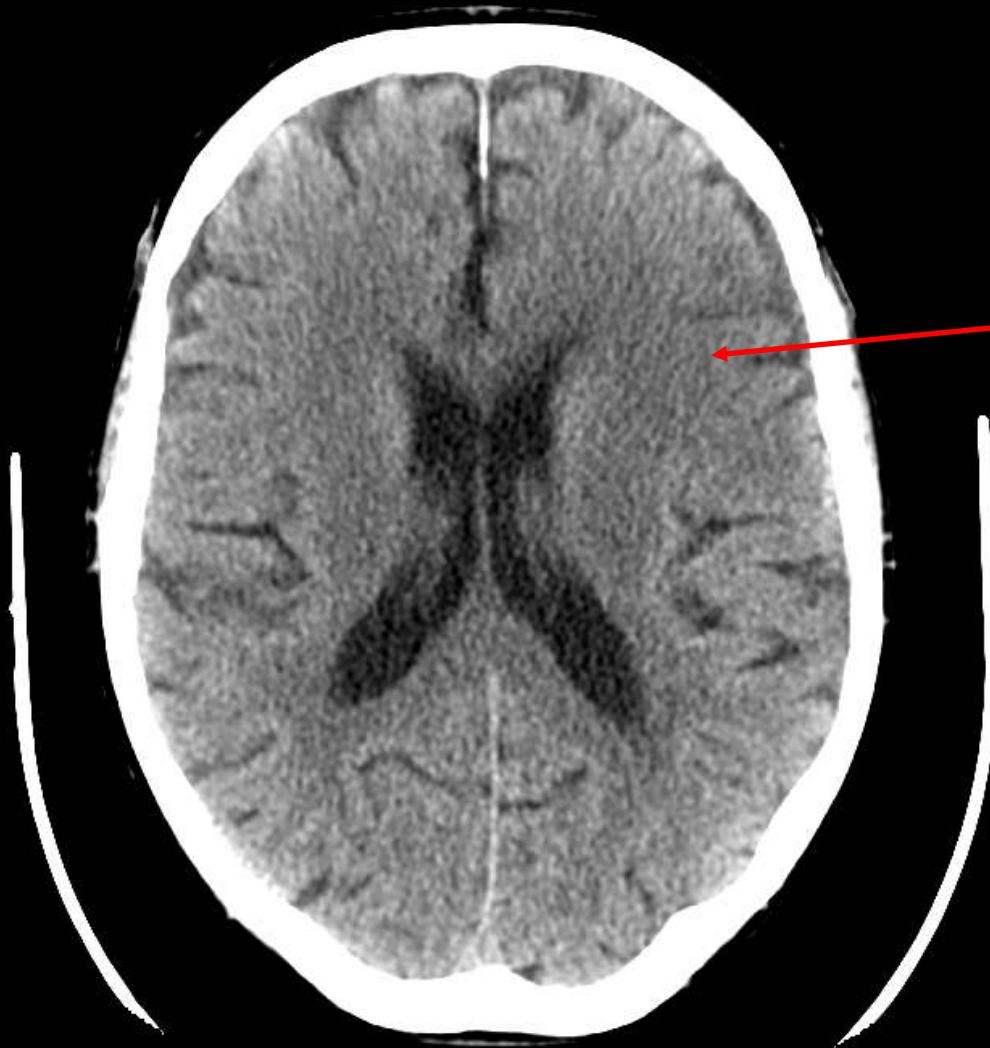


Right internal
carotid artery
occlusion



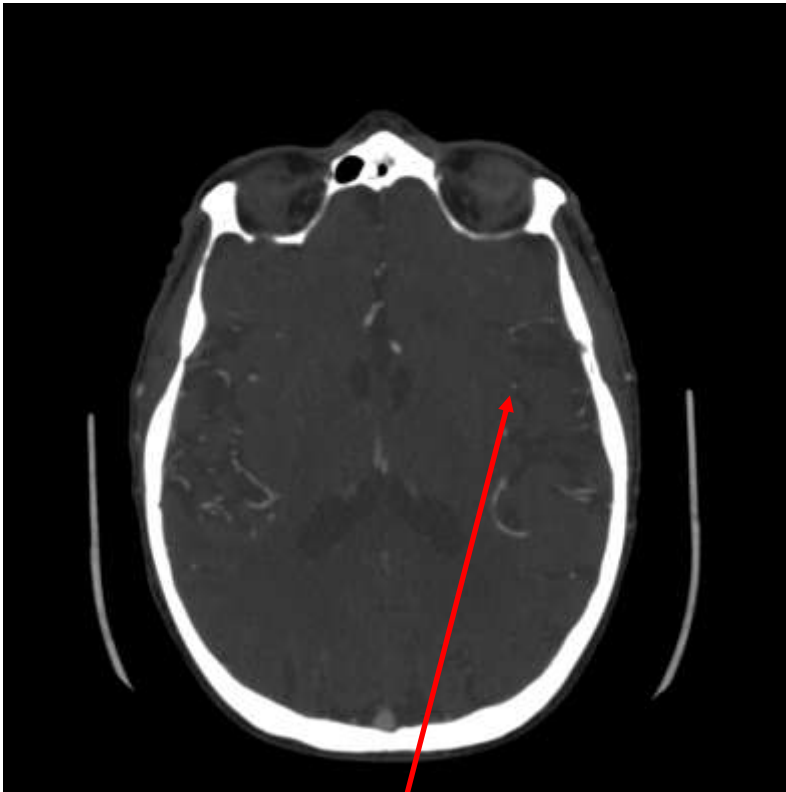
Case Example 5

- 82 yo RH man
- Background of HT and diabetes
- 2 hour history of
 - Non-fluent speech
 - Word-finding difficulty
 - R hemiparesis
- Which blood vessel is involved?
- Which hemisphere?
- Management?

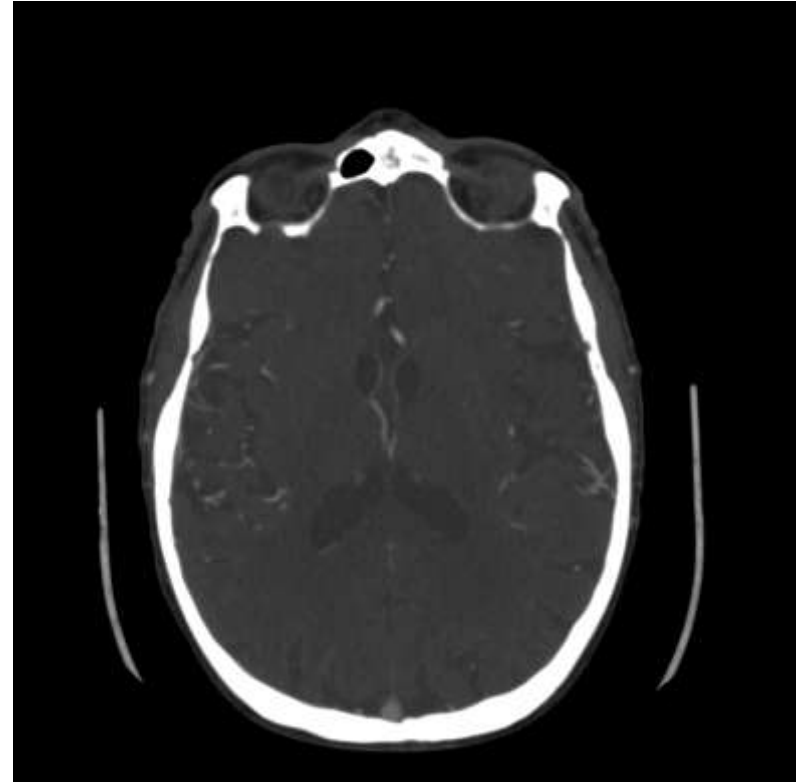


Subtle loss of
grey-white
differentiation
in L frontal
region

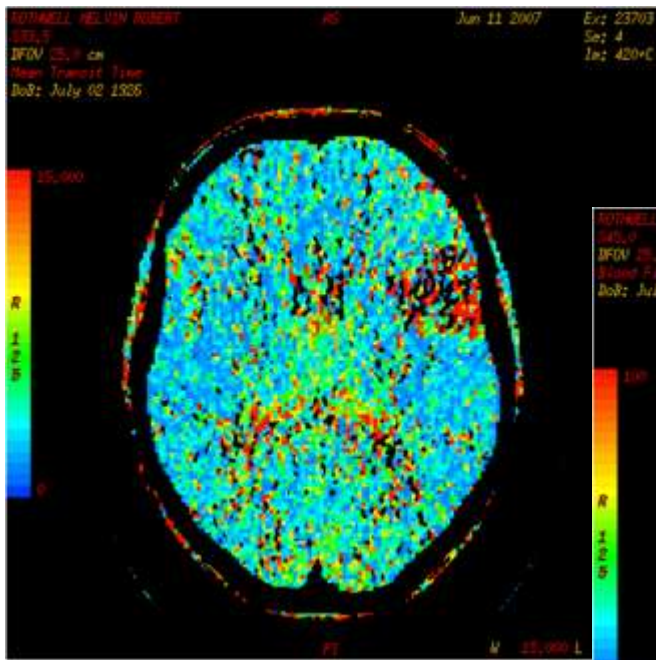
CT Angiogram



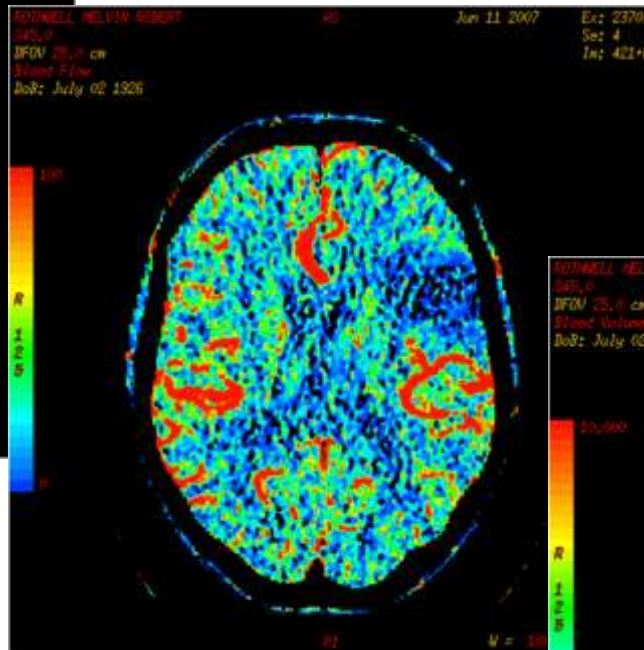
Occluded 2nd branch
of L MCA



Reduced collateral branches
In L MCA territory

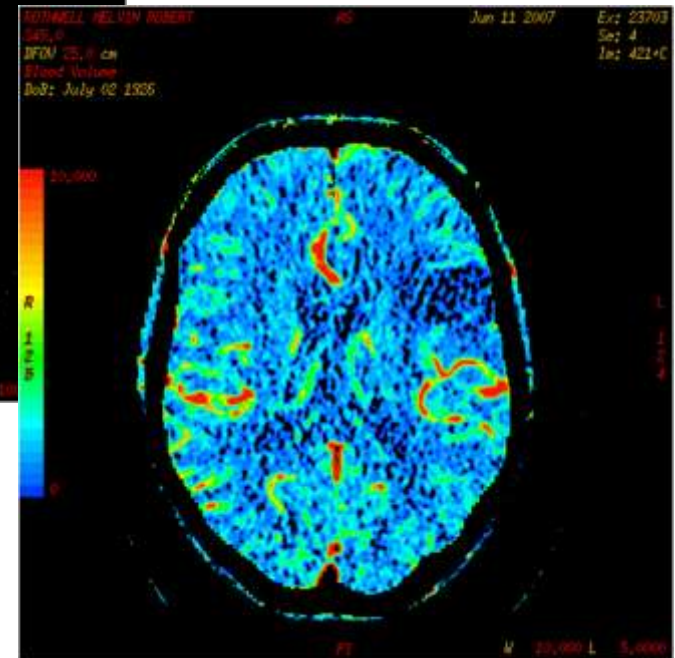


Prolonged mean transit time (red)



Reduced cerebral blood flow (blue)

Matched defect in the left MCA territory



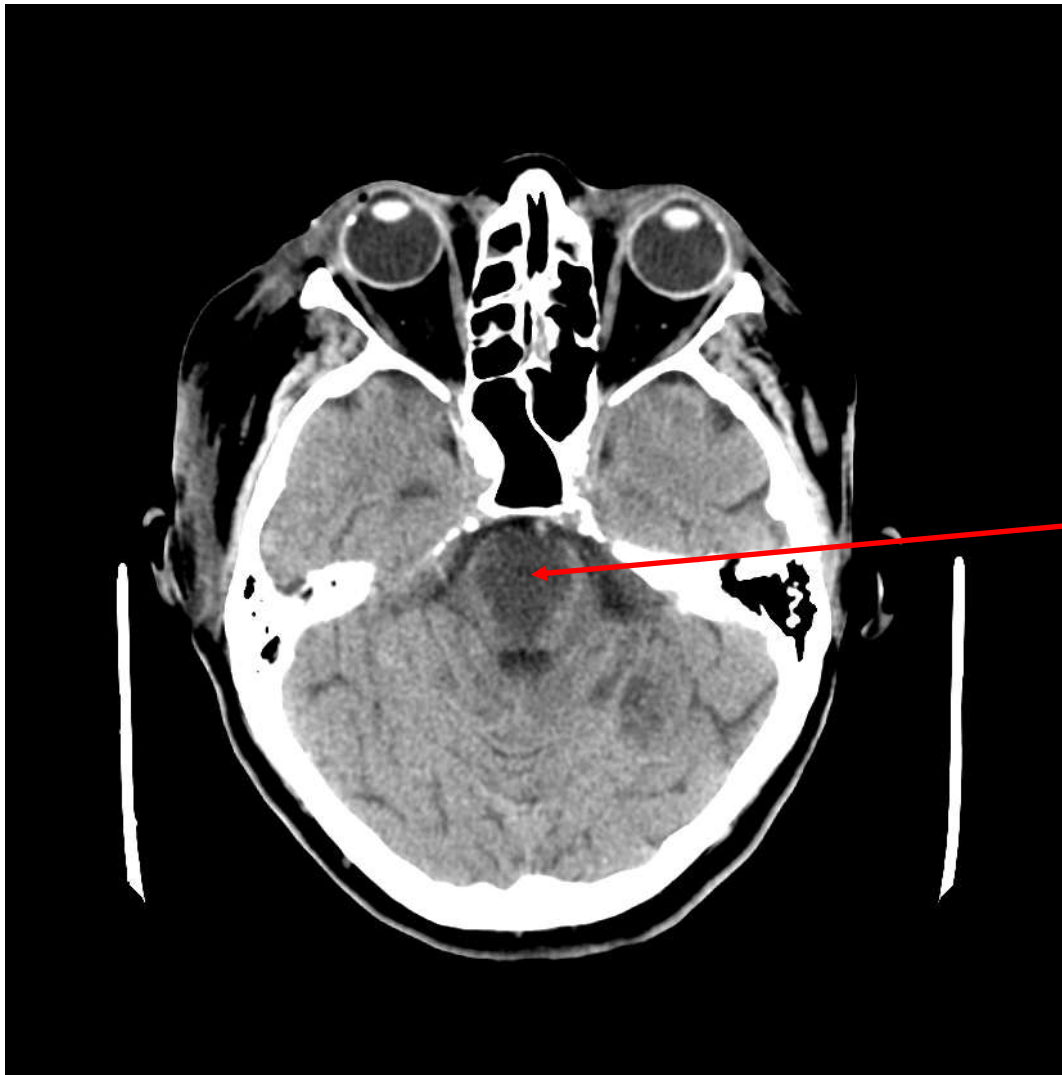

Reduced cerebral blood volume (blue)



Case Example 6

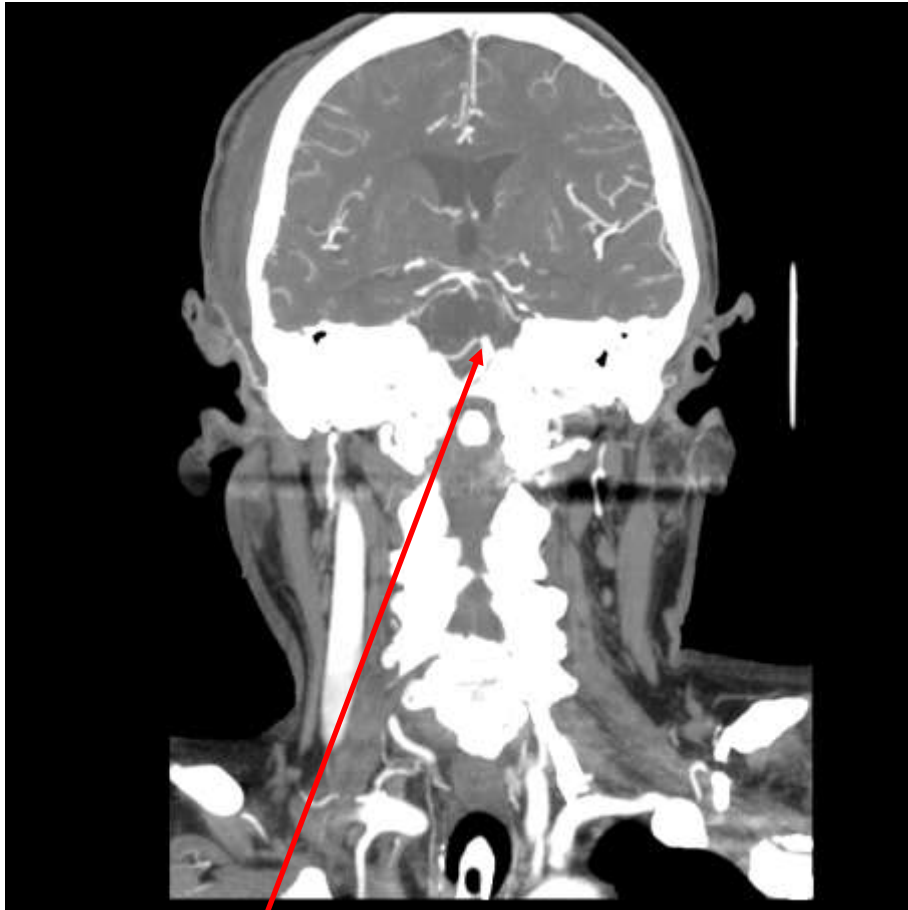

- 76 yo F
- Found collapsed
- Unresponsive
- Spastic quadriplegia
- No verbal output
- No gag reflex
- No facial movement
- Able to respond by blinking or with vertical eye movements

Non-Contrast CT Brain Scan

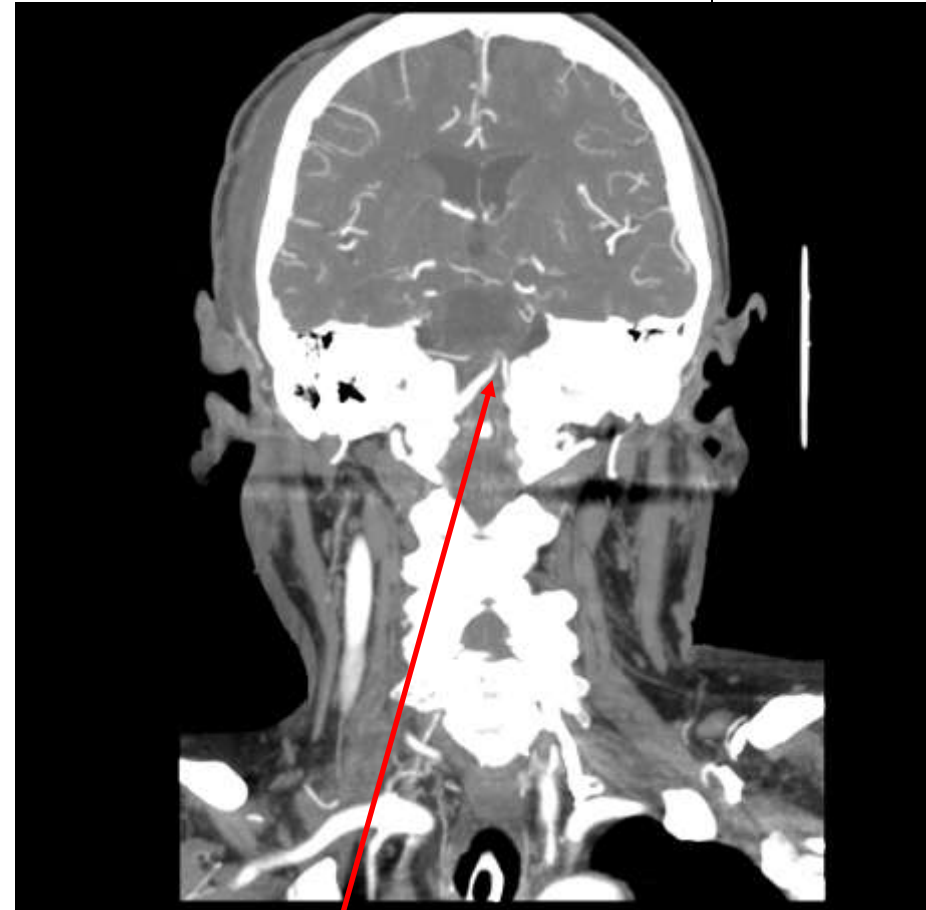


Pontine infarct

CT Angiogram



Occluded basilar artery



2 vertebral arteries join to become the basilar artery